

Celiac Disease Presenting as Idiopathic Terminal Ileum Obstruction

Chee-Kin Hui

Chee-Kin Hui, Centre For Alimentary Studies, Hong Kong
Chee-Kin Hui, Quality Healthcare Medical Services, Hong Kong
Correspondence to: Chee-Kin Hui, Rm. 601, HK Pacific Centre,
28 Hankow Road, Tsim Sha Tsui, Hong Kong. bckhui@gmail.com
Telephone: +852-2723-1183 Fax: +852-2723-6620
Received: March 7, 2013 Revised: April 11, 2013
Accepted: April 15, 2013
Published online: June 21, 2013

ABSTRACT

Celiac disease is an inflammatory injury in the small bowel mucosal that occurs after ingestion of gluten. Here, is a case of idiopathic intestinal obstruction at the terminal ileum in a patient with celiac disease. A 34-year old Caucasian lady presented with terminal ileum obstruction and abdominal fluid collection. She was diagnosed with celiac disease based on the histological findings of focal villous atrophy, intraepithelial lymphocytic infiltrate and crypt hyperplasia with mitoses at the terminal ileal and jejunal biopsies, elevated anti-tissue transglutaminase antibody (Ab) Immunoglobulin (Ig) G, raised anti-tissue transglutaminase Ab IgA; and; positive HLA DQ2 gene. Her intestinal obstruction and abdominal fluid collection resolved with gluten free diet. In conclusion, intestinal obstruction at the terminal ileum and fluid collection in the abdomen can be a complication of celiac disease. A gluten free diet can lead to resolution of the intestinal obstruction and abdominal fluid collection in celiac disease.

© 2013 ACT. All rights reserved.

Key words: Celiac disease; Intestinal obstruction; Ileum; Abdominal fluid; Gluten free diet

Hui CK. Celiac Disease Presenting as Idiopathic Terminal Ileum Obstruction. *Journal of Gastroenterology and Hepatology Research* 2013; 2(6): 652-654 Available from: URL: <http://www.ghrnet.org/index.php/joghr/article/view/408>

INTRODUCTION

Celiac disease is a small bowel disorder. It is characterized by small bowel mucosal inflammation, villous atrophy and crypt hyperplasia

with resultant malabsorption. The inflammatory injury to the small bowel mucosa occurs after the ingestion of gluten^[1]. Patients with celiac disease can present with a variety of symptoms. Patients with celiac disease who do not present with the classical malabsorption symptoms are usually diagnosed late. Here, is a case of idiopathic intestinal obstruction at the terminal ileum and abdominal collection in a patient with celiac disease.

CASE REPORT

A 34-year old Caucasian lady presented with acute abdominal pain, vomiting, and fever. At presentation, she was found to have fever of 40.3°C, and, tenderness in the right lower quadrant. However, there was no evidence of rebound or rigidity. Abdominal X-ray showed dilatation of the small intestine and intestinal obstruction in the small intestine.

An urgent computerized tomography (CT) of the whole abdomen showed dilated loop at the terminal ileum in the right lower abdomen with thickening and edema of the ileal wall (Figure 1). The proximal small bowel was also distended. Fluid was present in the right paracolic gutter, sub-hepatic region and in the pelvis. There was no evidence of lymphadenopathy. The CT was suggestive of distal small bowel obstruction at the ileum with surrounding wall edema.

Gynecological examination was unremarkable with no evidence of adnexal tenderness or pelvic inflammatory disease. High vaginal swab were negative for bacteria, virus, or chlamydia. Stool was negative for bacteria and Mycobacteria tuberculosis. There was no evidence of parasite infestation on three repeated stool samples. Serologic tests for *Trichinella spiralis*, *Wuchereria bancrofti*, *Toxocara canis*, *Schistosoma* and *Echinococcus* were all negative.

A colonoscopy was performed on day-3 of admission. The endoscope was passed to around 15 cm from the ileal-cecal valve. No intramucosal lesion could be seen in the colon or terminal ileum. Multiple biopsies were taken from the terminal ileum and colon.

The biopsy specimens were fixed in 10% neutral buffered formalin, processed using automated tissue processor and all embedded as paraffin blocks. Sections of 3 micron thick were cut, stained with haematoxylin & eosin and examined under light microscopy.

The terminal ileum showed focal villous atrophy (Figure 2A), intraepithelial lymphocytic infiltrate (Figure 2B) and crypt hyperplasia with mitoses (Figure 2C) were demonstrated. These findings were suggestive of celiac disease. Multiple biopsies taken

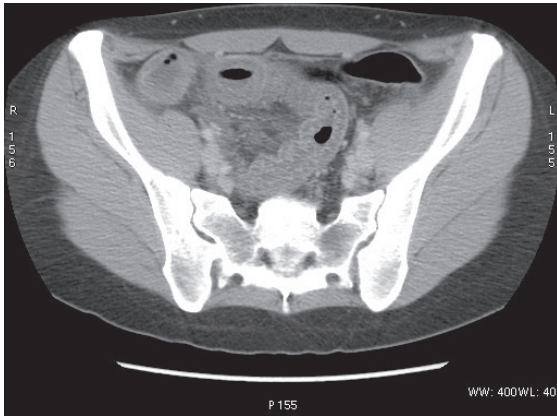


Figure 1 Computerized tomography showing dilated loop at the terminal ileum with thickening of the wall and edema.

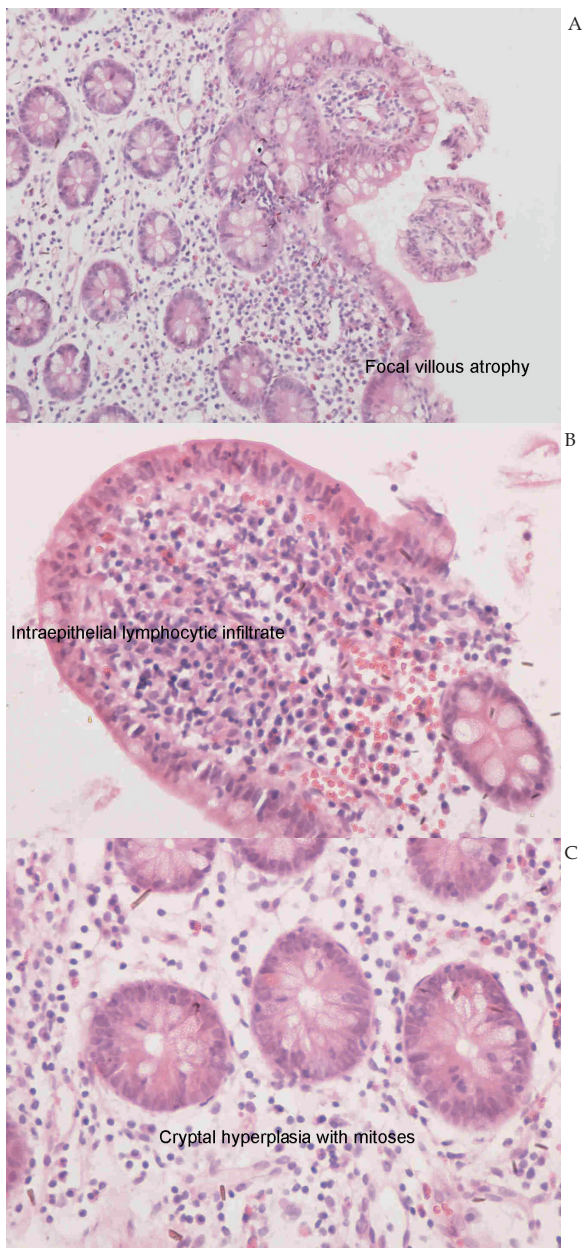


Figure 2 High powered field of terminal ileal biopsy showing (A) focal villous atrophy ($\times 200$); (B) intraepithelial lymphocytic infiltrate ($\times 400$); and (C) crypt hyperplasia with mitoses ($\times 400$) by haematoxylin and eosin staining.

from the colon showed mild non-specific inflammation.

The patient had a raised anti-tissue transglutaminase antibody (Ab) immunoglobulin (Ig) G 92 U/mL (normal range <6). But her anti-tissue transglutaminase Ab IgA, anti-gliadin Ab (IgA and IgG) and endomysial Ab (IgA) were all negative, respectively. She had a decreased serum IgA 44 mg/dL (normal range 87-474) and serum IgM 36 mg/dL (normal range 48-312). Her serum IgG was normal at 777 mg/dL (normal range 681-1648).

Upper endoscopy was normal and duodenal biopsies showed non-specific lymphangiectasia. There was no evidence of celiac disease on duodenal biopsies. Small bowel capsule endoscopy performed one month after resolution of intestinal obstruction was negative for stricture, ulcers or tumors in the small intestine. The capsule was able to pass through the ileum without difficulty. Jejunal biopsies taken by small bowel enteroscopy showed evidence of celiac disease with focal villous atrophy, intraepithelial lymphocytic infiltrate and crypt hyperplasia with mitoses.

HLA DQ2 and HLA DQ8 were tested by the Protrans Domino System HLA Celiac Disease [CD] Association kit (Protrans, Ketsch, Germany). HLA DQ2 was found to be present. The genotypes detected were: DRB1*03:01, DQA1*05:01, DQB1*02:01, DRB1*07, DQA1*02:01, DQB1*02:02. HLA DQ8 was not present.

The intestinal obstruction resolved on Day-6 of admission with conservative measures. A CT scan taken at this juncture showed complete resolution of the terminal ileal obstruction. However, the previously seen gross wall thickening and edema at the terminal ileum was still present. The fluid in the right para-colic gutter, sub-hepatic region and in the pelvis was still present.

She was then commenced on a gluten free diet. A repeat CT performed 4 weeks after gluten free diet revealed complete resolution of the gross wall thickening and edema at the terminal ileum. The fluid in the right para-colic gutter, sub-hepatic region and in the pelvis had also completely resolved.

Her serum IgA and IgM returned to normal 8 weeks after gluten free diet. At this point, her anti-tissue transglutaminase Ab IgG had decreased to 56 U/mL (normal range <6). However, her anti-tissue transglutaminase Ab IgA was raised at 28 U/ml (normal range <2).

Colonoscopy at 12 months after initiation of gluten free diet showed complete resolution of histological changes previously detected in the terminal ileum. Her anti-tissue transglutaminase Ab IgG had decreased to 16 U/mL (normal range <6), and her anti-tissue transglutaminase Ab IgA had decreased to 10 U/mL (normal range <2).

In view of her celiac disease and the site of the obstruction, we even performed a whole body positron emission tomography-computerized tomography to look for evidence of lymphoma complicating celiac disease. But this was negative. She was followed-up for a period of 24 months. CT whole abdomen performed at 12 months and 24 months of follow-up showed no recurrence of the intestinal obstruction or abdominal fluid collection. There was also no evidence of lymphoma complicating her celiac disease on CT scan.

DISCUSSION

Intestinal obstruction is an uncommon presentation of celiac disease^[2,3]. The site of the small bowel obstruction, when it uncommonly occurs, is usually at the proximal or mid-jejunum^[2,3,4]. The cause of intestinal obstruction in celiac disease is usually due to the formation of strictures, ulcerations, or, tumors in the small bowel^[4]. However, in a long term follow-up study, those with intestinal obstruction due to ulcerations or strictures, were eventually diagnosed with small bowel lymphoma^[4].

Unlike previous reports, the site of this patient's intestinal obstruction was located at the terminal ileum. This is an atypical site for intestinal obstruction in celiac disease^[2,3,4]. Besides the atypical site of obstruction, this patient also had fluid collection in the abdomen. The common pathological conditions in the terminal ileum would be tuberculosis, small bowel lymphoma, Yersinia infection, neuroendocrine tumor or inflammatory bowel disease, rather than celiac disease^[5,6].

The histological findings in the terminal ileum, raised anti-tissue transglutaminase Ab IgG, raised anti-tissue transglutaminase Ab IgA (upon normalization of her serum IgA), positive HLA DQ2 and resolution of histological features after gluten free diet in this patient confirmed the diagnosis of celiac disease. In view of the diagnosis of celiac disease, the possibility of terminal ileum lymphoma as a cause for her intestinal obstruction was highly suspected. However, after a follow-up of a period of 24 months, there was no evidence of lymphoma in this patient.

Therefore, clinicians should bear in mind the possibility of celiac disease in patients presenting with intestinal obstruction. This will allow clinicians to avoid an unnecessary laparotomy in those with an idiopathic cause for the intestinal obstruction complicating celiac disease. In this patient, the intestinal obstruction resolved with expectant management and withdrawal of gluten. As we were able to diagnose the celiac disease early, the diagnosis of intestinal obstruction complicating celiac disease was made early.

As conservative measures can lead to resolution of intestinal obstruction due to an idiopathic cause in celiac disease^[3], an early diagnosis will enable clinicians to allow conservative measures and the effect of gluten withdrawal to take effect before proceeding to a laparotomy.

In addition to the obstruction at the terminal ileum, this patient also had fluid collection in her abdomen. Fluid collection in the abdomen is also an uncommon presentation of celiac disease. Although, the fluid was still present on Day-6 of admission, we decided to observe this rather than to perform diagnostic tapping. The gluten free diet

also led to complete resolution of the fluid collection as evidenced on the CT performed four weeks after a gluten free diet.

One possible reason for the atypical site of obstruction in the terminal ileum may be due to gluten-driven inflammation in the terminal ileum. As we saw on histology, typical features of celiac disease were only found in the terminal ileum and jejunum; but, not in the duodenum. The changes in the terminal ileum may have resulted in mucosal inflammation in the terminal ileum. The mucosal inflammation in the terminal ileum may have impaired both the smooth muscle contractility and release of neurotransmitters in the terminal ileum. This may have resulted in impaired motor abnormalities in the terminal ileum and intestinal obstruction to occur at this site^[3].

In conclusion, intestinal obstruction at the terminal ileum and fluid collection in the abdomen can be a complication of celiac disease. A gluten free diet can lead to resolution of the idiopathic intestinal obstruction and fluid in the abdomen in celiac disease.

REFERENCES

- 1 Farrell RJ, Kelly CP. Celiac sprue. *N Eng J Med* 2002; **346**: 180-188
- 2 Biaggi F, Poggioli G, Mazzoni G, Corazza GR. Intestinal strictures. *Lancet* 1998; **352**: 876
- 3 Koklu S, Coban S, Ertugrul I, Basar O, Ensari A, Akyol A, et. al. Intestinal obstruction in Celiac disease: case report. *Dig Dis Sci* 2004; **49**: 1485-1488
- 4 Baer AN, Bayless TM, Yardley JH. Intestinal ulceration and malabsorption syndromes. *Gastroenterology* 1980; **79**: 754-765
- 5 Bojic D, Markovic S. Terminal ileitis is not always Crohn's disease. *Ann Gastroenterol* 2011; **24**: 271-275
- 6 Green PH, Rostami K, Marsh MN. Diagnosis of Celiac's disease. *Best Pract Res Clin Gastroenterol* 2005; **19**: 389-400

Peer reviewer: Edward J. Ciaccio, Medicine - HP804, Columbia University, 180 Fort Washington Avenue, New York, NY 10032, the United States.