

Therapeutic Efficacy of Aloe Vera high Molecular Fractions for Treatment of Hepatic Fibrosis, Type 2 Diabetes, Bed Sores and Lichen Planus

Akira Yagi

Akira Yagi, Placenta-Aloe research Institute, Fukuoka Bio Factory 204, Japan Bio Products Co., Ltd. 1488-4 Aikawa-machi, Kurume-shi, Fukuoka, 839-0861, Japan

Correspondence to: Akira Yagi, Placenta-Aloe research Institute, Fukuoka Bio Factory 204, Japan Bio Products Co., Ltd. 1488-4 Aikawa-machi, Kurume-shi, Fukuoka, 839-0861,

Japan. akirayagi@nexyzbb.ne.jp

Telephone: +81-942-34-2216

Fax: +81-942-34-2333

Received: November 7, 2012

Revised: February 10, 2013

Accepted: February 12, 2013

Published online: July 21, 2013

ABSTRACT

Aloe vera gel has been widely used for healing of burn wound and hepatitis with paucity of therapeutic evidence. One of the unclear therapeutic indications may be responsible to contamination and variation of coloured materials and ingredients in *aloe vera* gel. *Aloe vera* gel is separated from the rind of the leaf by filleting and separating the inner gel from the outer leaf rind with mechanical or handle way. Due to the differences in biological ingredients of test products, therapeutic evaluation may be variable. Coloured materials in *aloe vera* leaf gel, such as barbaloin and aloe-emodin with carcinogenicity, could not be completely removed without processing by charcoal treatment. The quality control of the biologically active principles is necessary for therapeutic applications. By using the patented hyper-dry system after washing out coloured materials with running water, aloe high molecular fractions (AHM) were obtained in original and natural form containing less than 10 ppm of barbaloin. AHM mainly contained high molecular fractions, such as polysaccharide (acemannan) and glycoprotein (verectin) showing immunomodulatory and anti-inflammatory activities. On the basis of chemical and biochemical properties, AHM were examined for the therapy designed by the implementation of well-controlled clinical trials, and exhibited the efficacy as immunomodulators for viral infection-induced hepatic periportal fibrosis and type 2 diabetic patients, and as wound and ulcer-healing ointment to patients suffering from bed sore and lichen planus. Therefore, AHM were considered to be a novel low-cost and safe drug of natural origin, indicating a possible therapeutic efficacy in prevention of age-related diseases by slowing aging process.

© 2013 ACT. All rights reserved.

Key words: Therapeutic efficacy; *Aloe vera* high molecular fractions; Hepatic fibrosis; Type 2 diabetes; Bed sores; Lichen planus

Yagi A. Therapeutic Efficacy of *Aloe vera* high Molecular Fractions for Treatment of Hepatic Fibrosis, Type 2 Diabetes, Bed Sores and Lichen Planus. *Journal of Gastroenterology and Hepatology Research* 2013; 2(7): 672-679 Available from: URL: <http://www.ghrnet.org/index.php/joghr/article/view/430>

INTRODUCTION OF ALOE VERA HIGH MOLECULAR FRACTIONS

Traditional hand-filleted aloe processing is very laborious intensive and does not fully remove barbaloin and anthraquinones which have laxative effect. *Aloe vera* gel from parenchyma cells is composed of mucilagenous jelly, containing about 0.5% total aloe solids in the inner leaf gel, and when ground into slurry and exposed to air, the gel is rapidly oxidized and loses its bioactivities by self-enzyme digestion. In order to remove barbaloin and anthraquinones, the gel slurry was passed through carbon-coated plates. The *in vivo* study exhibited that coloured substances participated clearly with carcinogenic properties^[1], and International Aloe Science Council (IASC), a non-profit association of *aloe vera* global industry, recommended the limitation of coloured substances in *aloe vera* commodities less than 10 ppm^[2]. Pasteurization by a high temperature short time (HTST) treatment at 85-95°C for 1-2 min is an effective method to avoid the loss of biological activities of the gel slurry. However, the potentially beneficial aloe constituents with high molecular weight were mostly lost or denaturalized, when the removals of barbaloin and anthraquinones through carbon-coated plates and pasteurization above 60°C were performed. Therefore, appropriate processing techniques using HTST-, spray-dry- or freeze-dry-systems should be employed to retain and enhance the biological native activities due to aloe polysaccharide, protein and glycoprotein moieties in *aloe vera* gel.

By using the patented hyper-dry system after washing out coloured materials with running water from *aloe vera* jell slurry, *aloe vera* high molecular fractions (AHM) containing native ingredients of polysaccharide (acemannan) and glycoprotein (verectin), were obtained in a high yield.

This review aims to provide the therapeutic efficacy of AHM

for treatment to hepatic fibrotic, type 2 diabetic, bed sores and lichen planus patients, and the possible beneficial uses by long-term treatment of *aloe vera* gel.

ANTI-FIBROTIC EFFECT OF AHM IN VIRAL INFECTION-INDUCED HEPATIC PERIportal FIBROSIS

Studies on *aloe vera* extract to anti-hepatotoxicity and liver fibrosis were mostly concerned with coloured substances, such as aloe emodin and barbaloin in *aloe vera* leaf^[3,4]. Recent *in vivo* studies on *aloe vera* gel treated with charcoal, showed hepato-therapeutic activity in alcohol-induced hepatic damage^[5] and hepato-protective activity on hepatic cholesterol and oxidative status in aged rats^[6].

Present review shows the anti-oxidative and anti-fibrotic effects of AHM in patients with liver fibrosis.

Sample preparation

AHM were prepared from the gel part, by washing out coloured materials with running water, followed by using the patented hyper-dry system in combination of freeze-dry technique with micro wave and farinfrared radiation. Barbaloin content was less than 10 ppm in the powder form of AHM by HPLC analysis. Colony formulation unit: less than 300/g: Na⁺ approx. 430 mg/100 g: Ca²⁺ approx. 2100 mg/100 g. The pore size of AHM was 5.090 µm by use of Master size 2000 of Malvern Instrument, Ltd., Tokyo. AHM showed the presence of acemannan having about 1×10⁶ D of molecular weight and glycoprotein (verectin) having 29×10³ D of molecular weight by examinations on size exclusion HPLC. Verectin composed of carbohydrate and protein in a ratio of 10.7% and 82.0%, respectively, was contained in AHM at a concentration of 20% by immunochemical assay^[7].

Patients

Fifteen healthy volunteers as the control group and 40 patients were included. All the patients were subjected to full history, through clinical examination, biopsy and histological examinations, and laboratory investigations. For assessment of liver fibrosis scores, all patients underwent liver biopsy as part of the neutral diagnostic procedure and were sub-classified according to the score for the histological activity index (HAI, Fibrosis stage: F1 to F4). Patients with a history of gastrointestinal bleeding and chronic liver disease (Wilson's disease, hemochromatosis, α 1-antitrypsin deficiency, or hepatocellular carcinoma), active intravenous drug abuse, and liver transplantation were excluded. The patients were randomly subdivided into two equal groups: the conventional group was treated with the conventional treatment with placebo (starch), and AHM group were treated with the conventional treatment with 0.15 g/d AHM, both for 12 consecutive weeks. Treatment of each patient was according to following standard protocol: hepatic C patients were treated with pegylated interferon (180 µg/wk)+ribavirin (800-1200 mg/d) and hepatitis B patients were treated with adefovir (10 mg/d) or lamivudin (100 mg/d) (Table 1).

Histological assessment

Liver biopsy fragments were fixed in 10% neutralized formaldehyde, embedded in paraffin, and then stained with hematoxylin and eosin. Liver biopsy samples were examined in a double-blinded fashion using a Metavir scoring system (the grade is a number based on the degree of inflammation, which is usually scored from 0 to 3 or 4 with 0 being no activity and 3 or 4 considered severe activity, and the

fibrosis score is assigned a number from 0 to 3 or 4: 0=no scarring; 1=minimal scarring; 2=scarring has occurred and extends outside the areas in the liver that contains blood vessels; 3=bridging fibrosis is spreading and connecting to other areas that contain fibrosis, 4=cirrhosis or advanced scarring of the liver). Blood samples were withdrawn; serum was separated and utilized for biochemical analysis. The patients were investigated before and after treatment (Table 2).

Table 1 Characteristics of the study populations (mean±SD).

Parameter	Control group (n=15)	Conventional group ¹ (n=20)	AHM group ² (n=20)
Age (year)	40.2±10.4	41.6±15.4	40.5±13.9
Sex(M/F)	15/0	15/5	17/3
HBV	-	12	12
HCV	-	8	7
Bilharziasis	-	0	1
Fibrosis Stage			
F1	0	3	3
F2	0	9	10
F3	0	8	7
F4	0	0	0
Total bilirubin(mg/dL)	0.55±0.20	1.19±0.20	1.18±0.19
ALT (IU/L)	19.4±8.2	87.4±8.4	85.9±9.1
AST(IU/L)	25.0±4.3	50.8±6.7	51.0±4.2
ALP(IU/L)	55.0±14.3	225.0±85.6	223.0±74.5
Albumin(g/dL)	4.4±0.1	4.2±0.2	4.3±0.1
INR	0.88±0.22	1.47±0.3	1.51±0.2

¹ Patients treated with the conventional treatment with placebo(starch) for 12 consecutive weeks; ² Patients treated with the conventional treatment with 0.15 g/d AHM for 12 consecutive weeks. ASP: Aspartate aminotransferase; ALT: Alanine aminotransferase; ALP: Alkaline phosphatase; INR: International normalization ratio; HBV: Hepatitis B virus; HCV: Hepatitis C virus; AHM: Aloe vera high molecular fractions.

Table 2 Histopathological evaluation of the patients before and after treatment n (%).

	Conventional group			AHM group		
	Before	After	χ ² /p	Before	After	χ ² /p
Grade						
0	0 (0)	3 (15)	4.390/	0 (0)	3 (15)	9.930/
1	3 (15)	5 (25)	0.223	3 (15)	9 (45)	0.024 ¹
2	9 (45)	6 (30)		10 (50)	4 (20)	
3	8 (40)	6 (30)		7 (35)	4 (20)	
Stage						
0	0 (0)	0 (0)	0.000/	0 (0)	2 (10)	6.170/
1	3 (15)	3 (15)	1.000	3 (15)	7 (35)	0.103
2	9 (45)	9 (45)		10 (50)	4 (20)	
3	8 (40)	8 (40)		7 (35)	7 (35)	

¹ p < 0.05 vs conventional group. AHM: Aloe vera high molecular fractions.

Biochemical assays

Serum activity of aspartate aminotransferase (AST), alanine aminotransferase (ALT), alkaline phosphatase (ALP), hyaluronic acid (HA), transforming growth factor-β (TGF-β) and matrix metalloproteinase-2 (MMP-2) were determined. The reduced glutathione (GSH) and malondialdehyde (MDA) levels in liver were assayed (Table 3) and the expression of hepatic α-smooth muscle actin (α-SMA) was identified by immuno-histochemistry.

Statistical analysis

Data were statistically analyzed by 2-way analysis of variance (ANOVA) (repeated measure type) to compare the results before (baseline) and after treatment within the same group, and unpaired Student's test was used to compare the means of different groups. Significant differences between the groups were statistically analyzed using one-way ANOVA using the computer program SPSS for Windows version 10 (Chicago, IL, United States). All results were expressed as mean±SD. The level of significance was set at P < 0.05.

Table 3 Biochemical parameters of hepatitis B virus-induced fibrosis and hepatitis C patients after treatment.

Parameter	Conventional group		AHM group	
	HBV (n=12)	HCV (n=8)	HBV (n=12)	HCV (n=7)
ALT(IU/L)	50.1	47.2	50.1	37.3
AST (IU/L)	40.4	38.3	30.3	28.1
ALP(IU/L)	173.3	177.8	156.3	160.4
MDA (μmol/g)	596.1	607.4	571	565
GSH (μg/g)	22.9	20.4	23.7	27.6
TGF-β (pg/mL)	38.2	41.1	34.6	38.4
HA (ng/mL)	63.3	59.7	58.1	52.1
MMP-2 (ng/mL)	259.1	277.8	238.8	256.7

ALT: Alanine aminotransferase; AST: Aspartate aminotransferase; ALP: Alkaline phosphatase; MDA: Malondialdehyde; GSH: Reduced glutathione; TGF-β: Transforming growth factor-β; HA: Hyaluronic acid; MMP-2: Matrix metalloproteinase-2; HBV: Hepatitis B virus; HCV: Hepatitis C virus.

Results and Discussion

At the start of the study, the hematoxylin and eosin staining revealed fibro-proliferated bile ducts, thick fibrous septa and dense inflammatory cellular filtration in the patients before treatment.

Histological findings of liver samples strongly supported the release of aminotransferases by damaged hepatocytes and the protective effect of AHM. The use of AHM for 12 weeks significantly ameliorated the fibrosis, inhibited the inflammation, and resulted in minimal infiltration and minimal fibrosis compared to the conventional group (Table 2), (Figure 1). The enzyme activities of the liver (AST, ALT and ALP) were attenuated after treatment in both groups and the decrease in AHM group was more significant as compared with the conventional group (Figure 2). Similar to the AST level, the MDA levels were significantly higher before treatment, and were attenuated after treatment in both groups (Figure 3). In contrast, the hepatic glutathione content in the patients was increased significantly in the AHM group compared to the control. The serum levels of the fibrosis markers (HA, TGF-β and MMP-2) were also reduced significantly after treatment (Table 3, Figure 4). There was no significant difference of fibrosis markers between HBV-induced fibrosis and HCV after treatment (Table 3). The expression of α-SMA was modified in patients before and after treatment as compared with the normal controls. In the conventional group, there was only thin and incomplete parenchymal α-SMA positive septum joining the thickened centrilobular veins, while in the AHM group few α-SMA positive cells were present in sinusoid and lobule after treatment (Figure 5).

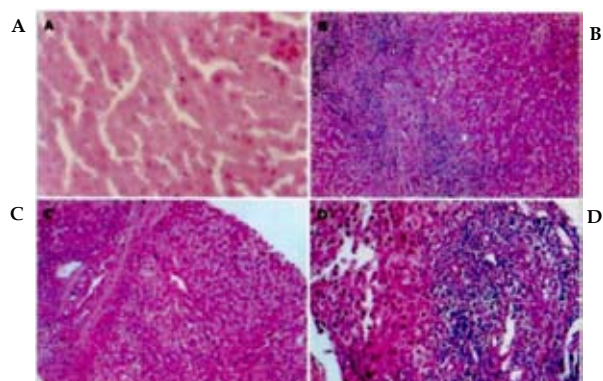


Figure 1 Hematoxylin and eosin staining of liver tissues (HE, ×200). A: Control group showed normal lobular architecture and cell structure; B: Patients before treatment showed fibro-proliferated bile ductules, thick fibrous septa and dense inflammatory cellular infiltration; C: The conventional group showed moderate fibrosis with inflammatory infiltration and slight ballooning of liver cells; D: Aloe vera high molecular fractions group showed minimal infiltration and minimal fibrosis.

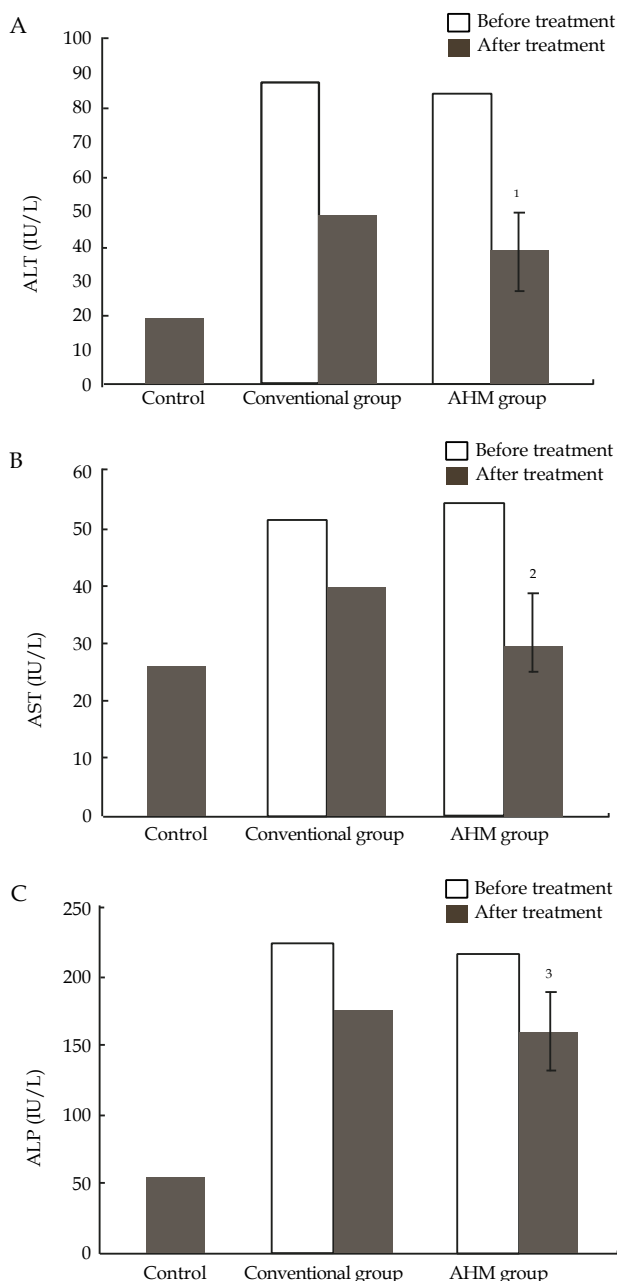


Figure 2 Serum activity of alanine aminotransferase (ALT), aspartate aminotransferase (AST) and alkaline phosphatase (ALP) of hepatic fibrosis patients and controls; A: Serum activity of alanine aminotransferase (IU/L) of hepatic fibrosis patients and controls; B: Serum activity of aspartate aminotransferase (IU/L) of hepatic fibrosis patients and controls; C: Serum activity of alkaline phosphatase of hepatic fibrosis patients and controls, ¹ P<0.05, ² P<0.05, ³ P<0.05, vs before treatment and conventional group; Data are presented as mean±SD. AHM: Aloe vera high molecular fractions.

Oral supplementation with AHM in conventional treatment of HCV and HBV could be helpful in alleviating the fibrosis and inflammation of hepatic fibrosis patients. AHM had antifibrotic effects which could be attributed to its ability to attenuate oxidative stress and enhanced the collagenolytic activity. This study provided evidences that AHM could be used as an immunomodulatory adjunct to prevent and/or treat hepatocellular damage in hepatic fine periportal fibrosis^[8].

POSSIBLE HYPOGLYCEMIC EFFECT OF AHM ON TYPE 2 DIABETIC PATIENTS

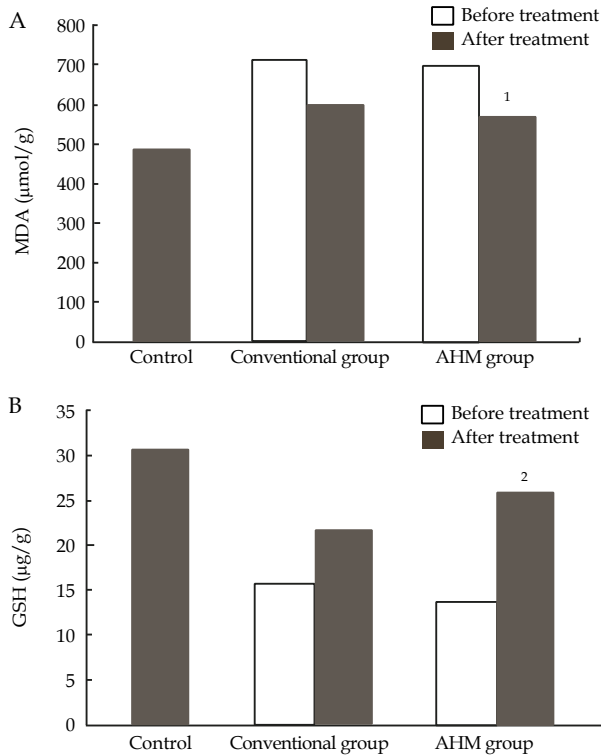


Figure 3 Hepatic malondialdehyde (MDA) and glutathione (GSH) of hepatic fibrosis patients and controls. A: Hepatic malondialdehyde ($\mu\text{mol/g}$) of hepatic fibrosis patients and controls; B: Hepatic reduced glutathione ($\mu\text{g/g}$) of hepatic fibrosis patients and controls. ¹ $P < 0.05$, ² $P < 0.05$ vs before treatment and conventional group. Data are presented as mean \pm SD. AHM: Aloe vera high molecular fractions.

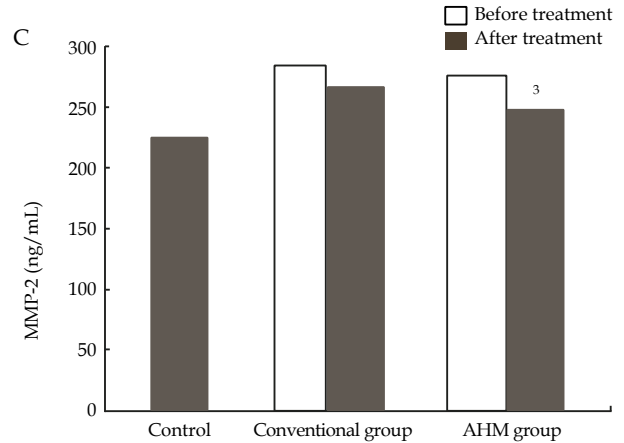
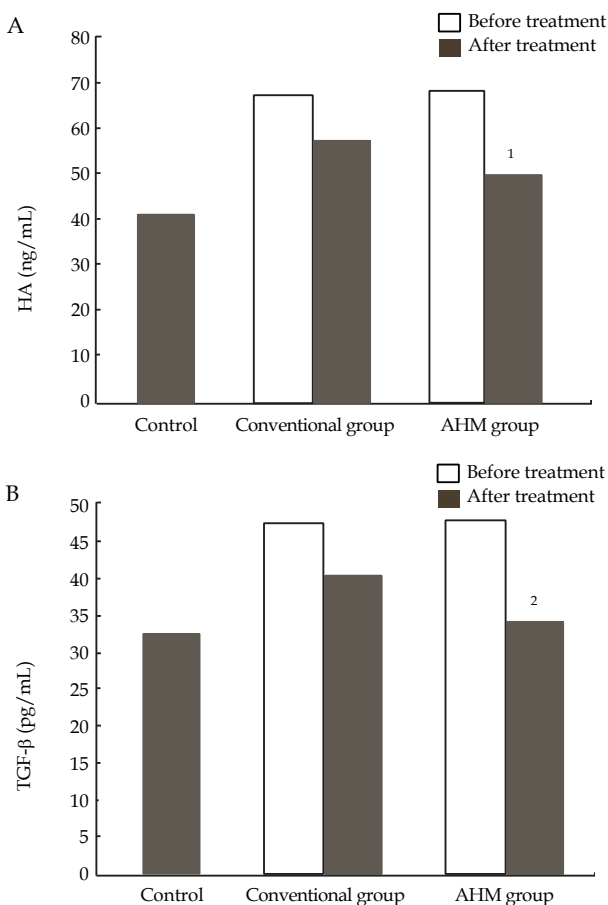


Figure 4 Serum hyaluronic acid (HA), transforming growth factor- β (TGF- β) and matrix metalloproteinase-2 (MMP-2) of hepatic fibrosis patients and controls; A: Serum hyaluronic acid (ng/mL) of hepatic fibrosis patients and controls; B: Serum transforming growth factor- β (pg/mL) of hepatic fibrosis patients and controls; C: Serum matrix metalloproteinase-2 (ng/mL) of hepatic fibrosis patients and controls. ¹ $P < 0.05$, ² $P < 0.05$, ³ $P < 0.05$ vs before treatment and conventional group. Data are presented as mean \pm SD. AHM: Aloe vera high molecular fractions.

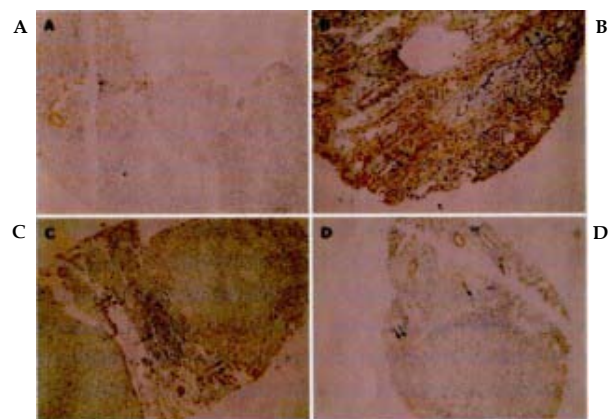


Figure 5 Immunohistochemical staining of α -smooth muscle actin. A: Section of liver from control showing negative staining (PAP \times 125); B: Section of liver from liver fibrosis patients before treated showing dense fibrotic reaction with strong positivity for α -smooth muscle actin (α -SMA) $\uparrow\uparrow$ and dense mononuclear cellular infiltration \uparrow (PAP \times 225); C: Section of liver from conventional group after treatment showing dense mononuclear inflammatory infiltration \uparrow and moderate positivity for α -SMA in fibrotic lesion $\uparrow\uparrow$ (PAP \times 125); D: Section of liver from AHM group after treatment showing moderate mononuclear cellular infiltration \uparrow surrounded by minimal fibrotic reaction stained mildly with α -SMA $\uparrow\uparrow$ (PAP \times 125).

In vivo study of the immunomodulatory activity by oral administration of processed *Aloe vera* gel (PAG) reduced the growth of *Candida albicans* in streptozocin-induced diabetic mice. PAG administration did not increase ovalbumin-specific cytotoxic T lymphocyte generation in normal mice, but did increase it in high-fat-diet induced diabetic mice. The *in vivo* study provided the clear evidence for immunomodulatory activity by orally administered *Aloe vera* gel^[9]. These findings provide for possible contributions of AHM to an immunomodulatory activity.

The present study aims to evaluate the hypoglycemic effect of AHM on type 2 diabetic patients uncontrolled with their hypoglycemic medications.

Sample preparation: AHM containing less than 10 ppm of barbaloin, polysaccharide (molecular weight 1×10^6 D) and glycoprotein, verectin (molecular weight, 29×10^3 D), were prepared by the patented hyper-dry systems.

Patients

The BMI values calculated ($BMI=kg/m^2$) for each patient showed that all patients were over weight. Blood pressure measures showed that none of them was hypertensive. No alterations in the patient's blood pressure or a significant change in their body weight could be detected during the study. Fifteen patients (nine males and six females) with T2DM uncontrolled with their oral hypoglycemic medication (metformin 500 mg twice daily and glibenclamide 5 mg twice daily) were enrolled in the study. The outpatients were selected for the study using the following criteria: **Inclusion criteria:** (1) Their ages ranged from 42-55 years old; (2) High fasting blood glucose level (>200 mg/dL); (3) Freely consented to participate this study. **Exclusion criteria:** (1) Liver disease as defined by abnormal level of ALT, AST and alkaline phosphatase; (2) Kidney disease as defined abnormal levels of serum BUN and creatinine; (3) Patients with clinical problems causing hyperglycemia including infection, and thyroid disease; (4) Patients taken medications known to modify glucose metabolism as corticosteroids; (5) Morbid obesity ($BMI>40$ kg/m^2).

Design

Before administrating AHM, each patient's body mass index was calculated ($BMI=kg/m^2$). Systolic and diastolic blood pressure were measured.

All the patients received two tablespoonful (0.05 g) of AHM three times daily for twelve weeks and continued taking their oral hypoglycemic medications (metformin 500 mg twice daily and glibenclamide 5 mg twice daily). Blood samples were analyzed for fasting blood glucose (FBG), glycosylated hemoglobin (HbA1c), triglycerides (TG), cholesterol, serum aspartate aminotransferase (AST), serum alanine aminotransferase (ALT) and serum creatinine before the study. Blood samples were obtained again weekly for measurement of FBG, and every 2 weeks for TG and cholesterol analysis. The HbA1c values were evaluated every 4 weeks, while serum activities AST and ALT and serum creatinine levels were determined at the end of the study.

Statistical analysis

Student's paired *t*-test was used to determine the difference in biochemical changes between the patients before and after the administrations of AHM. $P<0.001$.

Results and Discussion

There were no adverse effects reported by the patients due to the intake of AHM. AHM produced significant decrease in serum level of fasting blood glucose by 32% after treatment of 6 weeks from the start of the study and continued thereafter. A significant decrease in triglycerides level by 35% was only observed 4 weeks after treatment and continued thereafter, but treatment of the patients with AHM with their oral hypoglycemic agent did not result in any change in cholesterol levels compared to before the treatment. A significant reduction by 20% compared to before treatment of the glycosylated hemoglobin values in diabetic patients was observed 4 weeks after administration of AHM and continued thereafter for 12 weeks. No deteriorate effects on kidney and liver functions were apparent on the serum creatinine level in type 2 diabetic patients.

AHM administration exhibited significant hypoglycemic effect and reduction of glycosylated hemoglobin values. And it can lowered not only the serum fasting blood glucose but also the triglyceride levels which are often high in diabetic patients. Oral administration of AHM to type 2 diabetic patients may alleviate vascular complications likely via activation of systemic immune defenses in the absence of

any discernable hepato- and nephro-toxicity, and AHM may function as an immunomodulator^[10].

CASE REPORTS OF BED SORE USING AHM

It has been reported that the Japanese have higher rate of life expectancy and that Japan is rapidly becoming a super aging society. Almost 5 per cent of aged, who develop disease such as cerebrovascular related disorders, mental problems, fractures, cancer and infections, also end up suffering from bed sores. It has been found that patients often opt for treatment, when the bed sores become very severe and adding more complications in their treatment. It may be presumed that prevention and early detection are vital for the treatment of bed sores patients.

In present study, we aim to test AHM formulation for its efficacy and activity on bed sores patients.

Sample preparation

AHM was prepared from the gel part, by washing with running water using the patented freeze-drying systems in which barbaloin content was less than 10 ppm in the powder form.

The AHM ointment is a mixture of the hydrophilic ointment and AHM at 0.1% by weight.

Patients

The clinical treatments were given by application of AHM ointment for bed sores from I to II degree ulcer patients.

Pre-treatment

In case the skin ulcer, therapeutic drug had been used on a patient, and an isotonic sodium chloride solution was applied for washing it out and a gauze dressing was put for 7 days. As a positive control, gentamicine ointment was applied.

Treatment

After the skin ulcer therapeutic drug had been washed out, AHM ointment was applied to the diseased part once or twice a day after washing it with an isotonic sodium chloride solution.

Table 4 Judgment.

Score	Criteria
Extremely improved	Improved 6 points and more
Improved	Improved 3 points and more
Slightly improved	Improved less than 3 points
Not improved	Improved 0 point
Aggravation	Minus points

Design score prepared to judge a process and condition by points; D: depth point 0-5; E: exudates point 0-3, Size point 0-6, Inflammation/ infection point 0-3; G: granulation tissue point 0-5; N: necrosis tissue point 0-2; P: pocket point 0-4; The Judgment was given for 3 months after starting the treatment.

Table 5 Design score.

Case no. age/gender	Design score			Side effect	Results
	start	1 st -m	2 nd -m		
1. 52/f	4	0		None	Improved
2. 80/f	5	2	0	None	Improved
3. 92/m	11	2	0	None	Extremely improved
4. 87/f	9	4	0	None	Extremely improved
5. 63/f	9			None	Not improved
6. 90/m	6	8		None	Aggravated

Design score prepared to judge a process and condition by points. D: depth point 0-5; E: exudates point 0-3, Size point 0-6, Inflammation/ infection point: 0-3; G: granulation tissue point 0-5; N: necrosis tissue point 0-2; P: pocket point 0-4; 1st-m: first month after the start; 2nd-m: second months after the start.

Results and Discussion

The results have been shown that AHM in the ointment form indicated a high possibility to cure bed sores. It is very difficult to cure, due to the patient's peculiar conditions, such as old age, inability of the patients to turn by himself/herself and also due to complications caused by other symptoms. We confirmed the effectiveness of AHM ointment in six cases of bed sores with two cases of positive control, using the Design Score and by checking the side effects. Table 4 and 5 showed Judgment and Design Score.

AHM ointment had potential for quick remedy, which will greatly help the aged patient's Quality of Life and show high efficacy compared to gentamicine ointment. It was speculated that polysaccharides moiety in AHM can physically absorb and hold the exudates via the osmotic pressure differences, leading to desirable moisture condition to minimize the pain by skin ulcer.

Present report showed efficacy of the pre-clinical trials for bed sores ulcer patients in I to II degree by the external use of AHM ointment (Figure 6)^[11].

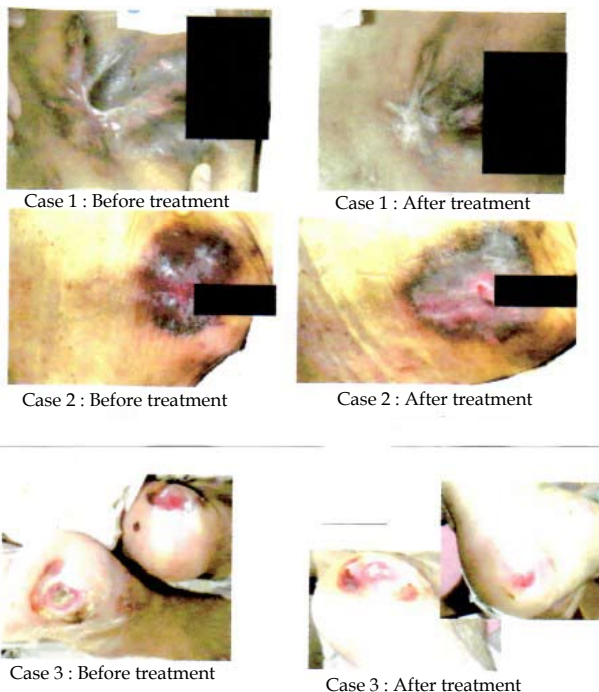


Figure 6 Case 1, 2, and 3. Case 1: An age 52 female patient with bed sore on her sacral region; Case 2: An age 80 female patient suffered from a syndrome for ash and a sacral region bed sore; Case 3: An age 92 male patient developed a skin ulcer on his right heel which was 2 cm in diameter.

A SELF-CONTROLLED SINGLE BLINDED CLINICAL TRIAL TO EVALUATE ORAL LICHEN PLANUS (OLP) AFTER TOPICAL TREATMENT WITH ALOE VERA-EFFECT OF ALOE VERA ON LICHEN PLANUS-

Current reports on OLP suggested that OLP is a T cell-mediated autoimmune disease in which auto-cytotoxic CD⁸⁺ T cells trigger the apoptosis of oral epithelial cells^[12], but the precise etiology of OLP is unknown. There are several reports to evaluate clinical treatments for OLP, such as placebo-controlled randomized clinical trials.

The object of this study is to evaluate the efficacy of a self-

controlled single blinded clinical trial by topical treatment with AHM ointment in oral lichen planus patients.

Sample preparation

AHM were obtained from water-washed gel part of *Aloe vera* and processed by the patented hyper-dry systems. The macromolecular aloe ointment is a mixture of the hydrophilic ointment composed of carboxymethylcellulose sodium, white vaseline and water at a ratio of 1:1:1 and AHM at 0.1% by weight.

Patients

Twenty patients (15 male and 5 female) aged at least 18 years recruited from the outpatients. In all cases the diagnosis met currently accepted criteria. Clinical criteria included the presence of bilateral lesions, with erythematous and/or erosive lesions, painful and no specific treatment within 4 weeks prior. The exclusion criteria were (1) The pregnant or breast feeding women; (2) Lesions in contact with dental amalgam; (3) The use of drugs possibly causing a lichenoid reaction; (4) Any treatment for OLP or immuno-suppressive drugs for pre-existing diseases within the 4 weeks prior to the study; and (5) A history of hypersensitivity to *Aloe vera*.

Treatment protocol

Each patient was instructed to manually apply AHM ointment on the affected right side of oral mucosa three times daily with the aid of gauze and the placebo gel to left side, and all patients were blind to the treatment assignment. Patients were instructed not to eat or rinse their mouth for at least one hour after application of the treatment. Each patient was examined at the beginning of treatment and then after 4 and 8 weeks of therapy. The clinical effect of treatment response was evaluated based on the criteria of Carrozo and Gandolfo: Complete remission (few or no symptoms), Partial remission (the symptoms have decreased with erythematous areas) and No response (the symptoms persist).

Results and Discussion

A self-controlled blind protocol to assessment clinical improvement

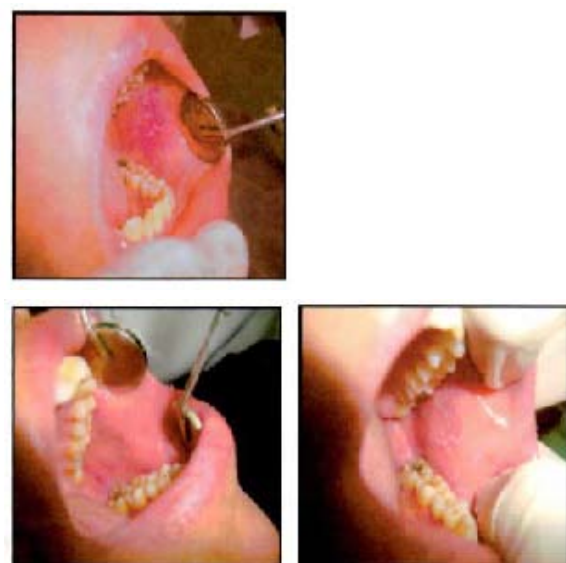


Figure 7 Right side treated with Aloe vera high molecular fractions (AHM) ointment at baseline (lower right), 4 (upper) and 8 (lower left) weeks. The initial presentation of reticular pattern of fine white striae typical of OLP (lower right) disappeared with improvement treated with AHM ointment after 8 weeks (lower left).

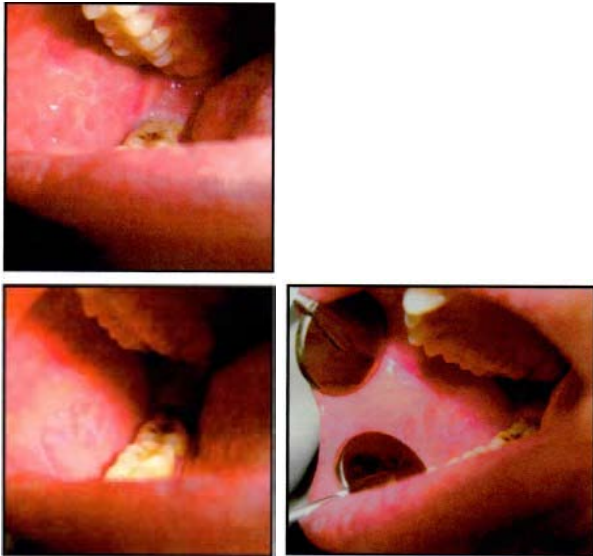

Figure 8 Left side treated with placebo at baseline (upper), 4 (lower left) and 8 (lower right) weeks. The surrounding mucosa with erythematous, atrophic area with faint reticular striae (baseline) treated with placebo continued during 8 weeks (lower right).

and pain response was used in this study. The clinical results of twenty patients showed a rapid subjective and objective improvement with topical AHM ointment treatment. Fifteen patients (75%) had complete remission at treated side (asymptomatic and absence of erythematous and mucosal erosion) and two patients (10%) had partial remission (decrease in symptoms with incomplete resolution erosion), while one patient showed no response to treatment (5%), and placebo sides showed partial remission responded in two cases (10%) only and no responded in other sides. Only one patient dropped out of the study (Figure 7 and 8).

Our hypothesis is that macromolecular acemannan and anti-oxidative- and Cox-2-inhibitory glycoprotein, verectin, as an immunomodulator in AHM, can physically hold lichen planus via the osmotic pressure difference, leading to desirable moisture contribution to minimize the pain from lichen planus. AHM ointment also provides a rich nutrition, playing a part of role in the regeneration of tissue, texture and epidermis that need to be restored in wound. In addition, glycoprotein fraction, verectin, in AHM revealed anti-inflammatory activity and wound-healing properties in *in vitro* study^[13]. Thus, the remarkable point of AHM ointment for therapeutic trials is fully expected not only for lichen planus but also for general wound-healing.

The effect of AHM ointment on OLP patients was significantly effective than that of placebo, both in clinical signs and pain scores. AHM ointment showed well-tolerated, safe and effective treatment to OLP patients^[14].

CONCLUSION

Burn wound healing is one of major indications of *Aloe vera* gel^[15], and acemannan, a β -(1-4)-linked acetylated mannan and a main component of *Aloe vera* gel, showed inhibition of inflammation and acceleration of wound healing^[16]. Acemannan in the presence of IFN γ indicated induction of apoptosis in a macrophage cell line RAN 264.7 through a mechanism involving the inhibition of bcl-2 expression^[17]. Acemannan also stimulated differentiation of immune dendritic cells, which are most important accessory cells for primary immune responses. These findings expressed that the adjuvant activity of acemannan is due to its capacity to promote differentiation

of immature dendritic cells^[18]. Acemannan, thus, exhibited multiple immunomodulatory effects which are important to burn wound healings.

On the other hand, verectin was stable at least for 4 years at 4°C under desiccation conditions by immunochemical assay and was destroyed completely under pasteurization at 80°C for 1 h^[7]. Verectin, a radical scavenging glycoprotein in AHM, inhibited Cox-2 and thromboxane A2 synthase level, suggesting the participation to human immune system^[13]. The verectin-derived N-terminal octapeptide (Asp-Glu-Asp-Asn-Val-Leu-Leu-Thr), obtained by a novel procedure for peptide sequencing from verectin, exerted a significant *in vitro* inhibitory effect on the growth of cell numbers of tumor, Ehrlich ascites carcinoma, which was correlated well with the *in vivo* prolongation of life span of the tumor transplanted mouse^[19]. Therefore, verectin may function as an anti-oxidative, radical-scavenging, Cox-2 inhibiting, and anti-tumor active component together with acemannan as adjuvants in AHM. In *in vivo* study, a glycoprotein fraction (G1G1M1D12), having molecular weight of about 5.5 KD isolated from *aloe vera* gel exhibited enhancement of wound-healing in hairless mice by day 8 after injury with significant cell proliferation^[20]. The wound-healing effect due to glycoprotein fractions, G1G1M1D12 and verectin in AHM, are fully expected in treatment for ulcer skin in bed-sores patients and lichen planus patients.

Aloe vera gel which enhanced bioavailability of vitamin C and B₁₂ in human healthy subjects^[21] was considered to play a role of an intestinal transport promoter and/or a drug permeation-enhancement potentiator in drug delivery system^[22,23]. *Aloe vera* gel supplementation in larval diet extended adult longevity in both the male and female flies without reducing fecundity^[24]. Long-term *aloe vera* ingestion on age-related disease in rats slightly suppressed the occurrence of fatal chronic nephropathy and thrombosis in the atrium of the heart. The analysis of longevity data based on the mortality rate doubling time in demographic measurements of aging, indicated lightening of the disease burden during the aging process and slowing the death rate of rats in life-long term ingestion of *aloe vera* gel. Life long ingestion of *aloe vera* gel showed several positive and beneficial effects without any adverse effects in old and young animals based upon longevity and pathological examinations^[25].

AHM and *aloe vera* gel are not exactly composed of same constituents, but the potential and beneficial efficacy of AHM, which were produced under quality control from *aloe vera* gel by the patented hyper-dry system after washing out coloured materials with running water, were sufficiently approved as immunomodulator by the design and implementation of well-controlled clinical trials for viral infection-induced hepatic periportal fibrotic, type 2 diabetic, bed sore- and lichen planus-suffering patients.

In the light of the potential of AHM for treatment of above severe age-related diseases, the findings should point to novel low-cost and safe drug of natural non-toxic origin, which can be afforded by developing countries. AHM provided a possible therapeutic efficacy for prevention of age-related diseases by slowing aging process.

ACKNOWLEDGMENTS

The author expresses deep thanks to Dr. Byung Pal Yu, emeritus professor, Department of Physiology, University of Texas Health Science Center, San Antonio, Texas, USA for notable advices to longevity study of *aloe vera* gel.

REFERENCES

- 1 Boudreau MD, Mellick P, Olson G, Felton R, Thron B, Beland F. Clear evidence of carcinogenic activity by a whole leaf extract of *Aloe barbadensis* Mill. (*A. vera*) in F344/N rats. *Toxicol Sci* 2012 Sep 11
 - 2 <http://www.iasc.org/complete.html/> IASC aloe vera online service.
 - 3 Woo SW, Nan JX, Lee SH, Park EJ, Zhao YZ, Sohn DH. Aloe emodin suppresses myofibroblastic differentiation of rat hepatic stellate cells in primary culture. *Pharmacol Toxicol* 2002 Apr; **90**: 193-198
 - 4 Chandan BK, Saxena AK, Shukla S, Sharma N, Gupta DK, Suri KA, Suri J, Bhadauria M, Singh B. Hepatoprotective potential of *Aloe barbadensis* Mill. against carbon tetrachloride-induced hepatotoxicity. *J Ethnopharmacol* 2007; **111**: 560-566
 - 5 Saka WA, Akhigbe RE, Ishola OS, Ashamu EA, Olayeml OT, Adeleke GE. Hepatotherapeutic effect of *Aloe vera* in alcohol-induced hepatic damage. *Pakistan J Biological Sciences*, 2011; **14**: 742-746
 - 6 Lim BO, Seong NS, Choue RW, Kim JD, Lee HY, Kim SY, Yu BP, Jeon TL, Park DK. Efficacy of dietary aloe supplementation on hepatic cholesterol and oxidative status in aged rats. *J Nutr Sci Vitaminol (Tokyo)* 2003, **49**: 292-296
 - 7 Yagi A, Sato Y, Shimomura K, Akasaki H, Tsuji H. Distribution of verectin in *Aloe vera* leaves and verectin contents in clonally regenerated plants and the commercial gel powders by immunochemical screening. *Planta Med* 2000; **66**: 180-182
 - 8 Hegazy SK, El-Bedewy M, Yagi A. Antifibrotic effect of *Aloe vera* in viral infected-induced hepatic periportal fibrosis. *World J Gastroenterology* 2012; **18**: 2026-2034
 - 9 Im SA, Lee YR, Lee YH, Lee MK, Park YI, Lee S, Kim K, Lee CK. *In vivo* evidence of the immunomodulatory activity of orally administered *Aloe vera* gel. *Arch Pharm Res* 2010; **33**: 451-456
 - 10 Yagi A, Hegazy SK, Kabbash A, Wahab EAE. Possible hypoglycemic effect of *Aloe vera* L. high molecular weight fractions on type 2 diabetic patients. *Saudi Pharmaceutical Journal* 2009; **17**: 129-136
 - 11 Matsuo K, Yagi A, Kabbash A. Case reports of bed sores using *Aloe vera* gel powder with high molecular weight. *Pharmacognosy Research* 2009; **1**: 16-42
 - 12 Sugerman PB, Savage NW. Oral lichen planus: Cause, diagnosis and management. *Australian Dental Journal* 2002; **47**: 290-297
 - 13 Yagi A, Kabbash A, Mizuno K, Moustafa SM, Kaharifa TI, Tsuji H. Radical scavenging glycoprotein inhibiting cyclooxygenase-2 and thromboxane A2 synthase from *Aloe vera* gel. *Planta Med* 2003; **69**: 269-271
 - 14 El-Soudany K, Yagi A, and Kabbash A. A self-controlled single blinded clinical trial to evaluate oral lichen planus after topical treatment with *Aloe vera*. *Journal of Gastroenterology and Hepatology Research* 2013; **2**: 503-507
 - 15 Maenthaisong R, Chaiyakunapruk N, Niruntraporn S, Kongkaew C. The efficacy of aloe vera used for burn wound healing: A systemic review. *Burns* 2007; **33**: 713-718
 - 16 Tizard IR, Busbee D, Maxell B, Kemp MC. Effect of acemannan, a complex carbohydrate, on wound healing in young and old rats. *Wound* 1994; **6**: 201-209
 - 17 Ramamoorthy L, Tizard IR. Induction of apoptosis in a macrophage cell line RAW 264.7 by acemannan, a β -(1,4)-acetylated mannan. *Molecular Pharmacology* 1998; **53**: 415-421
 - 18 Lee JK, Lee MK, Yun YP, Kim Y, Kim JS, Kim YS, Kim K, Han SS, Lee CK. Acemannan purified from *Aloe vera* induces phenotypic and functional maturation of immature dendritic cells. *Int Immunopharmacol* 2001; **1**: 1275-1284
 - 19 El-Shemy HA, Aboul-Soud MAM, Nassr-Allah AA, Aboul-Enein KM, Kabbash A, Yagi A. Anti-tumor properties modulation of auto-oxidation enzymes' activity by *Aloe vera* leaf active principles isolated via supercritical carbon dioxide extraction. *Current Medicinal Chemistry* 2010; **17**: 129-138
 - 20 Choi SW, Son BW, Son YS, Park YI, Lee SK, Chung MH. The wound-healing effect of a glycoprotein fraction isolated from *Aloe vera*. *Br J Dermatol* 2001; **145**: 535-545
 - 21 Yun JM, Singh S, Jialal R, Rockwood J, Jialal I, Devaraj S. A randomized placebo-controlled crossover trial of *Aloe vera* on bioavailability of vitamin C and B12, blood glucose, and lipid profile in healthy human subjects. *J Diet Suppl* 2010; **7**: 145-153
 - 22 Lebitsa T, Viljoen A, Lu Z, Hamman J. *In vitro* drug permeation enhancement potential of aloe gel materials. *Curr Drug Deliv* 2012; **9**: 297-304
 - 23 Beneke C, Viljoen A, Hamman J. *In vitro* drug absorption enhancement effects of *Aloe vera* leaf and *Aloe ferox*. *Scientia Pharmaceutica* 2012; **80**: 475-486
 - 24 Chandrashekara KT, Shakarad MN. *Aloe vera* or resveratrol supplementation in larval diet delays adult aging in the fruit fly, *Drosophila melanogaster*. *J Gerontol A Bio Sci Med Sci* 2011; **66A**: 965-971
 - 25 Ikeno Y, Hubbard GB, Lee S, Yu BP, Herlihy JT. The influence of long-term *Aloe vera* ingestion on age-related disease in male Fischer 344 rats. *Phytother Res* 2002; **16**: 712-718
- Peer reviewer:** Saad A Noeman, Professor of Immunology and Molecular biology, Department of Medical Biochemistry, Faculty of Medicine, Tanta University, Elgesh street, Tanta post code: 31512, Egypt.