

Chronic Hepatitis C is Associated with Adrenal Tumors

Montish Singla, Alexander Sy, Donald Baumstein, Khatuna Kadeishvili, Hussein M Matari, Nora V Bergasa

Montish Singla, Alexander Sy, Donald Baumstein, Khatuna Kadeishvili, Nora V Bergasa, Department of Medicine, Metropolitan Hospital Center, NY and New York Medical College, New York, NY 10029, the United States

Hussein M Matari, Department of Radiology, Metropolitan Hospital Center, NY and New York Medical College, New York, NY 10029, the United States

Correspondence to: Montish Singla, Department of Medicine—Room 706, Metropolitan Hospital, New York Medical College, 1901 First Avenue, New York, NY 10029, the United States. montishsingla@gmail.com

Telephone:+1-212-423-6771 Fax:+1-212-423-8099

Received: March 14, 2013 Revised: April 24, 2013

Accepted: April 26, 2013

Published online: July 21, 2013

functional adrenal tumors, which require diagnostic evaluation and treatment.

© 2013 ACT. All rights reserved.

Key words: Insulin growth factor; Insulin; Primary hyperaldosteronism; Tumorigenesis; Extrahepatic manifestations

Singla M, Sy A, Baumstein D, Kadeishvili K, Matari HM, Bergasa NV. Chronic Hepatitis C is Associated with Adrenal Tumors. *Journal of Gastroenterology and Hepatology Research* 2013; 2(7): 680-682 Available from: URL: <http://www.ghrnet.org/index.php/joghr/article/view/431>

ABSTRACT

AIM: Increased serum levels of insulin growth factor (IGF) and insulin have been reported in patients with chronic hepatitis C. Insulin and IGF-1 have also been associated with increased growth of adrenal cells in culture. These observations suggest that both IGF and insulin can trigger adrenal tumorigenesis. Adrenal tumors have been reported in a series of patients with chronic hepatitis C; accordingly, the aim of this study was to explore further this potential association.

METHODS: Patients with a diagnosis of adrenal tumors over the past ten years were identified and their records reviewed for evidence of chronic hepatitis C. The control group was comprised of age-matched subjects who had had a CT or MRI of the abdomen during the same study period, and had documentation of hepatitis C status.

RESULTS: Twenty three patients with adrenal tumors were identified. Fifteen of these patients (65.2%) had hepatitis C antibody in serum; eleven (47.8%) of these had hepatitis C RNA, confirming chronic hepatitis C (CHC). In the control group, in contrast, only one of twenty-three patients (4.3%) had hepatitis C antibody in serum, which was significantly lower than in the study group (p value<0.0005).

CONCLUSION: There is an association between chronic hepatitis C and adrenal tumors. Adrenal tumors may be one of the extrahepatic manifestations of this viral infection. The recognition of this association by clinicians will dramatically change the approach to patients with chronic hepatitis C and manifestations, even subtle, of

INTRODUCTION

Infection with the hepatitis C virus is one of the most common causes of chronic liver disease worldwide^[1]. In addition to liver disease, chronic hepatitis C can be associated with extrahepatic manifestations including mixed cryoglobulinemia, glomerulonephritis, porphyria cutanea tarda, lichen planus, Sjogren's syndrome, cardiomyopathy and, as recently reported, adrenal tumors^[2].

Chronic hepatitis C can be associated with insulin resistance, which leads to hyperinsulinemia, and with increased serum levels of insulin growth factor (IGF)^[3-5]; both substances have been reported to increase adrenal fasciculate cell growth *in vitro*^[6]. Thus, the hepatitis C virus may trigger adrenal tumorigenesis, which, in some cases, may lead to hyperaldosteronism. Accordingly, in this study we further explored the association between adrenal tumors and chronic hepatitis C.

METHODS

This study was approved by the Institutional Review Board. It was conducted in a community hospital in East Harlem, New York serving primarily African American individuals and those of Hispanic heritage. The medical records of subjects with the diagnosis of adrenal tumors in the problem list from 2001-2010 were identified. This period of time was chosen because electronic medical records became available in the institution in 2001. The computerized tomography (CT) or magnetic resonance imaging (MRI) scans of the abdomen were examined with a radiologist

to confirm the presence of adrenal tumors. The medical records of patients matched for age and who had had CTs or MRIs of the abdomen and serological testing for hepatitis C performed during the same period of time, were identified; they comprised the control group. The records of the subjects in both groups were reviewed for evidence of chronic hepatitis C. The proportion of patients with chronic hepatitis C was compared between the study group and the control group and the statistical significance of the difference, defined as p values less than 0.05, was calculated.

Statistical analysis: SPSS software version 19.0.0 (SPSS, Chicago, Illinois), was used for the statistical analysis. Chi square test was applied to analyze the difference in proportions. Descriptive statistics were used to describe the study group.

RESULTS

Twenty-three patients with adrenal tumors were identified. Fifteen (65.2%) of these patients had hepatitis C antibody in serum (Figure 1). Eleven (47.8%) of these patients had hepatitis C RNA, consistent with chronic hepatitis C virus infection (Figure 1); there was no documentation of hepatitis C RNA in the other four patients. In the control group, only one of twenty-three (4.3%) patients had hepatitis C antibody in the serum and it was negative in the other twenty-two (95.7%); no information on hepatitis C RNA was available in this group. The proportion of patients with chronic hepatitis C antibody in serum in the study group was significantly higher than that of the control group (p value <0.0005).

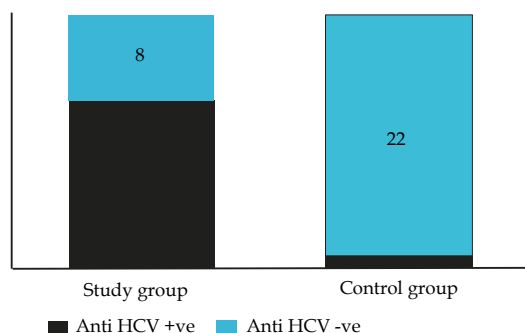


Figure 1 Anti HCV antibody positivity in the study group compared to control group.

The mean age of the group of fifteen patients (study group) was 60 years (range 44-81), ten (66.7%) were women and five (33.3%) were men. Seven (46.7%) patients were African American and the rest (53.3%), was of Hispanic heritage. Ten patients (66.7%) had hypertension and five (33.3%) had type II diabetes mellitus. One patient was co-infected with the hepatitis B virus and three with the human immunodeficiency virus.

The risk factor for viral hepatitis was intravenous drug use in four patients (26.7%), blood transfusions in eight (53.3%), and not documented in the other three (20%). There was documentation of hypokalemia in four patients, and high serum aldosterone levels along with low plasma renin activity, consistent with hyperaldosteronism, in another patient. The aldosterone to renin ratio in this patient was 1081 ng/dL per ng/(mL.hour). Eleven patients did not have any documented work up for the functionality of the adrenal tumors.

In the control group ($n=23$), the mean age of patients was 55 years (range 39-77), fifteen were women (65.2%) and eight were men (34.8%). Fourteen (60.9%) patients were of Hispanic heritage, seven (30.4%) were African American, and in two (8.7%) ethnicity or race were not documented. Nine (39.1%) had hypertension and eleven

(47.8%) had type II diabetes mellitus.

DISCUSSION

In this study, we found that 65.2% of the patients with adrenal tumors had evidence of hepatitis C virus infection, as evidenced by the presence of the antibody in serum; eleven of these (47.8%) had hepatitis C viral RNA, confirming the diagnosis of chronic hepatitis C. The diagnosis of chronic hepatitis C in the study group was probably higher than what can be inferred from the data, as at least 80% of patients with acute hepatitis C virus infection go on to develop chronic disease, hence most patients with hepatitis C antibody in serum have chronic hepatitis C^[1]. In contrast, in the control group, the proportion of patients with serum hepatitis C antibody was only 4.3%. These findings tend to support the idea that there is an association between adrenal tumors and chronic hepatitis C, and that adrenal tumors may be one of its extrahepatic manifestations, as previously suggested^[2].

Although this is a retrospective study with a limited sample size, it involved extensive review of ten years of clinical information at a busy community hospital lending credence to the findings.

The hepatitis C virus has tropism for glandular tissue, as evidenced by its ability to cause hepatitis; thus, it is possible that it might also have affinity for other glandular tissues like that of adrenal glands, and that ultimately might have a potential role in the formation of adrenal tumors. At present, there is no unequivocal information to support that the hepatitis C virus replicates in the adrenal glands^[7,8]; however, alternate pathways may support the development of adrenal tumors in chronic hepatitis C virus infection.

The mechanism of adrenal tumorigenesis is still not known completely^[9]. In this regard, the immunoreactivities of IGF-I, insulin, and their respective receptors have been reported to be increased in adrenal adenoma cells^[9]. In addition, insulin and insulin receptor immunoreactivities were also reported in the majority of tumors^[10]. These results may suggest that IGF and insulin mediate, to some degree, adrenal tumorigenesis. This idea may be relevant to the association of hepatitis C and adrenal tumors because it has also been reported that serum levels of IGF are increased in patients with chronic viral hepatitis, including that secondary to hepatitis C virus infection. Furthermore, chronic hepatitis C is associated with insulin resistance, leading to an increase in the secretion of insulin^[3-5]. Both insulin and IGF-I are growth factors that have been associated with increased cell growth in a culture system of adrenal fasciculate cells^[10]. These observations may suggest that IGF-I, IGF-II and perhaps insulin, trigger adrenal tumorigenesis.

Recently, somatic gene mutations have been reported to have a role in aldosterone producing adenomas^[11]. It would be of interest to explore if there is a genetic predisposition to the development of this type of neoplasia in patients with chronic hepatitis C.

The mainstay of the management of extrahepatic manifestations in chronic hepatitis C patients is antiviral therapy^[12]. Similarly, it would be important to determine the effects of antiviral therapy on adrenal tumors in patients with chronic hepatitis C virus.

In this study, it was found that approximately half of the patients with adrenal tumors had no documented work up for hyperaldosteronism. In this context, a question arises, why hasn't this association been reported before 2010^[2]? The answer, as pointed out in a recent communication^[13], may be "in part due to cost, and in larger part to clinical ignorance and indifference"^[13]. Accordingly, the novel findings from this study should have an impact on the approach to patients with chronic hepatitis C, which must include attention to subtle signs of hyperaldosteronism like early onset and/or difficult to treat hypertension, and hypokalemia, which would warrant investigations for hyperaldosteronism and adrenal

tumors. In patients with adrenal tumors, screening for hepatitis C virus infection may be a reasonable strategy.

REFERENCES

- 1 Williams R. Global challenges in liver disease. *Hepatology* 2006; **44**: 521-526.
- 2 Bergasa NV, Holguin GE, Martinez M, Chen YL, Baumstein D. Adrenal tumors in patients with chronic hepatitis C. *Gastroenterol Hepatol* 2010; **6**: 385
- 3 Conjeevaram HS, Kleiner DE, Everhart JE, Hoofnagle JH, Zacks S, Afdhal NH, Wahed AS; Virahep-C Study Group. Race, insulin resistance and hepatic steatosis in chronic hepatitis C. *Hepatology* 2007; **45**: 80-87
- 4 Harrison SA. Insulin resistance among patients with chronic hepatitis C: etiology and impact on treatment. *Clin Gastroenterol and Hepatol* 2008; **6**: 864-876
- 5 Maeno T, Okumura A, Ishikawa T, Kato K, Sakakibara F, Sato K, Ayada M, Hotta N, Tagaya T, Fukuzawa Y, Kakumu S. Mechanisms of increased insulin resistance in non-cirrhotic patients with chronic hepatitis C virus infection. *J Gastroenterol Hepatol* 2003; **18**: 1358-1363
- 6 Penhoat A, Chatelain PG, Jaillard C, Saez JM. Characterization of insulin like growth factor I and insulin receptors on cultured bovine adrenal fasciculata cells. Role of these peptides on adrenal cell function. *Endocrinology* 1988; **122**: 2518-2526
- 7 Sugitani M, Shimizu YK, Azumi J, Maeda T, Abe K, Shikata T. Organ specificity of the antigens reacting with the 48-1 and S-1 antibodies in chimpanzees infected with hepatitis C virus. *Int J Exp Pathol* 1991; **72**: 481-488
- 8 Yan FM, Chen AS, Hao F, Zhao XP, Gu CH, Zhao LB, Yang DL, Hao LJ. Hepatitis C virus may infect extrahepatic tissues in patients with hepatitis C. *World J Gastroenterol* 2000; **6**: 805-811
- 9 Kamio T, Shigematsu K, Kawai K, Tsuchiyama H. Immunoreactivity and receptor expression of insulin like growth factor I and insulin in human adrenal tumors. An immunohistochemical study of 94 cases. *Am J Pathol* 1991; **138**: 83-89
- 10 Kloos RT, Gross MD, Francis IR, Korobkin M, Shapiro B. Incidentally discovered adrenal masses. *Endocr Rev* 1995; **16**: 460-484
- 11 Choi M, Scholl UI, Yue P, Björklund P, Zhao B, Nelson-Williams C, Ji W, Cho Y, Patel A, Men CJ, Lolis E, Wisgerhof MV, Geller DS, Mane S, Hellman P, Westin G, Åkerström G, Wang W, Carling T, Lifton RP. K⁺ channel mutations in adrenal aldosterone-producing adenomas and hereditary hypertension. *Science* 2011; **331**: 768-772.
- 12 Zignego AL, Ferri C, Pileri SA, Caini P, Bianchi FB. Extrahepatic manifestations of Hepatitis C Virus infection: a general overview and guidelines for a clinical approach. *Dig Liver* 2006; **39**: 2-17
- 13 Funder JW. The genetics of primary aldosteronism. *Science* 2011; **331**: 685-686

Peer reviewer: Hamdy Sliem, professor of internal medicine, faculty of medicine, Suez canal university, Ismailia, Egypt.