

## Possible Prophylactic Efficacy of Aloe Vera for $\gamma$ -Ray Radiation-Induced Damages

Akira Yagi

Akira Yagi, Emeritus Professor. Fukuyama University, Placenta-Aloe Research Institute, Fukuoka Bio Factory 204, Japan Bio Products Co., Ltd. 1488-4 Aikawa-machi, Kurume-shi, Fukuoka 839-0861, Japan

Correspondence to: Akira Yagi, Emeritus Professor. Fukuyama University, Placenta-Aloe Research Institute, Fukuoka Bio Factory 204, Japan Bio Products Co., Ltd. 1488-4 Aikawa-machi, Kurume-shi, Fukuoka 839-0861, Japan. [akirayagi@nexyzbb.ne.jp](mailto:akirayagi@nexyzbb.ne.jp)

Telephone: +942-34-2216

Fax: +942-34-2333

Received: May 6, 2013

Revised: June 26, 2013

Accepted: April 28, 2013

Published online: September 21, 2013

### ABSTRACT

*Aloe vera* gel has been widely used for healing of burn wound and radiation-induced photo-skin damages under the duration of grade <2 mucositis, and positive or negative response to in vivo  $\gamma$ -ray radiation-induced tissue alterations and a possible prophylactic efficacy of *aloe vera* were comparatively evaluated in the review. Since *aloe vera* wound dressing gel reduced  $\gamma$ -ray radiation-induced skin reactions in C3H mice by daily application for at least 2-weeks beginning immediately after radiation, a possible participation of aloe polysaccharides in *aloe vera* gel was demonstrated for  $\gamma$ -ray radiation-induced skin damages. *In vitro* and *in vivo* insulin permeation enhancements by *aloe vera* gel were clearly revealed from the viewpoint of drug delivery system, and the treatment of insulin resistant mice with the polyphenol-rich *aloe vera* extract diminished their insulin resistance. Modified *aloe vera* polysaccharides with aloe phenolic chromones, aloesin groups, decreased in insulin level observed in subjects in condition of pre-diabetic/metabolic syndrome. Therefore, the possible prophylactic efficacy of *aloe vera* extract for  $\gamma$ -ray radiation-induced skin damages may be resulted from synergistic effects taking place between phenolic ingredients; chromones and aloe polysaccharides as adjuvants. The pro-inflammation studies on insulin response, resistance and/or sensitivity of aloe phenolic ingredient(s) and polysaccharides are needed to confirm possible prophylactic benefits of *aloe vera* gel for photo/ $\gamma$ -ray radiation-induced skin damages, wound healing-and regeneration, and the prevention of age-related pathology.

**Key words:** Possible prophylactic efficacy; *Aloe vera* phenolics; Aloe polysaccharides; Insulin sensitivity;  $\gamma$ -ray radiation-induced damages

Yagi A. Possible Prophylactic Efficacy of *Aloe Vera* for  $\gamma$ -Ray Radiation-Induced Damages. Journal of Gastroenterology and Hepatology Research 2013; 2(9): 757-764 Available from: URL: <http://www.ghrnet.org/index.php/joghr/article/view/478>

### INTRODUCTION

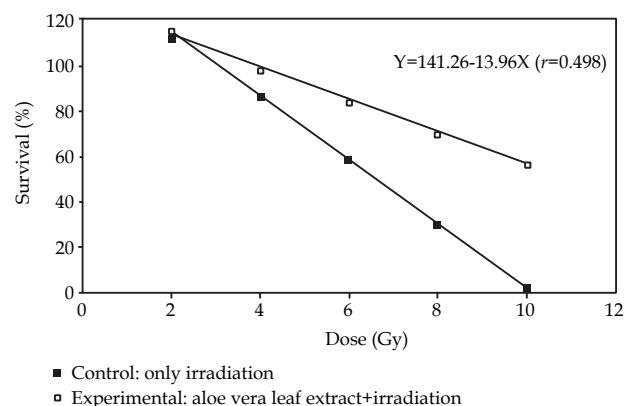
First case report of roentogen dermatitis treated with fresh *aloe vera* gel was demonstrated by Collins on 1935. A white woman, aged thirty-one, suffering with a severe roentogen dermatitis from a depilatory roentogen radiation, was treated with a quantity of *aloe vera* gel for local application. She was instructed to continue the use of the gel, and progressively was improved and completely regenerated the skin and new hair growth after 5 weeks<sup>[1]</sup>.

In 1953, Lushbaugh and co-workers at Los Alamos Science Laboratory, found that fresh *aloe vera* gel was very effective in healing  $\beta$ -radiation-induced skin burns on rabbits exposed to radiation Strontium, and cut healing times to less than half<sup>[2]</sup>. This government discovery has led to topical application of *aloe vera* gel for radiation-induced skin damages.

Recently,  $\gamma$ -ray radiation therapy becomes a popular treatment for cancer patients. One of the common side effects of  $\gamma$ -ray radiation therapy is acute skin damage (radiation dermatitis) ranging from a mild rash stage to severe ulceration. Eighty-five percent of patients treated with  $\gamma$ -ray radiation therapy for dermal cancer are likely suffered from moderate to severe skin reaction. Acute  $\gamma$ -ray radiation-induced skin reaction leads to itching and pain, and subsequently to decrease in quality of life. There are several reports showing positive or negative effects of *aloe vera* for in vivo  $\gamma$ -ray radiation-induced tissue alterations. This discrepancy may be due to the synergistic effect or different bioassay by the crude mixture with individual phytochemical profiles and ratio between various components; such as anti-oxidants/pro-oxidants, polysaccharides, glycoprotein and/or proteins. This review discusses various therapeutic properties for radiation-induced damages and future potential of *aloe vera*.

The present review is composed of positive/negative effect of *Aloe vera* for in vitro/vivo  $\gamma$ -ray radiation-induced tissue alterations, possible prophylactic efficacy of aloe polysaccharide for  $\gamma$ -ray

radiation-induced damages under subsections organized by the nature of protection modes, and *aloe vera* phenolic inhibitors for insulin receptor. Please find figure 1, tables 1-3 and tables 4-5 showing in the reference number 5, 9, and 18, respectively, therein, on Internet.



**Figure 1** Survival dose-response curves for determination of LD<sub>50/30</sub> (Survival data collected for four rediation doses and calculated by regression analysis).

## POSITIVE EFFECT FOR $\gamma$ -RAY RADIATION-PROTECTION OF ALOE VERA

### Oral administration of *Aloe vera*

(1) Evaluation of radioprotective efficacy of *aloe vera* gel by oral administration and possible mechanism of action of *aloe vera* gel.

Three different doses of *aloe vera* gel (250, 500 and 750 mg/kg body weight) were tested against 8 Gy induced damage in Swiss albino mice. A dose of 750 mg/kg body weight was the most effective while, 250 mg/kg body weight was the least effective in providing protection, as observed in the form of higher concentrations of blood glutathione and vitamin C and lower level of serum lipid peroxide than irradiated animals at 1 h post irradiation and higher percent of survivors up to day 30 post irradiation. Treatment of mice with *aloe vera* before irradiation with different doses of  $\gamma$ -ray radiation (6-12 Gy) delayed the onset and reduced the severity of signs of radiation sickness. The LD<sub>50/30</sub> was calculated as 6.77 and 10 Gy for untreated irradiated and *aloe vera* treated irradiated animals, respectively and its dose reduction factor was also calculated as 1.47 (10/6.77). *Aloe vera* gel scavenged the free radicals; (a) 1,1-diphenyl-2-picrylhydrazyl; (b) 2,2-azinobis-3-ethylbenzothiazoline-6-sulfonate<sup>+</sup>, and nitric oxide in a concentration dependent manner in vitro and therefore, scavenging

**Table 1** Variation in the body weight (g) tissue weight (mg) , tubular diameter (um) of adult male Swiss albino mice after the Aloe vera (A), radiation (R) and Aloe vera + radiation treatment (A+R).

Experimental group	Parameter	Autopsy interval (days)				
		1	3	7	14	30
A50	Body weight	20.60±0.45	21.10±0.34	20.80±1.30	21.9±0.34	23.5±0.42
	Testis weight	88.30±2.49 <sup>2</sup>	85.8±2.44	85.1±1.33	109.7±4.14 <sup>4</sup>	104.7±1.66 <sup>4</sup>
	Tubular diameter	178.74±4.79 <sup>2</sup>	186.39±2.91 <sup>3</sup>	181.39±5.05 <sup>2</sup>	199.67±4.98 <sup>4</sup>	174.67±2.65
A100	Body weight	21.50±0.63	19.80±1.16	21.90±0.60	21.40±0.86	21.5±0.47
	Testis weight	92.6±2.57 <sup>3</sup>	86.9±1.76	85.1±0.82	86.3±1.30	88.5±2.16
	Tubular diameter	185.96±3.48 <sup>3</sup>	206.72±6.22 <sup>4</sup>	172.87±7.33	183.35±3.83 <sup>3</sup>	186.83±2.66 <sup>3</sup>
R(8Gy)	Body weight	19.55±0.88	18.95±0.77	18.20±0.85	17.7±0.83	15.7±0.82
	Testis weight	74.40±2.53	74.4±2.13	59.80±2.66 <sup>3</sup>	46.6±2.59 <sup>4</sup>	25.9±1.07
	Tubular diameter	145.72±1.35	131.06±3.28	127.56±2.49	126.31±1.91	126.15±2.31
A50+R	Body weight	20.50±0.42	17.90±1.71	20.60±2.38	20.30±0.53	23.8±0.97 <sup>4</sup>
	Testis weight	75.6±1.10	8.71±2.74 <sup>2</sup>	72.4±2.80 <sup>3</sup>	49.0±1.86	30.9±2.12
	Tubular diameter	185.74±2.56 <sup>4</sup>	166.61±5.38 <sup>4</sup>	158.79±4.32 <sup>3</sup>	151.98±5.38	182.37±3.79 <sup>4</sup>
A100+R	Body weight	21.30±0.53	19.80±0.46	22.00±0.83 <sup>3</sup>	18.80±0.66	26.90±0.54 <sup>3</sup>
	Testis weight	91.11±2.85 <sup>3</sup>	78.0±1.57	67.40±1.58 <sup>2</sup>	56.9±1.58 <sup>3</sup>	39.5±0.94 <sup>3</sup>
	Tubular diameter	155.34±2.42	141.19±1.49	138.69±2.76	152.90±2.62 <sup>2</sup>	150.29±1.89 <sup>3</sup>
Normal <sup>1</sup>	Animal weight	21.20±0.488				
	Testis weight	76.5±1.021				
	Tubular diameter	157.4±2.90				

<sup>1</sup> Average animal weight, tissue weight and tubular diameter measured on each autopsy interval. <sup>4</sup>  $p < 0.001$ , <sup>3</sup>  $p < 0.01$ , <sup>2</sup>  $p < 0.05$ .

**Table 2** Variation in different cell counts of seminiferous tubule of the testes of adult male Swiss albino mice at various autopsy intervals in only Aloe vera (A) treated groups.

Experimental group	Cell types	Autopsy interval (days)				
		1	3	7	14	30
A50	Spermatogonia type A	6.00±0.59	3.60±0.58	1.60±0.40	2.90±0.37	8.80±0.32
	Spermatogonia type B	6.60±0.63	4.40±0.54	3.70±0.37	3.40±0.52	6.20±0.77
	Primary spermatocytes	27.20±1.57	39.00±1.10 <sup>2</sup>	34.80±0.72	37.70±1.13	47.70±1.26 <sup>3</sup>
	Secondary spermatocytes	20.30±1.53	25.70±1.65	20.90±1.25	22.80±1.22	28.30±1.92
	Spermatids	48.20±1.58 <sup>4</sup>	27.50±0.95	21.90±1.43	19.10±0.73	27.20±2.26
A100	Spermatogonia type A	2.77±0.49	4.11±0.40	2.55±0.55	0.40±0.22	5.66±0.44
	Spermatogonia type B	7.88±0.73	6.11±0.67	5.54±0.68	2.22±0.54	3.11±0.48
	Primary spermatocytes	36.50±2.53	46.44±1.73 <sup>3</sup>	42.66±0.86 <sup>3</sup>	38.00±0.86 <sup>3</sup>	45.77±1.30 <sup>3</sup>
	Secondary spermatocytes	21.33±1.28	23.44±2.24	28.55±1.87	19.44±1.38	17.66±0.83
	Spermatids	38.11±2.02 <sup>3</sup>	36.55±1.84	36.88±2.64 <sup>2</sup>	20.55±1.06	37.72±0.97
Normal <sup>1</sup>	Spermatogonia type A	10.60±0.30				
	Spermatogonia type B	13.10±0.79				
	Primary spermatocytes	31.50±1.87				
	Secondary spermatocytes	47.40±2.12				
	Spermatids	30.00±0.71				

<sup>1</sup> Average number of cells counted on each autopsy interval. <sup>4</sup>  $p < 0.001$ , <sup>3</sup>  $p < 0.01$ , <sup>2</sup>  $p < 0.05$ .

**Table 3** Variation in different cell counts of seminiferous tubule of the testes, of adult male Swiss albino mice at various autopsy intervals in irradiated group (R) and Aloe vera+radiation treatment (A+R).

Experimental group	Type of cell	Autopsy interval (days)				
		1	3	7	14	30
R(8Gy)	Spermatogonia type A	2.77±0.49	6.00±0.59	0.44±0.22	4.00±0.22	6.88±0.81
	Spermatogonia type B	3.00±0.33	5.66±0.63	4.77±0.44	5.33±0.83	13.33±1.27
	Primary spermatocytes	22.55±0.93	35.44±2.13	17.77±2.13	7.00±0.63	18.55±1.63
	Secondary spermatocytes	12.66±1.11	19.66±1.09	29.33±5.00	13.22±1.68	20.66±1.20
	Spermatids	45.12±1.22	33.44±2.76	26.44±2.88	25.55±2.51	0.00±0.00
A+R(8Gy)	Spermatogonia type A	2.60±0.30	3.20±0.41	2.20±0.41 <sup>3</sup>	4.10±0.48	2.20±0.35
	Spermatogonia type B	4.00±0.33	2.80±0.41	2.80±0.41	1.90±0.37	1.60±0.47
	Primary spermatocytes	28.20±1.35 <sup>4</sup>	26.60±0.95	11.60±0.95	7.30±0.59	17.60±0.56
	Secondary spermatocytes	17.40±0.70 <sup>2</sup>	17.20±1.36	17.20±1.31	17.20±1.63	22.00±0.68
	Spermatids	33.20±1.19	40.50±1.41 <sup>3</sup>	24.50±1.49	13.60±0.88	26.00±0.47 <sup>4</sup>
A100+R(8 Gy)	Spermatogonia type A	6.70±0.47 <sup>3</sup>	5.22±0.30	3.60±0.04 <sup>4</sup>	13.50±0.80 <sup>4</sup>	13.30±0.63 <sup>4</sup>
	Spermatogonia type B	10.30±0.59 <sup>3</sup>	15.11±1.56 <sup>4</sup>	6.20±0.41 <sup>2</sup>	4.50±0.72	5.90±0.98
	Primary spermatocytes	42.60±0.88 <sup>4</sup>	50.66±0.86 <sup>3</sup>	48.77±0.90 <sup>4</sup>	39.00±1.07 <sup>4</sup>	45.00±1.31 <sup>4</sup>
	Secondary spermatocytes	21.44±0.96 <sup>4</sup>	36.66±0.72 <sup>3</sup>	13.22±1.34	26.11±2.16 <sup>4</sup>	27.40±1.02 <sup>3</sup>
	Spermatids	55.66±0.96 <sup>3</sup>	52.40±1.56 <sup>4</sup>	56.00±1.37 <sup>4</sup>	34.90±1.51 <sup>3</sup>	42.80±2.67 <sup>4</sup>
Normal <sup>1</sup>	Spermatogonia type A	10.60±0.30				
	Spermatogonia type B	13.10±0.79				
	Primary spermatocytes	31.50±1.87				
	Secondary spermatocytes	47.40±2.12				
	Spermatids	30.00±0.71				

<sup>1</sup> Average animal weight, tissue weight and tubular diameter measured on each autopsy interval. <sup>4</sup> $p<0.001$ , <sup>3</sup> $p<0.01$ , <sup>2</sup> $p<0.05$ .

**Table 4** The effect of aloe polysaccharides (AP) on the mouse survival 30-day postirradiation<sup>a</sup>.

Group	Drug dosage (mg/kg BW)	Survival (%)
Control	-	100
Irradiation only	-	10
AP treated+Irradiation	12.5	30.0*
AP treated+Irradiation	25	60.0*
AP treated+Irradiation	50	86.0**
AP treated+Irradiation	100	72.**

<sup>a</sup> Forty mice were used in each group, and the dose of  $\gamma$ -ray irradiation was 7.5 Gy. The data presented are averages derived from independent triplicate experiment. One asterisk and two asterisks indicate  $P<0.01$  and  $P<0.001$ , respectively, as compared with the control group ( $\chi$ -square test).

**Table 5** Pretreated time required for radioprotective effect of aloe polysaccharides<sup>a</sup>.

Group	Drug dosage (mg/kg BW)	Drug exposure time (min)	Survival (%)
Control	-		100
Irradiation only	-		16.6
AP treated+Irradiation	25	30 min before irradiation	65.0**
AP treated+Irradiation	25	60 min before irradiation	50.0*
AP treated+Irradiation	25	90 min before irradiation	60.0**
AP treated+Irradiation	50	30 min before irradiation	87.5**
AP treated+Irradiation	50	60 min before irradiation	80.0**
AP treated+Irradiation	50	90 min before irradiation	82.3**

<sup>a</sup> Forty mice were used in each group, and the dose of  $\gamma$ -ray irradiation was 7.5 Gy. The data presented are averages derived from an independent triplicate experiment. One asterisk and two asterisks indicate  $P<0.01$  and  $P<0.001$ , respectively, as compared with the control group ( $\chi$ -square test).

of free radicals seems to be its important mechanism of action<sup>[3]</sup>.

(2) *Aloe vera* oral administration accelerates acute radiation-delayed wound healing by stimulating transforming growth factor  $\beta$ -1 and fibroblast growth factor production.

The effect of oral administration of *aloe vera* was studied in radiation-exposed rats compared with radiation-only and control rats as follows: Thirty-six male Wistar rats were assigned randomly to 3 groups ( $n=12$ , each); CG (Sham-radiation), radiation-only group (RG), and radiation plus *aloe vera* treatment group (RAG). A single dose of 9 Gy soft x-ray radiation to the selected area on each rat. Skin wounds were excised on the back of rats after 3 days of local radiation. Wound size was measured on days 0, 3, 6, 9, and 12 after wounding.

Wound tissues were examined histologically and the expressions of transforming growth factor  $\beta$ -1 (TGF  $\beta$ -1) and basic fibroblast growth factor (bFGF) were examined by immunohistochemistry and reverse-transcription polymerase chain reaction.

Wound contraction was accelerated significantly by *aloe vera* on days 6 and 12 after wounding.

Furthermore, the inflammatory cell infiltration, fibroblast proliferation, collagen deposition, angiogenesis, and the expression levels of TGF  $\beta$ -1 and bFGF were significantly higher in the radiation plus *aloe vera* group compared with the radiation-only group. It was concluded that *aloe vera* oral administration shows wound healing enhancement in early phase after single-dose acute radiation exposure. The improved wound healing activity might be attributed to its stimulating effect on increasing inflammatory cell infiltration, fibroblast proliferation and TGF-  $\beta$ -1 and bFGF production<sup>[4]</sup>.

(3) Radioprotective effects of *aloe vera* leaf extract against whole-body  $\gamma$ -ray irradiation and radiation-induced hepatic damage of Swiss albino mice.

Radiation-induced biochemical alterations caused by whole-body  $\gamma$ -ray irradiation and their modulation in Swiss albino mice were explored.

Swiss albino mice were divided into four different groups: I (double-distilled water-treated group); II (*aloe vera*-treated group): *aloe vera* leaf extract was orally administered 1g/kg body weight/day for 15 consecutive days; III (radiation-treated group): the animals were exposed to 6 Gy radiation at the dose rate of 0.96 Gy/min. This group served as the positive control. IV (combination group): animals were orally administered *aloe vera* leaf extract continuously for 15 consecutive days, and on the 15<sup>th</sup> day they were irradiated to 6 Gy  $\gamma$ -ray radiation after 30 minutes of extract administration. The animals from the above groups were autopsied after 6 h, 24 h and at 3, 7, 21 days of radiation. Biochemical estimations of DNA, lipid peroxidation (LPO), glutathione (GSH), catalase, and superoxide dismutase (SOD) were made. Total DNA, catalase, SOD activity in the skin, and GSH in the liver and blood increased in the irradiated control group. In contrast, in experimental animals, DNA, catalase, and SOD in the skin and GSH in the liver and blood increased significantly, whereas LPO in the liver and blood decreased in comparison to irradiated control animal. Thus, *aloe vera* leaf extract was found to have damage-

resistant properties against  $\gamma$ -ray radiation-induced biochemical alterations in Swiss albino mice. In the present animal experiments, the authors demonstrated survival assay as follows: mice of both control (only irradiation) and experimental groups (*aloe vera* leaf extract treated animal group with  $\gamma$ -ray irradiation) were exposed to whole-body  $\gamma$ -ray radiation (6 Gy) and checked daily for 30 days. The survival percentage of mice up to 30 days of exposure against each  $\gamma$ -ray radiation dose was used to construct survival dose-response curve. Regression analysis was done to obtain LD<sub>50/30</sub> values and to determine the dose-reduction factor (DRF). DRF results: The *aloe vera* leaf extract treated group was given as 100, 200, 400, 800, 1000, 1500, and 2000 mg/kg body weight per day in control group orally to Swiss albino mice for 15 consecutive days. The extract was nontoxic and no mortality was observed until day 30. An optimum dose of 1000 mg/kg body weight of *aloe vera* leaf extract was selected against 6 Gy  $\gamma$ -ray radiations on the basis of maximum survivability as depicted in figure 1<sup>[5]</sup>. The selected dose (1000 mg/kg body weight) was used to determine percent survival against various  $\gamma$ -ray radiations. When survival data were entered in the regression line equation, LD<sub>50/30</sub> values for control (irradiated alone) and experimental (*aloe vera* leaf extract plus irradiated) were computed as 6.54 and 10.84 Gy, respectively. On the basis of these LD<sub>50/30</sub> values, *aloe vera* leaf extract pretreatment produced a DRF of 1.657 (10.84/6.54), on survival dose-response curves for determination of LD<sub>50/30</sub>. (Figure 1)<sup>[5]</sup>.

Therefore, there is need to examine distinctly these individual ingredients for their abilities to prevent the x-ray radiation-induced accumulation of free radicals and membrane damages and to delay  $\gamma$ -ray radiation-induced mortality.

The radioprotective effect of *aloe vera* leaf extract was studied on  $\gamma$ -ray radiation-induced changes in the hepatic constituents of Swiss albino mice by same research group.

The mice were treated with 1000 mg/kg of body weight orally, once a day for 15 consecutive days, before exposure to single dose of  $\gamma$ -ray radiation (6 Gy), half an hour after the last administration. The  $\gamma$ -ray irradiation of mice caused a significant elevation in LPO followed by a decrease in GSH, acid phosphatase and alkaline phosphatase. The pretreatment of mice before irradiation elevated the GSH, acid phosphatase and alkaline phosphatase, and was accomplished by a decline in LPO. Recovery and regeneration from  $\gamma$ -ray radiation damage were faster in pretreated animals than the animals in the  $\gamma$ -ray irradiation-only group. The data clearly indicated that the oral treatment of *aloe vera* leaf extract significantly reduced the deleterious effects of  $\gamma$ -ray radiation on the liver and it could be a useful agent in reducing the side effects of therapeutic  $\gamma$ -ray radiation.

Phytochemicals, such as aloe polysaccharides, vitamin A, C and minerals; zinc and selenium, and pigments composed of anthraquinones and chlorophylls in *aloe vera* leaf extract may be responsible for the observed biological and pathological effects<sup>[6]</sup>.

(4) Effectiveness of *aloe vera* on antioxidant status of different tissues in irradiated rats.

The study was performed to evaluate the whole leaf juice filtrate of *aloe vera* on the antioxidant status in different tissues of animals whole body exposed to 7 Gy  $\gamma$ -ray radiation, delivered as a single shot dose to induce drastic biochemical changes. *Aloe vera* whole leaf juice filtrate was supplemented daily to rats (0.25 mL/kg body weight/day), by feeding, 5 days before irradiation and 10 days after irradiation. Experimental investigations performed 3, 7 and 10 days after exposure to radiation showed that *aloe vera* whole juice filtrate treatment has significantly minimized the radiation-induced increase in the amount of malondialdehyde in liver, lung, and kidney tissues of irradiated rats. Significant amelioration in superoxide dismutase

(SOD) and catalase activities was observed from the 3<sup>rd</sup> up to the 10<sup>th</sup> days for lungs, on the 7<sup>th</sup> and 10<sup>th</sup> days for kidneys and at 10<sup>th</sup> days for liver. Data obtained showed that for the different tissues, improvement in the decrease of reduced glutathione (GSH) contents was obvious on the 10<sup>th</sup> day after irradiation. Treatment with *aloe vera* whole leaf juice filtrate was also effective in minimizing the radiation-induced increase in plasma glucose levels throughout the experimental period, while it has not ameliorated the increase in plasma insulin levels. It could be concluded that the synergistic relationship between the ingredients found in the leaf juice filtrate of *aloe vera* could be a useful adjunct for maintaining the integrity of the antioxidation status<sup>[7]</sup>.

#### Topical application of *aloe vera* gel

The effect of *aloe vera* gel/mild soap versus mild soap alone in preventing skin reactions in patients undergoing radiation therapy.

The mean age of the participants was 56 years. The group consisted of Caucasians (74%) and Africans (26%). The ethnic mix was non-Hispanic (65%) and Hispanic (35%). Prophylactic skin care began on the first day of radiation therapy. Patients cleansed the area with mild, unscented soap. Patients randomized into the experimental arm of the trial were instructed to liberally apply *aloe vera* gel to the area at various intervals throughout the day. At low cumulative dose levels  $\leq 2700$  cGy, no difference existed in the effect of adding *aloe vera* gel. When the cumulative dose was high ( $>2700$  cGy), the median time was five weeks prior to any skin changes in the aloe/soap arm versus three weeks in the soap only arm. When the cumulative dose increases over time, there seems to be a protective effect of adding *aloe vera* gel to the soap regimen<sup>[8]</sup>.

#### Intra peritoneal injection of *aloe vera* leaf extract

Radioprotective efficacy of *aloe vera* leaf extract: Swiss albino mice were given *aloe vera* leaf extract in dry powder form daily over 4 days via intraperitoneal injection in 0.1 mL of distilled water. On the last day, i.e. day 4, they were irradiated 30 min after injection, and this day was considered as day zero. Animals were then autopsied on days 1, 3, 7, 14, and 30. Testes were removed and processed for histopathological observations. Other parameters studied were animal body weight, testes weight and mortality. To evaluate radiation effects, radioprotective efficacy, and toxicity of the *aloe vera* extract, animals were divided into different groups as follows: Group 1: Normal animal receiving only 0.1 mL distilled water as vehicle i.p. Group 2: To evaluate the acute toxicity of the *aloe vera* extract, it was injected at doses of 50, 100, 200, 400, 600 and 800 mg/kg body weight to different subgroups of animals. Group 3: To evaluate the toxic effects of the *aloe vera* extract over 30 days, two dose levels, i.e., 50 and 100 mg/kg, were given to two groups of animals. Group 4: For a radiation-treated control study, animals were exposed to a LD<sub>50/30</sub> dose of radiation, i.e., 8 Gy on day zero without any other treatment. Group 5: To study radioprotective efficacy, the *aloe vera* extract was injected at 50 and 100 mg/kg dose levels, and on day zero, animals were irradiated with 8 Gy  $\gamma$ -radiation. Radiomodifying effects of the leaf extract of *aloe vera* were observed on the testes of Swiss albino mice at 50 and 100 mg/kg dose levels. The extract was non-toxic when injected up to 800 mg/kg, and significant enhancement in survival time of the irradiated group was observed. In addition, the treatment reduced  $\gamma$ -ray radiation-induced quantitative and qualitative damages to germ cells, i.e., spermatogonia type A, B, primary and secondary spermatocytes, spermatids, and loss in body weight. (Tables 1, 2, 3)<sup>[9]</sup>.

Radioprotective efficacy of *aloe vera* leaf extract for the proliferation of radiosensitive germ cell layer was observed, but the

mode of radioprotection of *aloe vera* was not established, since no single definite active ingredient has been identified to date.

## NEGATIVE EFFECTS OF ALOE VERA GEL FOR $\gamma$ -RAY-RADIATION PROTECTION IN PHASE II TO III PATIENTS

### Topical application of *aloe vera* gel

(1) A phase III trial comparing an anionic phospholipid-based cream and *aloe vera*-based gel in the prevention of radiation dermatitis in pediatric patients

Radiation dermatitis is a common side effect of radiation therapy (RT). In severe cases, RT must be interrupted until the skin heals, which can compromise treatment. The purpose of the study was to compare an anionic phospholipid (APP)-based cream and an *aloe vera*-based gel to determine their effectiveness in preventing and treating radiation dermatitis. Forty-five pediatric patients (median age, 11 years) with various diagnoses who received at least 23.4 Gy participated. APP cream (a novel oil-in-water emulsion and the ingredients are triglycerides and phospholipids preserved with benzyl alcohol, methyl paraben, propyl paraben, and diazolidinyl urea) and *aloe vera* gel (the ingredients are water, *aloe vera*, D-panthenol, triethanolamine, carbomer 934P, hyaluronic acid, potassium sorbate, diazolidinyl urea, methylparaben, and propylparaben) were symmetrically applied within the irradiated field after each treatment. Three measures were collected before, during and after completion of treatment: subject's skin comfort, dermatologic assessment, and common toxicity criteria (CTC). Significant differences in specific variables favoring APP cream use were noted in some patients including skin comfort variables, dry ( $p=0.002$ ), soft ( $p=0.057$ ), feels good ( $p=0.002$ ), rough ( $p=0.065$ ), smooth ( $p=0.012$ ) and dermatologic variables, dryness ( $p=0.013$ ), erythema ( $p=0.002$ ) and peely ( $p=0.008$ ). Group CTC scores were supportive of APP cream ( $p=0.004$ ). In comparing the first and last assessments, two dermatologic variables, dryness ( $p=0.035$ ) and peely ( $p=0.016$ ), favored APP cream. APP cream was more effective than an *aloe vera*-based gel for prevention and treatment of radiation dermatitis in children treated to doses exceeding 23.4 Gy<sup>[10]</sup>.

(2) Comparison of three instrumental methods for the objective evaluation of radiotherapy induced erythema in the breast cancer patients and a study of the effect of skin lotion.

A non-blinded three armed study of the effect of *aloe vera*, Essex (a commonly recommended and used lotion at radiotherapy departments in Sweden) and no lotion on erythema was performed. The erythema is an effect of radiotherapy treatment in breast cancer patients. The study required testing of objective methods for measuring the erythema. The chosen experimental methods were Near Infrared Spectroscopy, Laser Doppler Imaging and Digital Colour Photography. The experimental setup was made in such a way that in parallel with testing the effect of the lotions there was also a test of sensitivity of the instruments. Fifty women were selected consecutively to participate in the study. They were all subjected to treatment with high-energy electrons (9-20 MeV) after mastectomy, 2 Gy/day to a total dose of 50 Gy. Measurements were performed before the start of radiotherapy and thereafter, once a week during the course of treatment. *Aloe vera* and Essex lotion were applied twice every radiation day in selected sites. The increase in skin redness could be monitored with all techniques with a detection limit of 8 Gy for Digital Colour Photography and Near Infrared Spectroscopy and 18 Gy for Laser Doppler Imaging. In clinical practice recommendation is to use Digital Colour Photography. No significant

median differences were observed between the pairs no lotion-Essex, no lotion-*Aloe vera* and Essex-*Aloe vera* for any of the techniques tested<sup>[11]</sup>.

(3) A phase III study on the efficacy of topical *aloe vera* gel on irradiated breast tissue.

A phase III study was conducted involving 225 patients with breast cancer after lumpectomy or partial mastectomy, who required a course of radiation therapy using tangential fields. Patients were randomized to either topical *aloe vera* gel or topical aqueous cream to be applied 3 times per day throughout and for 2 weeks after completion of radiation treatment. Weekly skin assessments were performed by nursing staff. Aqueous cream was significantly better than *aloe vera* gel in reducing dry desquamation and pain related to treatment. Subjects with D cup or larger size breasts experienced significantly more erythema, regardless of treatment arm. For subjects who had undergone lymphocele drainage, the *aloe vera* group experienced significantly more pain than the aqueous cream group. Within the aqueous cream arm, smokers were significantly more likely to experience itching within the treatment field than were nonsmokers. Within the *aloe vera* arm, subjects who had undergone one or more lymphocele drainages after surgery were significantly more likely to experience erythema and itching within the treatment field than those who did not have drainages. Aqueous cream was useful in reducing dry desquamation and pain related to radiation therapy<sup>[12]</sup>.

On the basis of systematic literature review and critical appraisal, there was no evidence from clinical trials to suggest topical *aloe vera* is effective in preventing or minimizing radiation-induced skin reactions in cancer patients<sup>[13]</sup>.

### Oral administration of *aloe vera*

Phase II double-blind randomized study comparing oral *aloe vera* versus placebo to prevent radiation-related mucositis in patients with head-and-neck neoplasms.

Radiation-induced mucositis, a side effect of head-and-neck cancer radiotherapy, can lead to pain, poor oral intake, weight loss, and treatment interruptions that can be detrimental to cancer cure. *Aloe vera* gel is used to prevent radiation-related dermatitis and may have anti-inflammatory properties through inhibition of cyclooxygenases. In the study, 58 head-and-neck cancer patients, who were scheduled to receive radiotherapy doses  $\geq 50$  Gy were randomized to either 20 mL *aloe vera* gel juice or placebo per oral 4 times/day during radiotherapy. Patients were stratified by primary tumor site and chemotherapy. Double blinks were used to minimize biases. Patients were evaluated biweekly with quality of life questionnaires. A physician also scored mucositis according to Radiation Therapy Oncology Group criteria. There was no statistically significant difference between the two groups in maximum grade toxicity or the duration of grade  $\geq 2$  mucositis during the course of radiotherapy. Quality of life scores, though slightly favoring the *aloe vera* gel arm, were not statistically different when using a long rank test of the equality of Kaplan-Meier curves. In this analysis a  $\geq 3$  point change in quality of life score was defined as a failure event. Multivariate analysis using the Cox proportional hazard model to control for age, sex, performance status, radiation dose, T stage, N stage, and prior surgery confirmed the lack of difference between the two arms. Other objective measures including use of pain medications, percent weight loss, hydration requirement, oral infections, prolonged radiotherapy breaks or the overall treatment time were not different between the two arms ( $p>0.05$ ). It was concluded that oral *aloe vera* is not a beneficial adjunct to head-and-neck radiation in single institution randomized study<sup>[14]</sup>.

## POSSIBLE PROPHYLACTIC EFFICACY OF ALOE POLYSACCHARIDES FOR $\gamma$ -RAY RADIATION-INDUCED DAMAGES

### Topical application of aloe polysaccharides

Acemannan-containing wound dressing gel reduces radiation-induced skin reactions in C3H mice.

To determine whether a wound dressing gel that contains aloe polysaccharides (acemannan) extracted from *aloe vera* gel affects the severity of  $\gamma$ -ray radiation-induced acute skin reactions in C3H mice, the following experiments were done. Male C3H mice received graded single doses of  $\gamma$ -ray radiation from 30 to 47.5 Gy to the right leg. The gel was applied daily beginning on day -7, 0, or +7 relative to the day of  $\gamma$ -ray radiation (day 0) and continuing for 1, 2, 3, 4 or 5 weeks. The right inner thigh of each mouse was scored on a scale of 0 (no visible reaction) to 3.5 (breakdown on the skin over the entire radiation field with severe exudation) for severity of  $\gamma$ -ray radiation reaction from the seventh to the 35<sup>th</sup> day after  $\gamma$ -ray radiation. Dose-response curves were obtained by plotting the percentage of mice that reached or exceeded a given peak skin reaction as a function of dose. Curves were fitted by logit analysis and ED<sub>50</sub> values, and 95% confidence limit were obtained. In the results, the average peak skin reactions of the wound dressing gel-treated mice were lower than those of the untreated mice at all radiation doses tested. The ED<sub>50</sub> values for skin reactions of 2.0-2.75 were approximately 7 Gy higher in the wound dressing gel-treated mice. Reduction in the percentage of mice with skin reactions of 2.5 or more was greatest in the groups that received wound dressing gel for at least 2 weeks beginning 1 week after  $\gamma$ -ray radiation. Wound dressing gel containing acemannan reduced acute  $\gamma$ -ray radiation-induced skin reactions in C3H mice if applied daily for at least 2 weeks beginning immediately after  $\gamma$ -ray radiation.

Acemannan, a highly acetylated  $\beta$ -1,4 mannan; one of the constituents of wound dressing gel, induces secretion of several cytokines, such as tumor necrosis factor and interleukin-1. It was speculated that some of these cytokines were thought to regulate wound healing and might also affect acute  $\gamma$ -ray radiation injury<sup>[15]</sup>.

A recent systematic review on *aloe vera* gel for burn healing concluded that the group that was being given *aloe vera* recorded a healing time that was 8.79 days shorter than those in the control group ( $p=0.006$ )<sup>[16]</sup>. In the treatment of bed-sore study, patients suffering from I to II degree with 0.1% aloe polysaccharides-ointment improved the severity of skin lesions. The results suggested that aloe polysaccharides can physically absorbed and hold the exudates because of its osmotic property, providing desirable moisture condition to minimize ulcerated skin pains<sup>[17]</sup>.

Topical therapeutic trials of aloe polysaccharide for bed-sores, burn-wound healing, and  $\gamma$ -ray radiation were fully expected.

### Intra peritoneal injection of *aloe vera* polysaccharides

Aloe polysaccharides mediated radioprotective effect through the inhibition of apoptosis.

Aloe has been traditionally used as a folk remedy for various diseases in wound healing and as an immuno regulator, and is a rich source of polysaccharides. A wound dressing gel that contains aloe polysaccharides extracted from *aloe vera* gel reduced acute  $\gamma$ -ray radiation-induced skin reactions in C3H mice. Radioprotective effects of aloe polysaccharides on normal human cells *in vitro* and mouse survival *in vivo*, and the mechanism were demonstrated by Wang Z *et al*, as follows: Pretreatment with 50  $\mu$ g/mL aloe polysaccharides could improve the surviving at 2 Gy of

three normal cell lines 293, ECV304, and Chang liver from 41.5%, 46.5%, and 40.9% to 49.4%, 72.1%, and 89.1%, respectively. Aloe polysaccharides could also reduce the apoptosis rate of Chang liver cells from 9.5% and 43.0% to 2.2% and 10.9% 48 h and 72 h after 2 Gy irradiation, respectively. Western blot analysis showed that pretreatment with aloe polysaccharides could block the upregulation of pro-apoptotic p53, Bax, and Bad and the downregulation of Bcl-2 by  $\gamma$ -ray irradiation, suggesting that aloe polysaccharides cause a reduction in the cellular levels of the pro-apoptotic proteins and an increase in anti-apoptotic proteins. Aloe polysaccharides could lower thymocyte apoptosis of mice *in vivo* after 6 Gy irradiation and abrogate the cell cycle perturbation.

The effect of aloe polysaccharides on the mouse survival 30-day post-irradiation showed that the treatment with various doses of polysaccharides (12.5, 25, 50 and 100 mg/kg body weight, intraperitoneal route (i.p.) 30 min before irradiation) could substantially increase the 30-day survival rate of mice from 10.0% in animals irradiated alone to 30.0%, 60.0%, 86.0% and 72.0%, respectively. It was obvious that 50 mg/kg aloe polysaccharides provided the best protection. To demonstrate the time-effect relation, the mice were treated i.p. with aloe polysaccharide at 30, 60, and 90 min before irradiation, respectively. It could be shown that at the doses of 25 and 50 mg/kg body weight, 30 min before irradiation was the optimum time for the radioprotective effect of aloe polysaccharides. Fifty mg/kg of aloe polysaccharides i.p. treatment for 30 min before 7.5 Gy irradiation provided the best radioprotective effect and improved the 30-day survival rate of mice to 86.0%, from 10.0%. The irradiated animal death may be attributed to immune organic pathological changing and immune suppression. It was suggested that aloe polysaccharides exerted radioprotective effects *in vitro* and *in vivo* through an inhibition of apoptosis following the alleviating of a thymus organ injury (Table 4, 5)<sup>[18]</sup>.

## ALOE VERA PHENOLIC INHIBITORS FOR INSULIN RECEPTOR

### *In vitro* insulin permeation enhancement by *aloe vera* gel

Drug absorption and permeation enhancement potential of *aloe vera* gel was shown to be available from the viewpoint of drug delivery system<sup>[19]</sup>. The *aloe vera* gel was able to significantly increase the transport of insulin across Caco-2 cell monolayers at pH 7.4<sup>[20]</sup>. Use of *aloe vera* gel as a drug absorption enhancing agent was expected for insulin receptor.

### Effect of a polyphenol-rich extract from *aloe vera* gel on experimentally induced-insulin resistance in mice

*Aloe vera* gel extract containing phenolic materials; such as aloin and aloe-emodin and aloe polysaccharides was administered orally in experimentally induced-insulin resistance mice. The phenolic materials-enriched *aloe vera* gel extract diminished the insulin resistance<sup>[21]</sup>. It was shown that the *aloe vera* gel extract containing phenolic materials and polysaccharides, could be effective for the control of insulin resistance by the decrease in plasma insulin levels<sup>[22]</sup>. Pharmaceutical studies on drug absorption enhancing properties for insulin transport, were needed to confirm in phenolic materials and aloe polysaccharides as adjuvants<sup>[23]</sup> from the sustained release forms of drug delivery system.

### Topical insulin treatment for wound healing in diabetes by enhancing the AKT and ERK pathway in rats

Topical insulin use for wound healing was investigated in insulin

signaling by immunoblotting during wound healing of control and diabetic animals with or without topical insulin, and topical insulin cream markedly improved wound healing by increasing in the expression of insulin, insulin signaling 1/2, SHC, ERK, and AKT passway in the skin of rats. In diabetic patients, topical insulin cream markedly improved wound healing, representing an attractive and cost-free method for treating diabetic complications<sup>[24]</sup>.

#### Effect of insulin on cellular and molecular mechanisms of processed *aloe vera* gel with a phenolic ingredient in db/db and diet-induced obese-diabetic mice and clinical study in subjects with pre diabetes/metabolic syndrome

The processed/modified aloe polysaccharides with molecular weight of ~80 KD, was obtained from the limited enzyme (cellulase) digestion of *aloe vera* gel, and improved insulin sensitivity via the suppression of obesity-induced inflammation in obese mice. The beneficial effects of the processed *aloe vera* gel with respect to obesity-induced insulin resistance and hepatic steatosis have been associated with its action by reducing levels of the pro-inflammatory cytokines; PPAR  $\gamma$ /LXR  $\alpha$ , and 11-HSD1, and by enhancing anti-inflammatory cytokines in white adipose tissue and liver, both of which are important peripheral tissues for insulin response. The processed/modified *aloe vera* gel was demonstrated to be useful dietary nutraceuticals for improving not only obesity-induced inflammation but also obesity-related metabolic disorders<sup>[25]</sup>.

The formulation (UP780) with the processed *aloe vera* gel and aloe chromones; aloesin and aloesinol, improved the insulin sensitivity in db/db and diet-induced obese-diabetic mice<sup>[26]</sup>. Further preclinical study of UP780 (*aloe vera* inner leaf gel powder standardized with 2% aloesin group) showed significant reductions in HbA1c, fructosamine, fasting glucose, insulin and homeostasis model assessment (a marker of insulin sensitivity) in total 45-subjects ( $n=15$ /group) with pre-diabetes/metabolic syndrome during 8-weeks supplementation. Standardized *aloe vera* gel preparation (UP780) restored the impaired fasting glucose and impaired glucose tolerance, and decreased in the insulin level observed in condition of prediabetes/metabolic syndrome. The *aloe vera* supplementation could beneficially be used in subjects with prediabetes/metabolic syndrome without any side effects<sup>[27]</sup>.

## CONCLUSION

The protection mode of *aloe vera* extract against  $\gamma$ -ray radiation-induced skin wound was not established, because definite active ingredient(s) has not been identified to date. Clinical evidence indicates that insulin normalizes cell permeability, reduces exudation, stimulates proliferation, decreases hypoxia of surrounding tissue and increases contraction of the wound.

Deficiency of insulin or the insensitivity of its receptors plays a key role in wound healing.

Recent pharmacokinetic and pharmacodynamic studies on anti hyperglycemic activity of aloins in *aloe vera*, for insulin receptor-binding properties were exhibited on the basis of computational analysis (28), and a phenolic ingredient aloesin and modified aloe polysaccharides as adjuvants in *aloe vera* gel were demonstrated in the subjects with prediabetes/metabolic syndrome through several different mechanisms in insulin sensitivity impairment.

Further pro-inflammatory studies on insulin response, resistance and/or sensitivity of its receptors and molecular interaction as therapeutic ligand of aloe phenolic component(s) are imperatively needed to confirm a possible prophylactic efficacy of *aloe vera* gel for  $\gamma$ -ray/photo radiation-induced skin damages, wound repair

and regeneration, and the prevention of age-related pathology. Furthermore, aloe polysaccharides being safe and well-tolerated, play critical roles in immune function and could be one of strong therapeutic candidates on quality of life issue regarding skin integrity among radiation therapy patients, and the study of synergistic effect of phenolic ingredient(s) and polysaccharides has future potential of *aloe vera* gel.

## REFERENCES

- Collins CE, Collins C. Roentogen dermatitis treated with fresh whole leaf of *aloe vera*. *Am J Roentogen* 1935; **33**: 396-397
- Lushbaugh CC, Hale DB. Experimental acute radiodermatitis following  $\beta$ -radiation. V. Histopathological study of the mode of action of therapy with *Aloe vera*. *Cancer* 1953; **6**: 690-699
- Saini DK, Saini MR. Evaluation of radioprotective efficacy and possible mechanism of action of *Aloe* gel. *Environmental Toxicology and Pharmacology* 2011; **31**: 427-435
- Atiba A, Nishimura M, Kakinuma S, Hiraoka T, Goryo M, Shimada Y, Ueno H, Uzaki Y. *Aloe vera* oral administration accelerates acute radiation-delayed wound healing by stimulating transforming growth factor- $\beta$  and fibroblast growth factor production. *Am J Surg* 2011; **201**: 809-818
- Goyal PK, Geholt P. Radioprotective effects of *aloe vera* leaf extract on Swiss albino mice against whole-body  $\gamma$ -ray irradiation. *J Environ Pathol Toxicol* 2009; **28**: 53-61
- Geholt P, Soyol D, Goyal PK. Prevention of radiation-induced hepatic damage in Swiss albino mice by *aloe vera* leaf extract. *Nuclear Technology & Radiation Protection* 2010; **25**: 186-191
- Saada HN, Ussama ZS, Mahdy AM. Effectiveness of *aloe vera* on the antioxidant status of different tissues in irradiated rats. *Pharmazie* 2003; **58**: 929-931
- Olsen DL, Raut W Jr, Bradley C, Johnson M, Macias JL, Love V, Markoe A. The effect of *aloe vera* gel/mild soap versus mild soap alone in preventing skin reactions in patients undergoing radiation therapy. *Oncol Nurs Forum* 2001; **28**: 543-547
- Pande S, Kumar M, Kumar A. Radioprotective efficacy of *aloe vera* leaf extract. *Pharmaceutical Biology* 1998; **36**: 227-232
- Merchant TE, Bosley C, Smith J, Baratti P, Pritchard D, Davis T, Chenghong L, Xiaoping X. A phase III trial comparing an anionic phospholipid-based cream and *aloe vera*-based gel in the prevention of radiation dermatitis in pediatric patients. *Radiat Oncol* 2007; **2**: 45-50
- Nystrom J, Svensk AC, Lindholm-Sethson B, Geladi P, Larson J, Franzen L. Comparison of three instrumental methods for the objective evaluation of radiotherapy induced erythema in breast cancer patients and a study of the effect of skin lotions. *Acta Oncologica* 2007; **46**: 893-899
- Heggie S, Bryant GP, Tripcony L, Keller J, Rose P, Glendenning M, Heath J. A phase III study on the efficacy of topical *aloe vera* gel on irradiated breast tissue. *Cancer Nurs* 2002; **25**: 442-451
- Richardson J, Smith JE, McIntyre M, Thomas R, Pilkington K. *Aloe vera* for preventing radiation-induced skin reactions: a systematic literature review. *Clin Oncol (R Coll Radiol)* 2005; **17**: 478-484
- Su CK, Meththa V, Ravikumar L, Shah R, Pinto H, Halpem J, Koong A, Goffinet D, Le Q. Phase II double-blind randomized study comparing oral *aloe vera* versus placebo to prevent radiation-related mucositis in patients with head-and-neck neoplasms. *Int J Radiat Oncol Biol Phys* 2004; **60**: 171-177
- Roberts DB, Travis EL. Acemannan-containing wound dressing gel reduces radiation-induced skin reactions in C3H mice. *Int J Radiat Oncol Biol Phys* 1995; **32**: 1047-1052
- Maenthaisong R, Chalyakunapruk N, Niruntraporn S, Kong-

## Yagi A. Aloe vera for $\gamma$ -ray radiation-induced damages

- kaew C. The efficacy of aloe vera used for burn wound healing: a systemic review. *Burns* 2007; **33**: 713-718
- 17 Matsuo K, Yagi A, Kabbash A. Case reports of bed sores using aloe vera gel powder with high molecular weight. *Phcog Res* 2009; **1**: 136-142
- 18 Wang ZW, Zhou JM, Huang ZS, Yang AP, Liu ZC, Xia YF, Zeng YX, Zhu XF. Aloe polysaccharides mediated radioprotective effect through the inhibition of apoptosis. *J Radiat Res (Tokyo)* 2004; **45**: 447-454
- 19 Lebitsa T, Viljoen A, Lu Z, Hamman J. In vitro drug permeation enhancement potential of aloe gel materials. *Curr Drug Deliv* 2012; **9**: 297-304
- 20 Hamman JH. Composition and applications of Aloe vera leaf gel. *Molecules* 2008; **13**: 1599-1616
- 21 Perez YY, Jimenez-Ferrer E, Zamilpa A, Hernandez-Valencia M, Alarcon-Aquilar FJ, Tortoriello J, Roman-Ramos R. Effect of a polyphenol-rich extract from Aloe vera gel on experimentally induced insulin resistance in mice. *Am J Chin Med* 2007; **35**: 1037-1046
- 22 Kim K, Kwon J, Lee S, Kong H, Im SA, Lee YH, Lee YR, Oh ST, Jo TH, Park YI, Lee CK, Kim K. Hypoglycemic and hypolipidemic effects of processed aloe vera gel in a mouse model of non-insulin-dependent diabetes mellitus. *Phyto-medicine* 2009; **16**: 856-863
- 23 Petrovsky N, Cooper PD. Carbohydrate-based immune adjuvants. *Expert Rev Vaccines* 2011; **10**: 523-527
- 24 Lima MHM, Caricilli AM, de Abreu LL, Araujo EP, Pelegri-nell FF, Thirone ACP, Tsukamoto DM, Pessoa AFM, dos Santos MF, de Moraes MA, Cavalheria JBC, Velloso LA, Saad MJA. Topical insulin accelerates wound healing in diabetes by enhancing the AKT and ERK pathway: a double-blind placebo-controlled clinical trial. *PLoS ONE* 2012; **7**: e36974
- 25 Shin E, Shim KS, Kong H, Lee S, Shin S, Kwon J, Jo TH, Park YI, Lee CK, Kim K. Dietary Aloe improves insulin sensitivity via the suppression of obesity-induced inflammation in obese mice. *Immune Network* 2011; **11**: 59-67
- 26 Yimam M, Zhao J, Comeliussen B, Pantier M, Brownell LA, Jia Q. UP780, a chromone-enriched Aloe composition improves insulin sensitivity. *Metab Syndr Relat Disord* 2013; Apr **10**
- 27 Devaraj S, Yimam M, Brownell LA, Jialal L, Singh S, Jia Q. Effects of Aloe vera supplementation in subjects with pre-diabetes/metabolic syndrome. *Metab Syndr Relat Disord* 2013; **11**: 35-40
- 28 Chatterjee S, Narasimhaiah AL, Kundu S, Anand S. Anti-hyperglycaemic study of natural inhibitors for insulin receptor. *Bioinformation* 2012; **8**: 1195-1201

**Peer reviewer:** Byung Pal Yu, PhD, Professor Emeritus, University of Texas , Health Science Center, San Antonio, TX 78229, the United States of America.