

Diagnosis and Treatment of Splenic Abscess (about 11 cases)

Bassem Nasr, Amine Chhaider, Mohamed Ben Mabrouk, Mehdi Ben Hadj Hamida, Waad Farhat, Mouna Ben Othmen, Jaafar Mazhoud, Fathia Harrabi, Mohamed Azzaza, Walid Naija, Fethi Derbel, Ali Ben Ali, Ridha Ben Hadj Hamida

Bassem Nasr, Amine Chhaider, Mohamed Ben Mabrouk, Mehdi Ben Hadj Hamida, Waad Farhat, Mouna Ben Othmen, Jaafar Mazhoud, Fathia Harrabi, Mohamed Azzaza, Walid Naija, Fethi Derbel, Ali Ben Ali, Ridha Ben Hadj Hamida, Department of surgery. University hospital sahloul. 4051. Sousse.Tunisia

Correspondence to: Fethi Derbel, MD, Department of General Surgery, Sahloul Hospital, Sousse, Tunisia. fethi.derbel@gmail.com

Telephone: +216 24130460

Received: June 9, 2013

Revised: July 4, 2013

Accepted: July 6, 2013

Published online: September 21, 2013

ABSTRACT

AIM: To describe the clinical features, etiology, imaging findings, bacteriologic profile, treatment and outcome in patients presenting splenic abscess in a Tunisian hospital.

METHODS: It is a retrospective study, where we reviewed 11 splenic abscess cases that were hospitalized between January, 1st 2000 and October, 31st 2009.

RESULTS: Eleven cases (5 males, 6 females) were found., the mean age was 59 years. Fever was found in 7 cases, the left-upper-quadrant guarding was found in 6 cases, splenomegaly was found in 2 cases were the main clinical signs. Laboratory tests revealed leukocytosis and elevated level of CRP in all cases. All patients were investigated by ultrasound and CT scan. The primary site of infection was found in 3 cases, (endocarditis and urinary infection). There was one case of epithelial cyst of the spleen that was secondarily infected and in the other 7 cases the etiology was not found; it was about primary spleen damage. Treatment was essentially surgical (total splenectomy) except for one case which was treated medically (antibiotics) and successfully. The outcome was generally favorable with the exception of two deaths from septic shock (originating from a urinary infection)

CONCLUSION: . The abscess of the spleen is a rare condition. Its clinical expression is highly polymorphic. Its positive diagnosis is based on imaging; the diagnosis must be made in good time to ensure timely treatment, which may be medical, interventional or surgical. The outcome after treatment is usually favorable.

Key words: Spleen; Abscess; Splenectomy; percutaneous drainage, antibiotics

Nasr B, Hamida MBH, Farhat W, Othmen MB, Chhaider A, Mabrouk MB, Mazhoud J, Harrabi F, Azzaza M, Naija W, Derbel F, Ali AB, Hamida RBH. Diagnosis and Treatment of splenic Abscess (about 11 cases). *Journal of Gastroenterology and Hepatology Research* 2013; 2(9): 786-790 Available from: URL: <http://www.ghrnet.org/index.php/joghr/article/view/483>

INTRODUCTION

The abscess of the spleen is rare but fatal in the absence of treatment. The incidence of this condition after large series of Western autopsy is estimated to be up to 0.7%^[1].

It is defined by the presence of one or more intraparenchymal or subcapsular collections of pus in the spleen. Its polymorphic symptomatology explains the difficulties of clinical diagnosis.

The diagnosis and treatment had been known well in the last century, and gains a great advances in recent decades because of the development of medical imaging (such as CT, ultrasound etc.). Thus, the mortality and morbidity of Spleen Abscess has decreased greatly.

METHODS

This is a retrospective study covering the period from 1 January 2000 until 31 October 2009 conducted in the digestive and visceral surgery department at Sahloul university hospital of Sousse, TUNISIA.

We report a series of 11 cases over 9 years.

The diagnosis was made on clinical, biological and imaging data. The treatment was either medical (antibiotic) or surgical (splenectomy).

Clinical, biological, radiological, therapeutic and evolutive data were collected from the records of inpatients.

RESULTS

This study included 5 men and 6 women (sex ratio=0.8), the mean age was 59 years (range 21-80). Twenty seven percent of patients

had diabetes ($n=3$), 45.45% ($n=5$) were holders of cardiovascular problems (hypertension, PAD, coronary artery disease, ischemic stroke ...) and one case was operated for a gastric cancer. Fever was found in 63.63% of cases ($n=7$), the left-upper-quadrant guarding was found in 54.54% of cases ($n=6$), splenomegaly was found in 18.18%

of cases ($n=2$), and were the main clinical signs.

Laboratory tests revealed leukocytosis and elevated level of CRP in all cases.

All patients were investigated by ultrasound and CT scan, which showed a positive diagnosis in 100% of cases.

Table 1 Summary of clinical, biological, radiological and therapeutic data of 11 cases of splenic abscess.

Case	PATIENT 1
Age, Sex Past History	Male; 75 years old; hypertension, coronary insufficiency
Clinical Manifestations	Left upper-quadrant pain, secondarily generalized. On examination: abdominal guarding.
Laboratory Tests	Leukocytes : 25400 elements/mm ³
Imaging	Sonography: heterogeneous collection of lower pole of the spleen; intraperitoneal effusion
Treatment	Surgery: generalized peritonitis secondary to an abscess of the lower pole of the spleen:
Anatomical Pathology	Total splenectomy
Outcome	Good
Case	PATIENT 2
Age, Sex Past History	F; 72 years old, hypertension, diabetes, ischemic stroke
Clinical Manifestations	feveracute intestinal obstruction syndrome (abdominalpain+absence of efecation and passage of gases); O/E: bloated and sensitive abdomen.
Laboratory Tests	Leukocytes : 14800 elements/mm ³ ; CRP : 120 mg/L; 2 blood cultures (-) urinalysis: (+) in Gram-negative bacilli
Imaging	CT scan: hypodense image of spleen; Thickening of the left colonic wall at the junction with the rectum.
Treatment	Surgery: Abscess of upper pole of the spleen clogged by the greater omentum: total splenectomy
Anatomical Pathology	Non specific abscess
Outcome	Death 20 days after surgery (septic shock)
Case	PATIENT 3
Age, Sex Past History	F, 43 years old; Takayashu disease, PAOD, diabetes. Aorto-aortic bypass. Surgery for duodenal perforation
Clinical Manifestations	Fever+pain in the left upper-quadrant for 2 weeks. O/E: Splenomegaly.
Laboratory Tests	Leukocytes: 41000 elements/mm ³ . No germ isolated
Imaging	Sonography: hypoechogenic picture of the lower pole of the spleen. CT scan: a 5 cm hypodense lesion in the lower pole of the spleen
Treatment	Failure of medical treatment. Surgery: total Splenectomy
Anatomical Pathology	Chronic abscess of the spleen
Outcome	Good
Case	PPATIENT 4
Age, Sex Past History	M, 70 years old; Chronic pancreatitis,
Clinical Manifestations	Fever+vomiting and epigastric pain for 4 days. O/E: guarding of Left upper-quadrant
Laboratory Tests	Leukocytes: 14800 elements/mm ³ then 20500 elements/mm ³ . CRP: 111 mg/L
Imaging	Sonography: focal pancreatitis in chronic pancreatitis, cholelithiasis CT scan: peripancreatic fat infiltration with Mid splenic hypodense image (abscess). figure1
Treatment	Failure of medical treatment. Surgery: abscess of mid spleen broken, clogged with neighboring organs (peritonitis)Total splenectomy+Cholecystectomy
Anatomical Pathology	Non specific chronic abscess of the spleen
Outcome	Good
Case	PPATIENT 5
Age, Sex Past History	M , 80 years total gastrectomy for tumors of the cardia
Clinical Manifestations	Onset of fever 30 days after surgery. O/E: T 38.7°C soft abdomen
Laboratory Tests	Leukocytes : 16400 elemnts/mm ³
Imaging	Sonography 1: collection of upper pole of the spleen (2.5cm) Sonography 2 and CT scan: increased size of the abscess (7cm) (figure2).
Treatment	Failure of medical treatment. Surgery: subcapsular abscess of the upper pole of the spleen (7cm), total splenectomy
Anatomical Pathology	Abscess of the spleen without evidence of malignancy
Outcome	Good
Case	PATIENT 6
Age, Sex Past History	F, 52 years, hypertension, mitral and aortic regurgitation
Clinical Manifestations	Low-grade fever, asthenia, Left upper-quadrant pain since 2months O/E: T: 40°C. Guarding of Left upper-quadrant+ splenomegaly. No heart murmurs
Laboratory Tests	Leukocytes: 20800 elemnts/mm ³ . CRP : 220 mg/L
Imaging	Sonography: image hypoechoic of spleen. CT scan: hypodense collection by 10×13cm diameter (splenic abscess) with ipsilateral pleural effusion. Echocardiography: large mobile vegetation of the mitral valve
Treatment	Surgery: total splenectomy
Anatomical Pathology	Chronic abscess of the splenic parenchyma without evidence of specificity
Outcome	-
Case	PATIENT 7
Age, Sex Past History	F, 59 years, Diabetes on insulin ischemic stroke, Amputation 4 th , 5 th left toe
Clinical Manifestations	Severe sepsis (originally urinary)+ketoacidosis
Laboratory Tests	Leukocytes: 15800 elemnts/mm ³ ; CRP 330 mg/L. blood cultures + urine analysis: Klebsiella pneumoniae
Imaging	Sonography: training hypoechogenic upper pole of the spleen with minimal pericapsular effusion CT scan: collection of upper pole of the spleen Echocardiography: normal
Treatment	Surgery: Splenic abscess of the upper pole, broken, partitioned total splenectomy
Anatomical Pathology	Acute, suppurative and non specific inflammatory of spleen
Outcome	Death at 4 days post surgery (heart attack)

Case	PATIENT 8
Age, Sex Past History	F, 23 years, Cesarean 2 months ago (eclampsia crisis)
Clinical Manifestations	Abdominal trauma a few weeks ago. Fever+vomiting+Left upper-quadrant pain O/E: guarding of Left upper-quadrant
Laboratory Tests	Leukocytes: 20000 elemnts/mm ³ . CRP: 248 mg/L
Imaging	Sonography and CT scan: Encysted lesion of upper pole of the spleen (7 cm) hematoma? Abscess? (Figure2).
Treatment	Surgery: Left upper-quadrant shady effusion, large abscess of the spleen ruptured and sealed by the omentum: total splenectomy; appendectomy
Anatomical Pathology	Epithelial cyst of the spleen with inflammatory remodeling abscess. acute appendicitis
Outcome	Infection of the lining then favorable evolution
Case	PATIENT 9
Age, Sex Past History	M; 21 years old; Splenic abscess at the age of 9 years (puncture under CT: compulobacter fetus). Favorable evolution after antibiotic therapy
Clinical Manifestations	Left upper-quadrant pain since 21 days; fever since 3 days. O/E: Fever: 40°C; pain on palpation of Left upper-quadrant
Laboratory Tests	Leukocytes : 14600 elemnts/mm ³ . CRP : 10 mg/L
Imaging	CT scan: multiple small perihilar calcifications; rounded mid parenchymal formation, (fluid density), not enhanced by the contrast and without any distinctive wall: splenic abscess sequelae
Treatment	Surgery: umbilicated formation of the inner edge of the spleen: splenectomy
Anatomical Pathology	Fibrosclerotic calcified and ossified lesion of the spleen
Outcome	Favorable
Case	PATIENT 10
Age, Sex Past History	M, 75 years old, operated for a prostate adenoma 6 months ago
Clinical Manifestations	Fever + epigastralgia , bloody mucoid diarrhea. O/E : Fever: 39°C; Abdomen soft
Laboratory Tests	Leukocytes : 10400 elemnts/mm ³
Imaging	CT: medio splenic collection by 3.8 cm in diameter (splenic abscess) COLONOSCOPY: inflammatory bowel disease
Treatment	surgery: splenectomy
Anatomical Pathology	splenic infarction
Outcome	Favorable
Case	PATIENT 11
Age, Sex Past History	F, 78 years old; stroke 21 years ago
Clinical Manifestations	Fever, Left upper-quadrant and epigastric pain ; vomiting. O/E : T = 38.4°C; guarding of Left upper-quadrant
Laboratory Tests	Leukocytes: 9300 elemnts/mm ³ . CRP :128 mg/L
Imaging	CT: hypodense non cystic nodular formation of the spleen (splenic abscess)
Treatment	Medical treatment: three-antibiotic therapy (claforan + flagyl + genta)
Anatomical Pathology	-
Outcome	good evolution

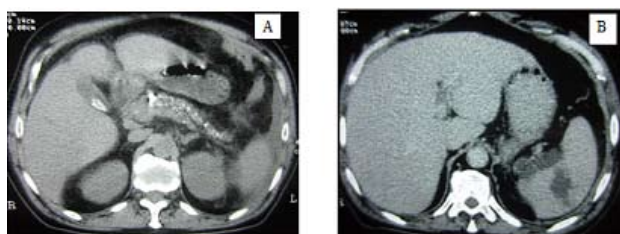


Figure 1 A: chronic Pancreatitis; B: Mid splenic hypodense image (abscess).

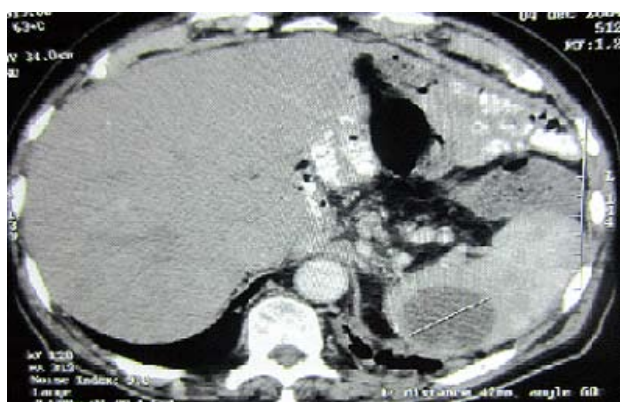


Figure 2 Collection of upper pole of the spleen (7 cm).

The primary site of infection was found in 3 cases, (endocarditis and urinary infection). There was one case of epithelial cyst of the spleen that was secondarily infected and in the other 7 cases the abscess; it was about primary spleen damage.

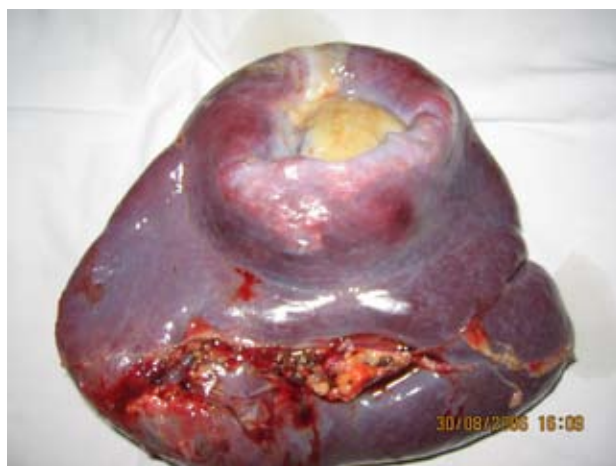

Figure 3 Abscess of spleen (total splenectomy).

Treatment was essentially surgical (total splenectomy) except for one case which was treated medically (antibiotics) and successfully.

The outcome was generally favorable with the exception of two deaths from septic shock (originating from a urinary infection).

DISCUSSION

The rarity of abscess of the spleen appears in all studies: 10 cases in 10 years for CHULAY^[2], 5 cases in 30 years for FALL^[3] and 11 cases in 9 years in our study. This scarcity may be explained by the fact that the spleen would have a capacity to resist local infections^[4]. The actual frequency is probably higher because of the existence

of deceptive forms or because it is decapitated by antibiotics^[5]. The abscess of the spleen in our study comes at a relatively advanced age (59 years) and predominantly amongst women (sex ratio=0.8). In the literature^[2], the condition also occurs most often in adults in their but predominance in terms of sex distribution in most studies is discordant: some authors found a higher frequency in women^[2,6,7] and others found it within men^[3,8-10].

Generally the suppurative infection of spleen is secondary and its primary focus is obscure because of its symptoms appearing after weeks or months following the primary infection receding.

The pathophysiology of splenic abscesses is still poorly understood, it may be better defined by the progress of medical imaging, however, three hypotheses as to its origin are still discussed:

Hematogenous: comes from other infective focus through blood, artery or portal vein, mainly artery route, such as endocarditis and childbed fever, accounting for about 75% to 90% of all Spleen abscess. In fact nearly all purulent infection of a human body can cause the abscess of spleen. Its common pathogen are Staphylococcus, Streptococcus and Pneumococcus etc.

In our study, the Splenic damage during a severe sepsis was noted in cases 2 and 7, and a result of infective endocarditis in case 6.

Intrinsic origin: The damage or infarct of Spleen, accounting for about 10% to 25% of abscess of the spleen. Even a small trauma to spleen could cause a hematoma, hence a secondary infection ensues, and Spleen abscess occurs. Thromboses, embolism, pathological hemoglobinemia are also common causes.

A preexisting lesion at the spleen on which is grafted an infectious violation. Example: splenic infarction, post traumatic hematoma, epithelial cyst of the spleen (case 8), malignant tumor of the spleen...

Extrinsic origin: affected by contiguity due to a neighboring infection. Adjacent viscera infection such as perinephric abscess, subphrenic abscess, acute pancreatitis, and gastrointestinal tumor etc could also invade directly to spleen and cause abscess of spleen. But, such conditions is rare, accounting for less than 10% of all the Spleen abscesses.

Immune suppress or defect such as critical illness, long-term use of immuno-suppressive drugs, AIDS patients. Besides, Spleen Cyst could also be infected to form abscess.

In addition, the pathogen for Spleen abscess could change under the widely usage of broad spectrum antibiotics. For example fungus (*Candida albicans*), anaerobic bacteria are also seen routinely and ameba is rare.

In terms of bacteriology, staphylococci and streptococci both prevail^[4] since it is highly related to infective endocarditis of which these germs are the most common causes^[7]. Thyphic abscesses and amoeba^[10] are rare. With our means of investigation we weren't always able to identify the causative agent.

Splenic abscesses occur in immuno-compromised individuals willingly by the presence of one or more defects. Indeed an underlying pathology was noted in 50% of cases [5], diabetes, leukemia, sickle cell anemia, cancer, cirrhosis, immunosuppressive treatment. In our study three patients had diabetes, five patients had cardiovascular problems (hypertension, PAD, coronary artery disease, ischemic stroke ...) and one case was operated for a gastric cancer.

The clinical features have no specificity; the classic triad made of painful and febrile splenomegaly is not always present. Indeed, fever is present in 7 cases, and pain or guarding of the left upper-quadrant in 6 cases, splenomegaly in 2 cases and in one case it was during the balance of septic shock that the splenic abscess was diagnosed and in another case the splenic abscess was discovered during an acute obstructive intestinal syndrome. More rarely, acute generalized

peritonitis is indicative of the abscess (one case).

Biological data are not contributory to the diagnosis of abscess of the spleen. It is a biological inflammatory syndrome associated with leukocytosis in 60 to 100% of cases^[11]. In our series, the inflammatory syndrome was present in 100% of cases.

It is the progress of medical imaging that facilitated the diagnosis of abscess of the spleen. Indeed, ultrasound can contribute to an early diagnosis^[3] showing a typically single or multiple hypo-echogenic image within the splenic parenchyma^[12]. Its sensitivity ranges from 75 to 95% depending on the series^[13,14]. But a hydatid cyst can be discussed because of our context (endemic hydatid disease). Misleading aspects of ultrasound are possible: hyper-echogenic or heterogeneous well circumscribed wide image suggesting malignancy. With a sensitivity close to 100%, the CT scan is better than ultrasound in terms of diagnosing splenic abscesses^[13,14]. In our series the couple CT scan / ultrasound showed a positive diagnosis in 100% of cases.

The invasive treatment of splenic abscess includes 3 options: percutaneous drainage, open or laparoscopic surgery (splenectomy), and open drainage.

Systematic splenectomy based therapy can be criticized because of high mortality and morbidity because there is a need to keep the spleen at the end to avoid overwhelming infections^[15]. The spleen is important for proper immunologic function, and splenectomy carries an increased morbidity rate with the danger of postsplenectomy infections^[15]. Current therapeutic strategies established spleen-preserving treatment in cases of trauma and benign lesions

In our study, about 90% of patients were treated by splenectomy and has achieved good results, only two deaths occurred and that were not attributed to splenectomy but were related to the loaded past patient's history. Only one patient received medical treatment (antibiotics) with success.

Currently puncture or percutaneous drainage both associated with antibiotic transformed the prognosis of splenic abscess^[5], contributing to the shortening of hospitalization, avoiding the risk of opening the abscess into the peritoneal cavity and preserving the splenic parenchyma.

The different current indications for the treatment of splenic abscess are:

Antibiotics alone: small abscesses or poorly collected.

Percutaneous drainage: Percutaneous drainage is indicated for easily accessible uniloculated or biloculated abscesses with otherwise favorable features, and also for surgical patients at very high risk who cannot tolerate general anesthesia or surgery. It is the first option especially if a patient is in a poor condition^[3,18].

Its indications according to GLEICH are: A unique non-partitioned collection with a thin wall.

The success rate is about 70%^[12].

However Contraindications to percutaneous drainage include the following^[18-19].

Multiloculated or debris-filled abscess

Multiple small abscesses

Uncontrollable coagulopathy

Poorly defined abscess on CT scan or ultrasonogram

Diffuse ascites

No safe route for drainage

Splenectomy: Splenectomy has long been considered the standard treatment of splenic abscess. Depending on the patient population, open splenectomy has a mortality rate of 0-17% and a morbidity rate of 28-43%

Laparoscopic splenectomy is safe and effective in selected patients. It can be performed with no morbidity or mortality, and patients who have undergone the procedure reportedly have a shorter hospital stay^[6].

No prospective, randomized study is available to determine the most effective treatment for splenic abscess. The diversity of the patient population suggests the importance of patient selection to improve outcome.

CT scanning is currently considered the criterion standard for helping to establish the diagnosis of splenic abscess. Percutaneous, CT-guided drainage is a safe, minimally invasive, and successful treatment option that should be used as a spleen-conserving alternative to surgery in suitable patients^[18-20].

CONCLUSION

The abscess of the spleen is a rare condition. Its clinical expression is highly polymorphic. Its positive diagnosis is based on imaging; the diagnosis must be made in good time to ensure timely treatment, which may be medical, interventional or surgical. The outcome after treatment is usually favorable.

REFERENCES

- 1 Reid SE, Lang SJ. Abscess of the spleen. *American Journal of Surgery* 1954; **88**: 912-917
- 2 Chullay JD, Lankerani Splenic abscess. Report of case and review of the literature. *Am J Med* 1966; **61**: 513-522
- 3 Fall B, Dansokho A, Tetiamiand KAM, Tooure HP. Abcès de la rate à propos de 5 observations. *J Chir* 1991; **128**: 256-259
- 4 Gadacz TR. Splenic abscess. *WJ Surg* 1985; **9**: 410-415
- 5 Chakroun M, Ladeb MF, Gahbiche M, Bouzouaia N. Les abcès de la rate. *Sem Hop, Paris* 1995; **71**: 858-863
- 6 Carbonell AM, Kercher KW, Matthews BD, Joels CS, Sing RF, Heniford BT. Laparoscopic splenectomy for splenic abscess. *Surg Laparosc Endosc Percutan Tech* 2004; **14**: 289-291
- 7 Choudhury SR, Rajiv C, Pitamber S, Akshay S, Dharmendra S. Management of splenic abscess in children by percutaneous drainage. *J Pediatr Surg* 2006; **41**: e53-56
- 8 Fotiadis C, Lavranos G, Patapis P, Karatzas G. Abscesses of the spleen: Report of three cases. *World J Gastroenterol* 2008; **14**: 3088-3091
- 9 LA Whorne TW, Zvidema GD. Splenic abscess. *Surgery* 1976; **79**: 686-689
- 10 Rotman N, Kracht M, Mathieu D, Fagniez PL. Abcès de la rate: Dignostic et traitement. A propos de 12 cas. *Ann chir* 1989; **3**: 203- 206
- 11 Loussaief C, Toumi A, Ben Romdhane F, Chakroun M, Bouzouaia N. Les abcès de la rate à pyogènes .À propos de 8 cas. *La Revue de Médecine nterne* 2005; **26**: 541-544
- 12 Gleich S, Wolin DA, Herbsman H. A review of percutaneous drainage in splenic abscess. *Surg Gynecol Obstet* 1986; **167**: 211-215
- 13 Nelken N, Ignatius J, Skinner M, Christensen N. Changing clinical spectrum of splenic abscess. A multicenter study and review of the litterature. *Am J Surg* 1987; **154**: 27-34
- 14 Ooi LL, Leong SS. Splenic abscesses from 1987 to 1995. *Am J Surg* 1997; **174**: 87-93
- 15 Freysm M, Jourden L, Rat P. Splénectomie et déficits immunitaires. *Sem hop Paris* 1989; **65**: 1720-1726
- 16 Sarr MG, Zuideman GD. Abscess. Présentation, diagnostic and treatment. *Surgery* 1982; **3**: 480-485
- 17 Simson NL. Solitary abscess of the spleen. *Br J Surg* 1980; **67**: 106-110
- 18 Ferraioli G, Brunetti E, Gulizia R, Mariani G, Marone P, Filice C. Management of splenic abscess: report on 16 cases from a single center. *Int J Infect Dis* 2009; **13**: 524-530
- 19 Schaberle W, Eisele R. Percutaneous ultrasound controlled drainage of large splenic abscesses. *Chirurg* 1997; **68**: 744-748
- 20 Alvi AR, Kulsoom S, Shamsi G. Splenic abscess: outcome and prognostic factors. *J Coll Physicians Surg Pak* 2008; **18**: 740-743

Peer reviewers: Lian-An Ding, Department of General Surgery, Eastern Branch of Affiliated Hospital, Qingdao University Medical College, No.59 Haier Road, High Scientific and Technical Garden of Laoshan, Qingdao, 266000, China; Gianluca Pellino, MD, General Surgery Unit, Second University of Naples, Via Giotto, 60, 81031, Aversa (CE) , Italy.