

Comparison of Liver Biopsy with Transient Elastography as a Non-invasive Method for Assessment of Liver Fibrosis

Eskandar Hajiani, Seyed Jalal Hashemi, Abdol Rahim Masjedizadeh, Ali Akbar Shayesteh, Pezhman Alavi Nejad, Ahmad Kadkhodae, Kousar Jalalvand

Eskandar Hajiani, Seyed Jalal Hashemi, Abdol Rahim Masjedizadeh, Ali Akbar Shayesteh, Pezhman Alavi Nejad, Ahmad Kadkhodae, Research Institute for Infectious Diseases of the Digestive System, School of Medicine, Ahvaz Jundishapur University of Medical Sciences, Ahvaz, Iran

Eskandar Hajiani, Jalal Hashemi, Abdol Rahim Masjedizadeh, Ali Akbar Shayesteh, Pezhman Alavi Nejad, Ahmad Kadkhodae, Division of Gastroenterology and Hepatology, Department of Internal Medicine, Ahvaz Jundishapur University of Medical Sciences, Ahvaz, Iran

Kousar Jalalvand, General Physician of Imam Hospital, Ahvaz Jundishapur University of Medical Sciences, Ahvaz, Iran

Correspondence to: Pezhman Alavi Nejad, Research Institute for Infectious Diseases of the Digestive System, School of Medicine, Ahvaz Jundishapur University of Medical Sciences, Ahvaz, Iran.

Email: pezhmanalavinejad@gmail.com

Telephone: +989161115880

Received: December 23, 2013 Revised: February 8, 2013

Accepted: February 15, 2013

Published online: March 21, 2014

ABSTRACT

AIM: Liver biopsy (LB) – considered as the “gold standard” in evaluation of patients with chronic liver disease but it is an invasive procedure so noninvasive methods are needed to identify clinically significant fibrosis. This study was performed to compare the liver stiffness (LS) measurement by transient elastography (TE) with liver biopsy.

METHODS: We performed a cross-sectional study that included a 102 consecutive patients with chronic liver disease in which LB and LS assessments (by means of TE) were performed. In all subjects, liver stiffness was measured by an experienced physician using a FibroScanR device (EchoSens, France) with standard protocol. We excluded patients for whom the successful rate (SR) of liver stiffness measurements (LSM) was < 60% and those who had measurements with an IQR >30%. LSM results were compared with liver biopsy results.

RESULTS: Overall 102 patients were analyzed: 12 with HCV, 57

with HBV, 17 with Autoimmune Hepatitis and 16 cases with NASH. The median age of patients with reliable LSM was 42.8 years (range 13-61). The distribution of patients in different fibrosis stages was: 0 ($n=40$), 1 ($n=22$), 2 ($n=16$), 3 ($n=4$), 4 ($n=11$), 5 ($n=6$), 6 ($n=3$). Fibrosis stage was significantly associated with LSM ($p=0.0003$). The median AST, ALT values were: 42 IU/L (15-173) and 53 IU/L (10-211) respectively. The mean LSM was 9.38 ± 2.3 kPa (Range 2.9-65). LSM was significantly associated and concordant with stage of fibrosis.

CONCLUSION: LSM in chronic liver disease patients correlates with fibrosis stages. A cut-off of 6.74 kPa can differentiate between significant fibrosis and absent or mild fibrosis, with PPV of 98%, NPV of 40.2%, sensitivity of 60.6%, specificity of 92.3%, and a diagnostic performance of 76.2%.

© 2014 ACT. All rights reserved.

Key words: Transient elastography; FibroScan; Liver biopsy; Liver stiffness

Hajiani E, Hashemi SJ, Masjedizadeh AR, Shayesteh AA, Alavi Nejad P, Kadkhodae A, Jalalvand K. Comparison of Liver Biopsy with Transient Elastography as a Non-invasive Method for Assessment of Liver Fibrosis. *Journal of Gastroenterology and Hepatology Research* 2014; 3(2): 1013-1016 Available from: URL: <http://www.ghrnet.org/index.php/joghr/article/view/625>

INTRODUCTION

For different causes of chronic liver disease, assessment of liver fibrosis is important to estimate the prognosis and to determine surveillance strategies for liver cancer. Historically, liver biopsy (LB) was the only method of determining hepatic fibrosis. However, it is an invasive method associated with patient discomfort and in rare cases serious complications^[1]. In addition, the accuracy of liver biopsy is limited due to sampling error and significant intra- and inter-observer variability in histological staging^[2]. Nevertheless its well-acknowledged limitations have led to the search for alternative, non-invasive methods for fibrosis assessment, including clinical and serum biomarker algorithms and the transient elastography (TE)

measured with the FibroScan device^[3,4].

TE is an ultrasound-based method. By using an ultrasound transducer probe mounted on the axis of a vibrator, the transmission of low-frequency vibrations from the right intercostal space creates an elastic shear wave that propagates into the liver. A pulse-echo ultrasound acquisition is then used to detect the velocity of wave propagation. This velocity is proportional to the liver stiffness, faster wave progression occurring through stiffer tissues. Measurement of liver stiffness (LS) is then performed and measured in kPa^[5].

The aim of the present study is to assess and compare the results of transient elastography (TE) as a non-invasive test and the liver biopsy, as a reference method in patients with chronic liver disease.

MATERIALS AND METHODS

The study period for sample acquisition was from September 2010 to September 2012 and a total of 102 consecutive patients who referred to the Ahwaz Jundishapur University Hospitals (AJSUH) and Hepatitis Clinic with chronic liver disease who received a liver biopsy and transient elastography were included in the study. Patients with decompensated liver cirrhosis (ascites, jaundice, esophageal varices) were excluded from the study as were patients who had hepatocellular carcinoma. A mean time interval between liver biopsy and performing of transient elastography (TE) of up to 12 months was accepted for enrollment in the present study. The indication of liver biopsy was determination of histological fibrosis and inflammation. Written informed consents were obtained from all patients before participating in the study.

Liver biopsies were performed by an experienced physician at the right section of the right lobe with a 16-gauge Menghini biopsy needle. Specimens were stained with haematoxylin and eosin (H&E) and argyrophilia and examined by an expert liver pathologist unaware of the patients' transient elastography (TE) results. The biopsies were judged as adequate, if the number of portal tracts and the length of liver specimen was at least 6 and 1 cm respectively. The mean length of the included liver biopsies was 22.3±9.3 mm (median 20 mm, range 10-54 mm). Fibrosis was staged on a 0-6 scale: F0-no fibrosis; F1- Fibrous expansion of some portal areas, with or without short fibrous septa; F2- Fibrous expansion of most portal areas, with or without short fibrous septa; F3- Fibrous expansion of most portal areas with occasional portal to portal bridging; F4- Fibrous expansion of portal areas with marked bridging; F5- Marked bridging with occasional nodules and F6- Cirrhosis, probable or definite^[6].

The liver stiffness (LS) was evaluated by means of Transient Elastography (TE) using FibroScan® (Echosens, France). This machine is equipped with a probe including an ultrasonic transducer mounted on the axis of a vibrator. A vibration transmitted from the vibrator towards the tissue induces an elastic shear wave that propagates through the tissue. These propagations are followed by pulse-echo ultrasound acquisitions and their velocity is measured which is directly related to tissue stiffness. Results are expressed in kilopascal. Details have been described in previous studies^[7]. The examination was performed on the right lobe of the liver through the intercostals space. After determination of the area of measurement, the tip of the transducer was covered with coupling gel and placed on the skin; the examiner pressed the button of the probe to start the acquisition. The measurement depth was between 25 and 65 mm free of large vascular structures. As suggested by the manufacturer, ten successful acquisitions were performed on each patient. Only TE-results obtained with 10 valid measurements, with a success-rate of at least 60% and an interquartile range ≤30% were considered reliable. FibroScan failure is defined when less than 10 valid measurements

were obtained.

The statistical analysis was performed using Microsoft Excel program. For the statistical study of quantitative variables, the mean and standard variations were calculated.

Table 1 Patient's characteristics.

Characteristics	Patients (n=102)
Sex:	71 male/31 female patients
Age:	Mean :42.8years (range 13-61)
AST:	42 IU/L (range 15-173)
ALT:	53 IU/L (10-211)

Table 2 Liver stiffness based on stage of fibrosis.

Histological Fibrosis stage	Patients (n=102)	Mean LSM/ Kpa
F0	40	6.7
F1	22	6.42
F2	16	11.3
F3	4	15.1
F4	11	17.3
F5	6	17.6
F6	3	15.9
Total	102	mean LSM was 9.38±2.3 Kpa

RESULTS

In this study overall 112 cases were analyzed [10patients were excluded because of unreliable TE measurements (less than 10 valid measurements, success rate <60%, or IQR >30%)], the remaining 102 cases included 12 with HCV, 57 with HBV, 17 with Autoimmune Hepatitis and 16 cases with NASH. 31 patients were women and 71 were men, with a mean age of 42.8 years (range 13-61). The distribution of patients in different fibrosis stages was: 0 (n=40), 1 (n=22), 2 (n=16), 3 (n=4), 4 (n=11), 5 (n=6), 6 (n=3). The mean LSM was 9.38±2.3 kPa (Range 2.9-65). We divided patients according to the degree of fibrosis, into a subgroup with significant fibrosis (F≥2) and another one with no or mild fibrosis (F<2).

The mean value of LS in patients with significant fibrosis (40 patients with F≥2) was 11.3 kPa, significantly higher than in patients with no or mild fibrosis (62 patients with F<2); 6.7 kPa (P=0.0003).

The values of LS in various subgroups of patients, divided according to fibrosis stage, were: 6.7 kPa in 40 patients with F0; 6.42 kPa in 22 cases with F1; 11.3 kPa in 16 patients with F2; 15.1 kPa in 4 cases with F3; 17.3 kPa in 11 cases with F4, 17.6 kPa in 6 cases with F5, and 15.9 kPa in 3 cases with F6 (Table 2).

The statistical significance of the differences between the LS in these subgroups was: F0-2 vs F3-6 P=0.0003. The statistical analysis of these subgroups showed that there were no significant differences between the mean values of LS in the F0 vs F1 and F5 vs F6 subgroup (so that these stages cannot be differentiated by means of FibroScan evaluation of LS).

The median AST, ALT values were: 42 IU/L (15-173); 53 IU/L (10-211); respectively. The mean LSM was 9.38±2.3 kPa (Range 2.9-65). LSM was significantly associated with stage of fibrosis (Figure 1).

A cut-off of 6.74 kPa can differentiate between significant fibrosis and absent or mild fibrosis, with a PPV of 98%, NPV of 40.2%, sensitivity of 60.6%, specificity of 92.3%, and a diagnostic performance of 76.2%.

DISCUSSION

Our study assessed the performance of TE in chronic liver disease patients by using liver biopsy (LB) as the reference standard. For different causes of chronic liver disease precisely evaluation of liver fibrosis is important to estimate the prognosis and to determine

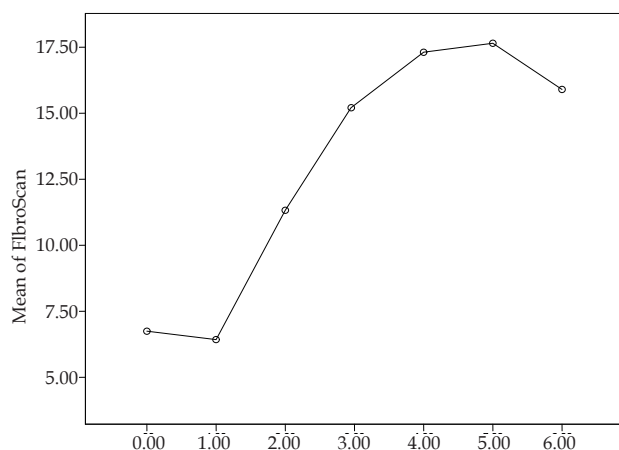


Figure 1 Mean values of LS in subjects with different fibrosis stages.

surveillance strategies for liver cancer. Currently, the biopsy examination of the liver is considered the optimal method to evaluate changes in fibrosis over time^[9]. Nevertheless, the liver biopsy (LB) has its shortcomings so TE as a noninvasive methods for the evaluation of liver fibrosis have been developed during the last few years in order to replace the LB.

The results of the present study for transient elastography and LB are in accordance with the results of previous studies^[10]. Some studies have been published regarding the upper limit of normal LS values^[11]. In a Korean study^[12], the cut off values were 7.3 kPa for $F \geq 2$, 8.8 kPa for $F \geq 3$ and 15.1 kPa for $F=4$. In another study using a cutoff value of 7.1 kPa, 88% of the patients who did not have significant fibrosis ($F < 2$ Metavir) were correctly identified^[13]. In our study a cut-off value of 6.7 kPa could differentiate between significant fibrosis and absent or mild fibrosis with a PPV of 98% and a NPV of 40.2%.

Beaugrand *et al* evaluated patients infected with HCV, who were assessed in the same session by means of percutaneous LB and valid FibroScan, and a significant correlation was found ($P < 0.0001$) between the LS and histological fibrosis, with AUROC [confidence interval (CI) 95%] 0.84, 0.93 and 0.96 for $F \geq 2$, $F \geq 3$ and $F=4$, respectively. This study tried to establish cut-off values in order to differentiate among various histological stages. Thus, a cut-off value of 7.5 kPa differentiates F0, 1/F2, 3, 4 with a sensitivity of 67%, a specificity of 87%, PPV of 86% and a NPV of 68%, with 76% diagnostic accuracy^[14].

Marcellin *et al* showed that in patients infected with HBV, LSM was significantly ($P < 0.001$) correlated with Ishak fibrosis stage (0.65). The area under receiver operating characteristic curves were 0.81 for $F > 2$, 0.93 for $F > 3$ and 0.93 for $F=4$. Optimal LSM cut-off values were 7.2 and 11.0 kPa for $F > 2$ and $F=4$ respectively^[15].

A recent study reported that TE measurement accurately predicts the absence or presence of significant fibrosis, or cirrhosis in 202 cases infected with HBV and was comparable to that observed in HCV patients^[16]. Considering the data presented from our study, the cut-off value of 6.7 kPa is the most accurate for discrimination between absence or mild fibrosis ($F < 2$) and the presence of moderate or severe fibrosis ($F \geq 2$). The cut-off value of 6.7 kPa in our study had a PPV of 98%, meaning that we can identify quite accurately the patients who should be treated ($F \geq 2$).

For patients with values of LS less than 6.7 kPa, the NVP is low (40.2%), we might miss patients with significant fibrosis using only TE.

In conclusion, TE is a new, rapid and noninvasive method of fibrosis assessment that offers specialists a new way of supervising

patients who are suffering from chronic liver diseases. TE provides a quantitative operator-independent measurement of liver stiffness. The best known contributor to liver stiffness is the amount of fibrosis. Our study like most other studies, show that, by using a cut-off value of 6.7 kPa, we could identify the patients with advanced fibrosis ($F \geq 2$) vs those who have non-significant fibrosis ($F < 2$) with enough accuracy and without performing a LB. TE can reliably exclude cirrhosis offering a useful tool in the clinical assessment of chronic liver disease patients. However, current findings do not support the replacement of liver biopsy in routine clinical practice. But, TE has the potential to provide much more information than just an assessment of fibrosis, and specialists must put the elastographic results in perspective with the rest of their clinical findings.

ACKNOWLEDGMENTS

This study was funded by the Research Institute for Infectious Diseases of the Digestive System, Ahvaz Jundishapur University of Medical Sciences, Ahvaz, Iran.

REFERENCES

- 1 Castera L, Negre I, Samii K, Buffet C. Pain experienced during percutaneous liver biopsy. *Hepatology* 1999; **30**:1529-1530
- 2 Bedossa P, Dargere D, Paradise V. Sampling variability of liver fibrosis in chronic hepatitis C. *Hepatology* 2003; **38**:1449-1457
- 3 Talwalkar JA, Kurtz DM, Schoenleber SJ, West CP, Montori VM. Ultrasound-based transient elastography for the detection of hepatic fibrosis: systematic review and metaanalysis. *Clin Gastroenterol Hepatol* 2007; **5**: 1214-1220
- 4 Rockey DC. Noninvasive assessment of liver fibrosis and portal hypertension with transient elastography. *Gastroenterology* 2008; **134**: 8-14
- 5 Adhoute X, Foucher J, Laharie D, Terreboune E, Vergnol J, Castéra L, Lovato B, Chanteloup E, Merrouche W, Couzigou P, de Ledinghen V. Diagnosis of liver fibrosis using FibroScan and other noninvasive methods in patients with hemochromatosis: a prospective study. *Gastroenterol Clin Biol* 2008; **32**: 180-187
- 6 Ishak K, Baptista A, Bianchi L, *et al*. Histologic grading and staging of chronic hepatitis. *J Hepatol* 1995; **24**: 289-293
- 7 Sandrin L, Fourquet B, Hasquenoph JM, Yon S, Fournier C, Mal F, *et al*: Transient elastography: a new non-invasive method for assessment of hepatic fibrosis. *Ultrasound Med Biol* 2003; **29**: 1705-1713
- 8 Poynard T, Halfon P, Castera L, Munteanu M, Imbert-Bismut F, Ratziu V, Benhamou Y, Bourliere M, de LV: Standardization of ROC Curve Areas for Diagnostic Evaluation of Liver Fibrosis Markers Based on Prevalences of Fibrosis Stages. *Clin Chem* 2007; **53**: 1615-1622
- 9 McHutchison J, Poynard T, Afdhal N. Fibrosis as an end point for clinical trials in liver disease: a report of the international fibrosis group. *Clin Gastroenterol Hepatol* 2006; **4**: 1214-1220
- 10 Friedrich-Rust M, Ong MF, Martens S, Sarrazin C, Bojunga J, Zeuzem S, Herrmann E: Performance of transient elastography for the staging of liver fibrosis: a meta-analysis. *Gastroenterology* 2008; **134**: 960-974
- 11 Fraquelli M, Rigamonti C, Casazza G, Conte D, Donato MF, Ronchi G, *et al*. Reproducibility of transient elastography in the evaluation of liver fibrosis in patients with chronic liver disease. *Gut* 2007; **56**(7): 968- 973
- 12 Kim KM, Choi WB, Park SH, Yu E, Lee SG, Lim YS, Lee HC, Chung YH, Lee YS, Suh DJ. Diagnosis of hepatic steatosis and fibrosis by transient elastography in asymptomatic healthy individuals: a prospective study of living related

- potential liver donors. *J Gastroenterol* 2007; **42**: 382-388
- 13 Berends MA, Snoek J, de Jong EM, Van Krieken JH, de Kneegt RJ, van Oijen MG, van de Kerkhof PC, Drenth JP. Biochemical and biophysical assessment of MTX-induced liver fibrosis in psoriasis patients: Fibrotest predicts the presence and Fibroscan predicts the absence of significant liver fibrosis. *Liver Int* 2007; **27**: 639-645
 - 14 Ziol M, Marcellin P, Douvin C, de Ledinghen V, Poupon R, Beaugrand M. Liver stiffness cut off values in HCV patients: validation and comparison in an independent population. *Hepatology* 2006; **44**: **Suppl 1**: 269A
 - 15 Marcellin P, Ziol M, Bedossa P, Douvin C, Poupon R, de Léd-
inghen V, Beaugrand M. Non-invasive assessment of liver
fibrosis by stiffness measurement in patients with chronic
hepatitis B. *Liver Int* 2009; **29**: 242-247
 - 16 Cardoso AC, Carvalho-Filho RJ, Stern C, Dipumpo A, Giully
N, Ripault MP, Asselah T, Boyer N, Lada O, Castelnau C,
Martinot-Peignoux M, Valla DC, Bedossa P, Marcellin P. Di-
rect comparison of diagnostic performance of transient elas-
tography in patients with chronic hepatitis B and chronic
hepatitis C. *Liver Int* 2011; **32**: 612-621

Peer reviewer: Yoshihiro Kamada, Department of Gastroenterology and Hepatology, Osaka University, Graduate School of Medicine, 2-2, K1, Yamada-oka, Suita, Osaka 565-0871, Japan.