

Aberrant Splenic Artery: Case Report of Splenic Artery originating from Superior Mesenteric Artery

Doua Elamin, Haytham El-Salhat, Omar Bekdache

Doua Elamin, Haytham El-Salhat, Omar Bekdache, Division of General Surgery, Department of Surgery. Tawam Hospital, Al Ain, United Arab Emirates

Correspondence to: Omar Bekdache, MD, FRCS, FACS, Division of General Surgery, Department of Surgery. Tawam Hospital, Al Ain, United Arab Emirates

Email: obekdache@tawamhospital.ae

Telephone: +97137677444 Fax: +97137072894

Received: October 8, 2013 Revised: November 8, 2013

Accepted: November 15, 2013

Published online: March 21, 2014

ABSTRACT

The splenic artery is a relative constant branch of the celiac artery. The celiac trunk arises from the abdominal aorta and after a short course divides into the left gastric, common hepatic and splenic arteries. Aberrances describing the gastric and the hepatic branches are quite common but aberrances in the origin of the splenic artery are rarely seen. We present a case where the splenic artery does not follow the normal course; instead, it arises from the Superior Mesenteric Artery which arises from the anterior surface of the aorta below the celiac artery at the level of the first lumbar vertebra. A review of the frequency of this anomaly is also described.

© 2014 ACT. All rights reserved.

Key words: Aberrant splenic artery; Splenomesenteric trunk; Superior Mesenteric Artery; Celiac trunk/axis

Elamin D, El-Salhat H, Bekdache O. Aberrant Splenic Artery: Case Report of Splenic Artery originating from Superior Mesenteric Artery. *Journal of Gastroenterology and Hepatology Research* 2014; 3(3): 1017-1018 Available from: URL: <http://www.ghrnet.org/index.php/joghr/article/view/626>

INTRODUCTION

The splenic artery is known to be the largest branch of the celiac trunk with distribution to the spleen, pancreas, stomach and greater omentum. However, variations to this anatomy and origin can occur.

An aberrant splenic artery arising from the superior mesenteric artery is known as the splenomesenteric trunk and it occurs in less than 1% of patients^[1].

CASE REPORT

A 47 year old male physician known to be diabetic and hypertensive was admitted complaining of epigastric pain, bloody diarrhea and weight loss of 10 kilograms over 2 months. A large ulcerated bleeding duodenal mass was found on EGD. Abdominal CT scan showed the mass to be encasing the second and third parts of the duodenum and adherent to the transverse colon, pylorus of the stomach, head of pancreas and a short segment of the jejunum (Figure 1). Biopsy confirmed the diagnosis of large B cell lymphoma. An interesting, exceptional anomaly was also noticed while interpreting the imaging. An aberrant splenic artery originating directly from the Superior Mesenteric Artery was seen (Figure 2, 3). This was further appreciated and helped in our surgical management

Aberrances of the splenic artery were documented in few studies.

In India, dissection of 50 cadavers to study the celiac trunk and its branches revealed that in 86% of cadavers, the left gastric, common hepatic and splenic arteries arise from the celiac trunk. In one case, all three branches arose directly from the abdominal aorta, and the origin of the splenic artery was 1 cm distal to the origin of the left gastric and common hepatic arteries^[2]. Another reported variation was seen in a 62 year old male cadaver, where a gastroduodenal-splenic trunk was found to give rise to the splenic and gastroduodenal arteries^[3].

A similar case to our currently described case was reported in 2011 where the splenic and hepatic arteries arose directly from the superior mesenteric artery in a 66 year old man with complete agenesis of the celiac axis^[4]. Another case with absence of the celiac axis was described when dissecting a 95 year old male Japanese cadaver. The left gastric, splenic, common hepatic and superior mesenteric arteries arose independently from the abdominal aorta^[5].

CONCLUSION

The specificity of our case comes from the fact that the splenic artery originates from the superior mesenteric artery with a preserved celiac trunk in contradistinction to the agenesis or absence of the celiac axis like otherwise reported.

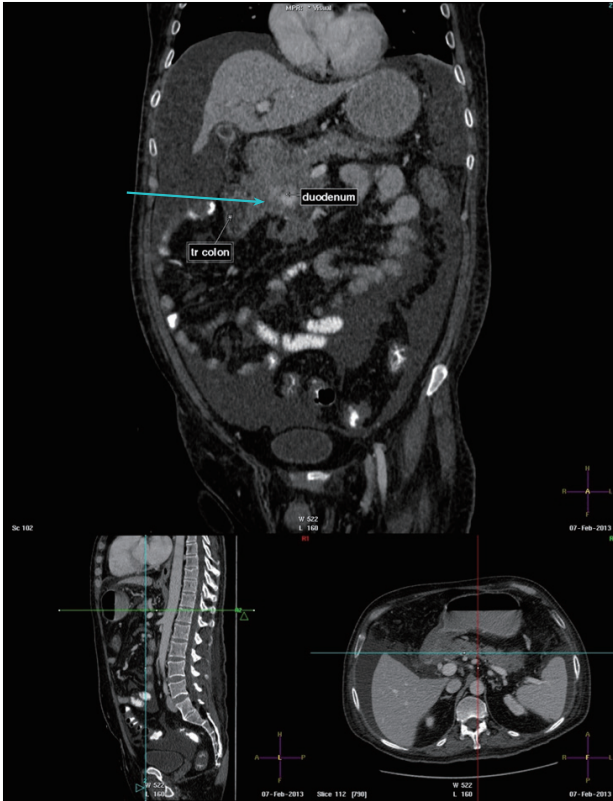

Figure 1 Abdominal CT scan; Mass encasing second and third parts of the duodenum adherent to the transverse colon, pylorus of the stomach, head of the pancreas and short segment of the jejunum.

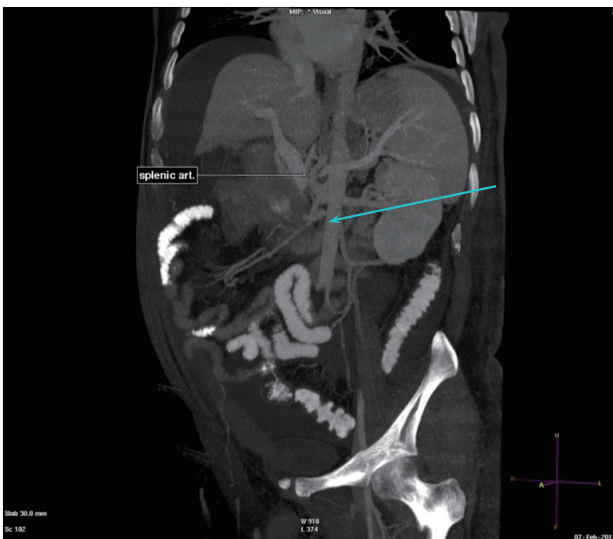


Figure 2 Aberrant splenic artery originating from the Superior Mesenteric Artery.

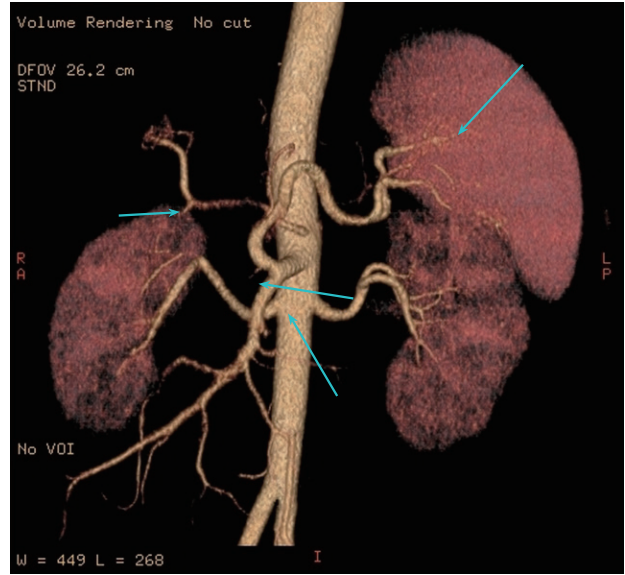


Figure 3 Aberrant splenic artery originating from the Superior Mesenteric Artery.

Exploring these variations is important especially if surgical intervention is contemplated. This could greatly affect the surgical planning and avoid injuries to major arteries and organs intraoperatively.

REFERENCES

- 1 Sato M, Anno I, Yamaguchi M, Iida H, Orii K. Splenic artery aneurysm of the anomalous splenomesenteric trunk: successful treatment by transcatheter embolization using detachable coils. *Cardiovascular and interventional radiology* 2006; **29**: 432-434
- 2 Prakash, Rajini T, Mokhasi V, Geethanjali BS, Sivacharan PV, Shashirekha M. Coeliac trunk and its branches: anatomical variations and clinical implications. *Singapore medical journal* 2012; **53**: 329-331
- 3 Li J, Ren ZF. Gastroduodenal-splenic trunk: an anatomical vascular variant. *Romanian journal of morphology and embryology= Revue roumaine de morphologie et embryologie* 2011; **52**: 1385
- 4 Bharath A, Rao N, Dunn W, Lobo DN. Gastrointestinal: Absent coeliac axis. *Journal of gastroenterology and hepatology* 2011; **26**: 932-932
- 5 Yi SQ1, Terayama H, Naito M, Hirai S, Alimujang S, Yi N, Tanaka S, Itoh M. Absence of the celiac trunk: case report and review of the literature. *Clinical Anatomy* 2008; **21**: 283-286

Peer reviewers: Yuedong Wang, MD, PhD, FACS, Department of Laparoscopic and Gastrointestinal Surgery, Second Affiliated Hospital of Zhejiang University School of Medicine, 88JiefangRD., Hangzhou310009, China; Vikram Kate, Professor of General & Gastrointestinal Surgery, Jawaharlal Institute of Postgraduate Medical Education & Research (JIPMER), Pondicherry-605006, India.