

Evaluation of Portal Hypertensive Doppler Parameters in Patients with Bilharzial Periportal Fibrosis

Hasan Sedeek Mahmoud, Seham F Ahmed, Mohamed A Al-Senbesy

Hasan S Mahmoud, Department of Tropical Medicine and Gastroenterology, Qena Faculty of Medicine, South Valley University, Egypt

Seham F Ahmed, Mohamed A Al-Senbesy, Department of Internal Medicine, Qena Faculty of Medicine, South Valley University, Egypt

Correspondence to: Hasan Sedeek Mahmoud, Department of Tropical Medicine and Gastroenterology, Qena Faculty of Medicine, South Valley University, Egypt.

Email: hasan_sedeek@yahoo.com

Telephone: +20-1061648665

Fax: +20-965337571

Received: December 29, 2013

Revised: February 4, 2014

Accepted: February 10, 2014

Published online: April 21, 2014

patients than control, also in patients with thick than those with fine PPF (P value=0.000).

CONCLUSION: Color Doppler portal hypertensive parameters are significantly higher in patients with more advanced bilharzial periportal fibrosis.

© 2014 ACT. All rights reserved.

Key words: Bilharzial Periportal Fibrosis; Portal Hypertensive; Doppler US

Mahmoud HS, Ahmed SF, Al-Senbesy MA. Evaluation of Portal Hypertensive Doppler Parameters in Patients with Bilharzial Periportal Fibrosis. *Journal of Gastroenterology and Hepatology Research* 2014; 3(4): 1024-1029 Available from: URL: <http://www.ghrnet.org/index.php/joghr/article/view/655>

ABSTRACT

AIM: The current study aimed to evaluate sonographic and Doppler portal hypertensive parameters in patients with hepatic periportal fibrosis; either with mild or advanced disease, and to assess if there are any correlations between these parameters.

METHODS: This case/control study included 50 patients; 44 males and 6 females and 40 subjects as a control group. Diagnosis of bilharziasis was established by history, examination and investigations. Patients were classified into patients with fine and thick periportal fibrosis (PPF) by abdominal US. All included subjects underwent hepatosplenic Color Doppler Ultrasonographic examination.

RESULTS: 50 patients with their mean age 34 ± 9 years were included. No statistically significant differences in portal vein diameter (PVD), portal vein velocity (PVV) and portal vein flow volume (PVFV) between patients and control. Patients with thick PPF showed statistically significant higher values in PVD (P value=0.001) and PVFV (P value=0.05) than those with fine PPF. Congestion index of the portal vein (CI) was significantly higher in patients than control (P value=0.001), also in patients with thick than those with fine PPF (P value=0.000). Statistically significant higher values of splenic vein diameter (SVD) (P value=0.026), splenic Index (SI), splenoportal index (SPI) (P value=0.000) were detected in

INTRODUCTION

Schistosomiasis (Bilharzias) is the third-leading endemic parasitic disease in the world, following malaria and amebiasis^[1]. The estimated number of individuals infected is about 200 million^[2]. There are three major species that cause tremendous human morbidity, *Schistosoma haematobium* and *Schistosoma mansoni* predominantly in Africa, and *Schistosoma japonicum* in the Far East. Schistosomiasis can cause a wide range of symptoms and consequences depending on the species, the worm burden and the length of time infected^[3].

Chronic Schistosomiasis is characterized by a series of chronic inflammatory lesions produced in and around blood vessels by the eggs or their product^[4]. The chronic manifestations in *S. japonicum* and *S. mansoni* infestations are characterized by hepatosplenomegaly, although development of polyps or mucosal proliferation of the intestine may also be observed in most cases. Egg granulomas are replaced by fibrotic tissues, which are prominent in the periportal areas and lead to the development of pipestem fibrosis^[5].

Hepatosplenic Schistosomiasis is the major complication of chronic infestation with *S. mansoni* and *S. japonicum*. Hepatosplenic schistosomiasis is usually, but not invariably, associated with enlargement of the liver and spleen, and reversible

hepatosplenomegaly may occur in early infestations not complicated by the development of portal hypertension^[6].

The portal hypertension of schistosomiasis is intra-hepatic and presumably related to the portal zone reaction^[7]. In advanced schistosomiasis, hepatic arterial hypertension contributes to increased sinusoidal pressure^[8].

The diagnosis may be confirmed by the finding of eggs in stool (Kato-Katz method)^[9] or biopsy specimens, by the presence of circulating antischistosomal antibodies, and by a positive intradermal reaction^[10]. But most of these methods are time-consuming, lack sensitivity or specificity, and, therefore, are not suitable for large field studies^[11]. Abdominal ultrasonography is among the most valuable diagnostic tool for schistosomiasis-related organ lesions in endemic regions^[12]. It has been used as a reliable and reproducible technique for identifying and grading morphological changes associated with Symmers' pipestem periportal fibrosis and for assessing the efficacy of antiparasitic chemotherapy^[13].

Non-invasive method of assessing portal hemodynamics, namely duplex-Doppler ultrasonography (USG), has produced a large amount of data on blood velocity and flow in portal vein^[14]. It allows the identification of a number of parameters related to the presence of portal hypertension, these are increase in portal vein diameter, lack of respiratory change in portal, splenic and mesenteric veins diameter, presence of portal-collateral circulation, decreased or reversed portal vein velocity, increased congestion index of the portal vein and presence of ascites and splenomegaly^[15].

METHODS

A case control study was conducted on patients with bilharzial periportal fibrosis who were admitted to Internal Medicine and Tropical Medicine and Gastroenterology departments at Qena University Hospital from March 2012 to January 2013. Ninety subjects (80 males and 10 females) were recruited; fifty were bilharzial patients and forty as control. Patients were classified according to the degree of periportal fibrosis by abdominal ultrasonography into patients with fine and thick periportal fibrosis.

I- Inclusion criteria: All included patients were bilharzial and they should have the following criteria: Previous history of antibilharzial therapy, positive antibilharzial antibodies, positive rectal snip and bilharzial PPF by abdominal ultrasonography.

II- Exclusion criteria: Patients excluded if they have any of the following: patient with non bilharzial liver diseases, patients with massive ascites, hepatic malignancy and portal vein thrombosis, patient with advanced age, comorbidity, previous history of alcoholism, positive serology for hepatitis B or C viruses, previous history of proven autoimmune disease, splenectomized patients, irregular use of beta-blocker drugs (propranolol), the use of hepatotoxic drugs and refusal to participate in the study.

III- All selected subjects underwent: (A) Clinical history and examination; (B) Laboratory investigations; including: Urine analysis, stool analysis, liver function tests: ALT, AST, serum albumin, total bilirubin, prothrombin time and prothrombin concentration; (C) Abdominal ultrasonography was done for all subjects for detecting the following data: (1) Liver size: measured as the span of the right lobe in mid-clavicular line on oblique view and classified as shrunken (<11 cm), average (11-15 cm), or enlarged (> 15 cm)^[16]. (2) Presence of hepatic PPF; whether it is fine or thick^[17]. We graded PPF as grades 0-III. Grade 0 corresponds to normal liver with no thickening of the peripheral portal branch (PPB) wall and PPB diameters (outer to outer) about 2-3 mm. Grade I corresponds to a pattern of small stretches of fibrosis around secondary portal

branches (this patchy fibrosis usually has a "fishes in the pond" appearance) and PPB diameters about 4 mm (fine, mild). Grade II still shows the patchy fibrosis observed in early mild fibrosis, but a continuous fibrosis affects most second-order branches, and PPBs appear as long segments of fibrosis. PPB diameter is about 5-6 mm. In 30% of cases, the thickness of the gallbladder wall is increased (2-4 mm). Grade III shows a thickening of the walls of most PPBs, some branches are occluded, and the long segment of the fibrosis reaches the surface of the liver (thick, advanced). (3) Portal vein diameter and patency: The normal PV is up to 13mm in diameter. It was measured from the inner to the inner wall during suspended respiration^[18]. (4) Splenic size: Measured in a coronal plane. The size of the spleen was classified according to its longest axis which was measured from upper to lower pole. Normally, it is up to 12-13 cm. If enlarged, it is classified as mild (13-16 cm), moderate (16-20 cm), or huge (>20 cm) splenomegaly^[17]. (5) Status of ascites: if present, it was reported as either minimal ascites (in hepatorenal pouch, peri-hepatic area or supravescical area) or moderate to severe ascites. (6) Criteria suggestive of portal hypertension by ultrasonography are an increased diameter of the portal and splenic veins, the presence of portosystemic collaterals, splenomegaly and ascites^[19]. (D) Hepatic Doppler US was done for all subjects as follow: All patients were examined after an overnight fasting, using a color Doppler unit (Toshiba TA311 Japan real-time scanner instrument with a 3.5 MHz convex probe). The reported values of the Doppler parameters were obtained by taking the average value of 3 consecutive measurements^[20]. The following data were reported: 1-Portal vein: Confirmation of the portal vein patency and measuring portal vein diameter, portal vein cross sectional area (CSA), mean portal vein flow velocity (mean PVV) (cm/s)=maximal PV flow velocity $\times 0.57^{[21]}$, which was calculated automatically by the device, portal vein flow volume (mL/min)=portal vein mean flow velocity multiplied by the cross sectional area of the portal vein^[22]. 2- Portal vein congestive index (CI) (cm/s)=the ratio of PV cross-sectional area (cm²) to mean PV flow velocity (cm/s)^[23]. 3- Hepatic artery including hepatic artery pulsatility index (HAPI) and hepatic artery resistance index (HARI). 4- Liver vascular index (cm/s): The ratio of the portal vein velocity (PVV) and hepatic artery pulsatility index (PI). The best cutoff value of LVI was 12 cm/sec^[24]. 5- Splenic vein diameter: The normal splenic vein diameter is usually less than 10 mm^[25]. 6- Splenic Index (SI): The splenic index (SI) was calculated in square centimeters with the following formula: $SI = a \cdot b$, where a is the transverse diameter in centimeters and b is the vertical diameter in centimeters of the maximal cross-sectional images of the spleen^[26]. 7- Splenoportal Index (SPI): The SPI, obtained in centimeters times seconds with the following formula: $SPI = SI/PVV_{mean}^{[27]}$.

Statistical analysis

Data entry and analysis were done using statistical package of social science (SPSS) version 16. The data are presented as means \pm SD. Statistical methods included independent-t-tests; used for comparison between the two groups in case of continuous variables and the Chi-square test for comparison between categorical variables. Correlations between variables were done using Pearson Correlation.

RESULTS

The demographic data for the studied groups were illustrated in table 1 and they were matched for age and sex. Patients were classified according to the degree of PPF by abdominal ultrasonography into subgroup (a) patients with fine PPF 40 (80%) and subgroup (b) patients with thick PPF 10 (20%). Past history of bilharzias

as, history of swimming in canals in 40 patients (80%), history of terminal hematuria in 4 patients (8%), and history of dysentery in 8 patients (16%), antibilharzial therapy was found in 26 patients (52%). Clinically, there were hepatomegally in 30 patients (60%) and splenomegally in 40 patients (80%).

No statistically significant differences were found in liver function tests between patients and control, while there were a significant lower values in prothrombin concentration and significant higher values in prothrombin time and total bilirubin in patients with thick PPF than those with fine PPF with no significant differences in liver enzymes and albumin in both patients' subgroups, this is illustrated in table 2.

Abdominal ultrasonography showed statistically significant higher values in liver size at midclavicular line and in splenic size in patients than control (*P* value=0.000) and also in patients with thick PPF than those with fine PPF (*P* value=0.003 and 0.000; respectively), this is illustrated in table 3.

Doppler hemodynamic parameters showed no statistically significant differences in portal vein diameter, portal vein velocity

Table 1 Demographic data for of both groups (patient and control).

Variable	Patients (n=50)	control (n=40)	P value
Age (ys)	34.24±9.68	33.9±9.23	NS
Sex			
Male, n (%)	44 (88%)	36 (90%)	NS
Female, n (%)	6 (12%)	4 (10%)	NS

Data are expressed as mean±SD or as number, (%). Chi² test was used in analysis NS: Non significant.

Table 2 Demographic data for of both groups (patient and control).

Variable	Patients (n=50)	Control (n=40)	P value	Fine (n=40)	Thick (n=10)	P value
ALT (U/L)	17.14±10.4	17.6±11.6	NS	15.5±5.4	16.01±5.2	NS
AST (U/L)	21.6±8.4	22.37±9.2	NS	20.6±5.2	25.4±9.15	NS
T. bilirubin (mg/dL)	0.562±0.136	0.55±0.130	NS	0.539±0.001	0.65±0.214	0.014
Albumin (g/dL)	4.22±0.33	4.19±0.32	NS	4.20±0.29	4.30±0.47	NS
Prothrombin time (s)	12.22±1.3	12.02±1.27	NS	11.80±0.68	13.9±1.8	0.000
Prothrombin conc. (%)	90.07±8.59	92.27±6.57	NS	92.92±4.59	78.68±11.42	0.000

Data are expressed as mean ± SD. Independent sample t test was used in analysis. NS= Non significant. *P* value<0.05 = significant.

Table 3 Liver and spleen size by abdominal ultrasonography in patients and control and in patients' subgroups.

Variable	Patients (n=50)	Control (n=40)	P value	Fine (n=40)	Thick (n=10)	P value
liver span in MCL (cm)	11.878±1.72	10.6±0.86	0.000	11.52±1.12	13.30±2.81	0.003
size of spleen (cm)	14.596±3.45	8.28±1.64	0.000	13.34±2.14	16.60±4.20	0.000

Data are expressed as mean ± SD or as number, (%). Independent sample t test was used in analysis. *P* value<0.05= significant. NS= Non significant. MCL: Midclavicular line.

Table 4 Doppler parameters of the portal vein and hepatic artery for patients and control and for patients' subgroups.

Variable	Patients (n=50)	Control (n=40)	P value	Fine (n=40)	Thick (n=10)	P value
PVD (mm)	10.958±2.49	10±1.27	NS	10.39±1.49	13.2±4.15	0.001
PVV (cm/s)	14.23±3.67	16.31±3.19	0.005	14.53±3.59	13±3.91	NS
PVfV (mL/min)	794.17±278	725.68±167	NS	755.67±242	948.15±367	0.05
CI (cm/s-1)	0.074±0.051	0.048±0.0127	0.001	0.062±0.019	0.125±0.098	0.000
HAPI	1.155±0.383	1.1019±0.119	NS	1.187±0.368	1.026±0.433	NS
HARI	0.687±0.127	0.685±0.07	NS	0.692±0.09	0.668±0.212	NS
LVI	13.44±4.9	15.002±3.5	NS	13.358±13.3	13.772±3.6	NS

Data are expressed as mean ± SD or as number, (%); Independent sample t test was used in analysis; NS=Non significant. *P* value<0.05= significant. PVD: Portal vein diameter; PVV: portal vein velocity; PVFV: portal vein flow volume. CI: congestion index; HAPI: hepatic artery pulsatility index; HARI: hepatic artery resistance index; LVI: Liver vascular index.

Table 5 Doppler parameters of the splenic vein, splenic Index and splenoportal Index for patients and control and for patients' subgroups.

Variable	Patients (n=50)	Control (n=40)	P value	Fine (n=40)	Thick (n=10)	P value
SVD(mm)	8.104±2.75	7.058±1.56	0.026	7.19±1.84	11.74±2.84	0.000
SI	61.67±37.55	29.03±11.09	0.000	47.03±12.61	120.23±47.15	0.000
SPI	4.88±4.34	1.79±0.623	0.000	3.38±1.158	10.89±6.84	0.000

Data are expressed as mean±SD or as number, (%). Independent sample t test was used in analysis. *P* value<0.05= significant, SVD: Splenic vein diameter; SI: Splenic index; SPI: Spleno-portal index.

and portal vein flow volume between patients and control while there were significant higher values in portal vein diameter (*P* value=0.001) and portal vein flow volume (*P* value=0.05) in patients with thick PPF than those with fine PPF with no significant differences in portal vein velocity. Congestion index showed statistically significant higher values in patients than control (*P* value=0.001) and also in patients with thick PPF than those with fine PPF (*P* value=0.000). On the other hand Liver vascular index showed no statistically significant differences between patients and control or between both patients' subgroups, this is illustrated in table 4.

Hepatic artery pulsatility index and hepatic artery resistance index showed no statistically significant differences between patients and control or between both patients' subgroups, this is illustrated in table 4.

Splenic doppler parameters showed significant higher values of splenic vein diameter (*P* value=0.026), SI, SPI in patients than control (*P* value=0.000) and also in patients with thick PPF than those with fine PPF (*P* value=0.000), this is illustrated in table 5.

Positive correlations were detected in patient group between congestion index of portal vein (CI) and splenic size (*r*=+0.669, *P* value=0.000), SI (*r*= +0.786, *P* value= 0.000) and SPI (*r*=+0.903, *P* value=0.000), (Figure 1, 2, 3).

DISCUSSION

Qena governorate, in Upper Egypt, has two main canals (Asfon and El- Esmailia) and many tributaries from them. Canals are the source of transmission of bilharziasis due to swimming in it. The prevalence

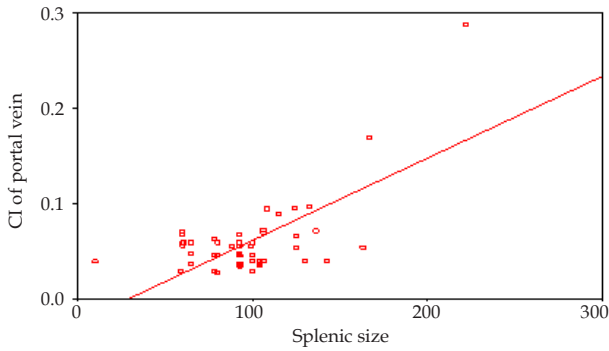


Figure 1 Correlation between splenic size and congestion index of portal vein (CI) in bilharzial patients ($r = +0.669$, P value=0.000).

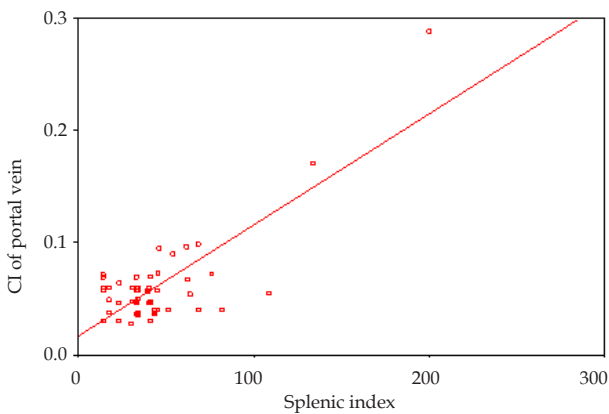


Figure 2 Correlation between splenic index (SI) and congestion index of portal vein (CI) in bilharzial patients ($r = +0.786$, P value=0.000).

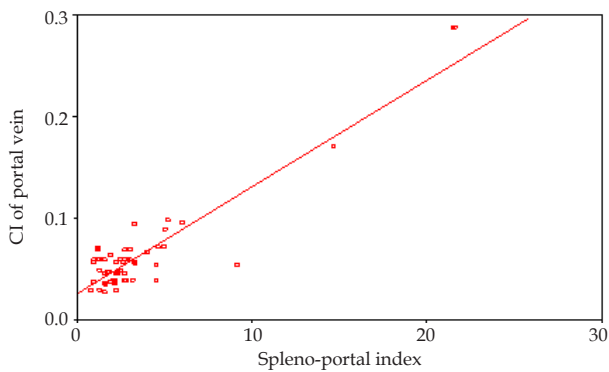


Figure 3 Correlation between splenoportal index (SPI) and congestion index of portal vein (CI) in bilharzial patients ($r = +0.903$, P value=0.000).

of schistosomiasis in Qena was 12% in 1988 and it decreased to be 1.4% in 2011 according to the recent report of (The Ministry of Health and Population in Qena, 2011). The prevalence of infection was slightly more in ezbas than in their mother villages. Prevalence and intensity of infection was higher at all ages in males than in females^[28].

Schistosomiasis can cause many complications including portal hypertension, pulmonary hypertension and oesophageal varices. Hepatosplenic schistosomiasis refers to the major complication of chronic infestation with *S. mansoni* and *S. japonicum*. Schistosomal portal hypertension is unique, with a distinct pathophysiology, different from cirrhotic and prehepatic causes^[29].

In the current study no statistically significant differences were found in liver function tests (total bilirubin, serum albumin, liver enzymes (ALT and AST), prothrombin time and concentration)

between patients and control. In patients' subgroups, patients with thick PPF showed statistically significant lower values in prothrombin concentration and statistically significant higher values in prothrombin and total bilirubin than those with fine PPF with no statistically significant differences in liver enzymes and albumin. Shakir *et al*^[30] (2010) reported that liver function is generally well preserved in schistosomiasis even after development of PPF and portal hypertension.

In the current study we found statistically significant higher values in liver size at midclavicular line and in splenic size in patients than control and also in patients with thick PPF than those with fine PPF. The same results were observed by De Cock^[31] (1986) as hepatosplenic schistosomiasis is usually, but not invariably, associated with enlargement of the liver and spleen, and reversible hepatosplenomegaly may occur in early infestations not complicated by the development of portal hypertension. Ibrahim *et al*^[32] (2009) reported that splenomegaly is a prominent feature of schistosomal portal hypertension. On the other hand Fernandes *et al*^[33] (2010) reported that the disease can develop even in the absence of manifest liver involvement. Mies^[34] (1992) reported that, there was extensive splenomegaly with dilated spleen vessels, suggesting that the splanchnic hyperflow is largely due to splenic hyperflux in schistosomal portal hypertension.

No statistically significant differences could be detected in portal vein diameter (PVD) and portal vein flow volume (PVFV) between patients and control but we found statistically significant lower values in portal vein velocity (PVV) between them. Patients with thick PPF showed statistically significant higher values in PVD and PVFV than those with fine PPF but no statistically significant differences could be detected in PVV. Chou *et al*^[35] (2003) reported that portal blood flow (PBF) remain unaffected in patients with schistosomiasis. On the contrary Kardorff^[36] (1999) reported that portal blood flow is decreased in patients with schistosomiasis as a consequence of increased portal vascular resistance. Martins *et al*^[37] (2000) reported that the reduced PBF in hepatosplenic schistosomiasis has been attributed both to an early stage of portal hypertension and to the presence of collaterals and of a reversed blood flow in the left gastric vein. On the other hand Vezozzo *et al*^[38] (2006) study has indicated that both hepatosplenic and hepatointestinal schistosomiasis have an increased PBF as assessed by doppler ultrasound, which was not observed in healthy individuals. Qurashi *et al*^[39] (1999) observed significant association between grades of PPF and PVD; as moderate and advanced fibrosis is associated with increased PVD.

The study of portal hemodynamics is very important for the understanding of the pathophysiology of portal hypertension in hepatosplenic mansonic schistosomiasis. Hemodynamic studies in schistosomal disease reveal a unique hyperdynamic circulatory syndrome characterized by marked increased cardiac index and decreased peripheral vascular resistance, splenic hyperflow, and reduced mesenteric blood flow, with mild increase in portal flow compared with the total hepatic blood flow^[40].

Also we detected that the congestion index had statistically significant higher values in patients than control also in patients with thick PPF than those with fine PPF. The use of congestion index was introduced by Moriyasu *et al*^[41] (1986). As the congestion index is affected by PV cross sectional area and the PV mean velocity, therefore, the increase in PV cross sectional area and the decrease in PV mean velocity result in increase of CI in portal hypertension. Sallam *et al*^[42] (1996) found that the congestion index of the portal vein was correlated with liver function, presence and size of varices and presence and degree of red signs.

In the current study, the doppler parameters of the spleen showed statistically significant higher values of splenic vein diameter (SVD), splenic Index (SI) and splenoportal Index (SPI) in patients than control and in patients with thick than those with fine PPF. Qurashi *et al.*^[39] (1999) reported that moderate and advanced fibrosis is associated with increased SVD and with splenomegaly. Bolognesi *et al.*^[27] (2002) reported that SPI is accurate in diagnosing the presence or absence of esophageal varices when the cutoff value is set at 3.0. By using the cutoff level, 92% of the patients could have been given correct diagnoses with this noninvasive index, without having to undergo invasive screening endoscopy. These results could be explained as portal hypertension increases splenic size and decreases the flow velocity of portal vein resulting in elevation in both SI and SPI.

CONCLUSION

Bilharzial periportal fibrosis still to be a health problem in Upper Egypt. Screening programs for detecting early stages is mandatory for treatment and avoiding such complications. Color Doppler portal hypertensive parameters are significantly higher in patients with more advanced bilharzial periportal fibrosis especially those of the splenic vein diameter, splenic index and splenoportal index. Those patients should be screened for esophageal and gastric varices for proper management.

CONFLICT OF INTERESTS

There are no conflicts of interest with regard to the present study.

REFERENCES

- 1 Gryseels B, Polman K, Clerinx J, Kestens L. Human Schistosomiasis. *Lancet* 2006; **368**: 1106–1118
- 2 Ross AG, Bartley PB, Sleight AC, Olds GR, Li Y, Williams GM, McManus DP. Schistosomiasis. *N Engl J Med* 2002; **346**: 1212–1220
- 3 Fenwick A and Zhang Y. Schistosomiasis. In *Infectious Diseases*. 3rd edition. Edited by Cohen J, Opal SM, Powderly WG. Amsterdam, the Netherlands: Elsevier; 2010.
- 4 Nash TE, Cheever AW, Ottesen EA and Cook JA. Schistosome infections in humans: perspectives and recent findings. NIH conference. *Ann Intern Med* 1982; **97**: 740-754
- 5 Von Lichtenberg F, Sadun EH, Cheever AW, Erickson DG, Johnson AJ, Boyce HW. Experimental infection with *Schistosoma japonicum* in chimpanzees. *Am J Trop Med Hyg* 1971; **20**: 850-893
- 6 De Cock KM. Hepatosplenic schistosomiasis: a clinical review. *Gut* 1986; **27**: 734-745
- 7 Coutinho A. Hemodynamic studies of portal hypertension in schistosomiasis. *Am J Med* 1968; **44**: 547-557
- 8 Alves CA, Alves AR, Abreu W and Andrade ZA. Hepatic artery hypertrophy and sinusoidal hypertension in advanced schistosomiasis. *Gastroenterology* 1977; **72**: 126-128
- 9 Katz N, Chaves A, Pellegrino J. A simple device for a quantitative stool thick-smear technique in schistosomiasis mansoni. *Rev Inst Med Trop Sao Paulo* 1972; **14**: 397-400
- 10 Pinto PL, Amato Neto V, Matsubara L, de Carvalho SA. Intradermal reaction with diluted antigen for the diagnosis of *Schistosoma mansoni*: evaluation of sensitivity. *Rev Hosp Clin Fac Med Sao Paulo* 1988; **43**: 288–290
- 11 El-Garem AA. Schistosomiasis. *Digestion* 1998; **59**: 589–605
- 12 Richter J, Hatz C, Haussinger D. Ultrasound in tropical and parasitic diseases. *Lancet* 2003; **362**: 900–902
- 13 Cerri GG, Paranaguá-Vezozzo DC. L'ecographie des schistosomiasis hépatiques. *J EMU* 1992; **13**: 31–35

- 14 Merkel C, Sacerdoti D, Bolognesi M, Bombonato G, Gatta A. Doppler sonography and hepatic vein catheterization in portal hypertension: assesment of agreement in evaluating severity and response to treatment. *J Hepatol* 1998; **28**: 622-630
- 15 Michielsen PP, Duysburgh IK and Pelckmans PA. Ultrasound and duplex-Doppler in the diagnosis and follow-up of portal hypertension. *Acta Gastroenterology Belg* 1995; **58**: 409-421
- 16 Kuntz E and Dieter H. *Hepatology, Principles and Practice: history, morphology, biochemistry, diagnostics, clinic, therapy*, (The 2nd edition). 2006, PP. 212.
- 17 Bates JA. Pathology of the liver and portal venous system, Chapter 4. In: *Abdominal Ultrasound. How, Why and When?* Second edition, Edited by Bates, J.A. Churchill Livingstone, Edinburgh, London, New York, Philadelphia, Toronto 2004; 79-119
- 18 Olliff JF. The liver and spleen, Chapter 25. In: *Textbook of Radiology and Imaging*, (7th edition, Volume 1). Edited by Sutton D, Robinson PJ, Jenkins JP, Whitehouse RW, Allan PL, Wilde P, Stevens JM. Churchill Livingstone. 2003; 763-789
- 19 Zwiebel WJ. Vascular disorders of the liver, Chapter 29. In: *Introduction to Vascular Ultrasonography*. Edited by Zwiebel WJ. (4th edition), W B. Saunders Company. Philadelphia, London and Toronto. 2000; 431-454.
- 20 Li FH, Hao J, Xia JG, Li HL, Fang H. Hemodynamic analysis of esophageal varices in patients with liver cirrhosis using color Doppler ultrasound. *World J Gastroenterol* 2005; **11**: 4560-4565
- 21 Kockar O, Kockar MC, Erden A, Cumhur T. Relation between esophageal varices and splanchnic and portal veins diameter and flow volumes determined by duplex Doppler ultrasonography in chronic parenchymal liver disease. *Turkish J of Gastroenterol* 1999; **10**: 216-220
- 22 Kayacetin E, Efe D and Dogan C. Portal and splenic hemodynamics in cirrhotic patients: relationship between esophageal variceal bleeding and the severity of hepatic failure. *J Gastroenterol* 2004; **39**: 661-667
- 23 Haag K, Rossle M, Ochs A, Huber M, Siegerstetter V, Olschewski M, Berger E, Lu S and Blum H E. Correlation of duplex sonography findings and portal pressure in 375 patients with portal hypertension. *Am J Roentgenol* 1999; **172**: 631-635
- 24 Iwao T, Toyonaga A, Oho K, Tanama C, Masumoto H, Sakai T, Sato M, Tanikawa K. Value of Doppler ultrasound parameters of portal vein and hepatic artery in the diagnosis of cirrhosis and portal hypertension. *Am J Gastroenterology* 1997; **92**: 1012-1017
- 25 Niederau C, Sonnenberg A, Muller JE, Erckenbrecht JF, Scholten T, Fnitsch WP. Sonographic measurement of the normal liver, spleen, pancreas and portal vein. *Radiol* 1983; **149**: 537
- 26 Ishibashi H, Higuchi N, Shimamura R, Hirata Y, Kudo J and Niho Y. Sonographic assessment and grading of spleen size. *J Clin Ultrasound* 1991; **19**: 21–25
- 27 Bolognesi M, Merkel C, Sacerdoti D and Nava V. Role of spleen enlargement in cirrhosis with portal hypertension. *Dig Liver Dis* 2002; **34**: 144–150
- 28 Hammam HM, Zarzour AH, Moftah FM, ABDEL-ATY MA, HANY AH, EL-KADY AY, NASR AM, ABD-EL-SAMIE A, QAYED MH, MIKHAIL NN, TALAAT M and HUSSEIN MA. The epidemiology of schistosomiasis in Egypt: Qena Governorate. *American Journal of Tropical Medicine and Hygiene* 2000; **62(2)**: 80-87
- 29 Ross AG, Sleight AC, Li Y, Davis GM, Williams GM, Jiang Z, Feng Z, and McManus DP. Schistosomiasis in the People's Republic of China: prospects and challenges for the 21st century. *Clin Microbiol Rev* 2001; **14**: 270-295
- 30 Shakir Z Ibrahim, Beshir M Arbab, Suleiman H Suleiman, Osman Abdelwahab, Shawgi H Elmasri, Mohammed A Hassan. The natural history of bleeding oesophageal varices in patients with schistosomal portal hypertension. *Khartoum Medical Journal* 2010; **3(1)**: 385-392
- 31 De Cock KM. Hepatosplenic schistosomiasis: a clinical review.

- Gut* 1986; **27**: 734-745
- 32 Ibrahim SZ, Shah TI, Arbab BM and Abdelwahab O. Risk factors for bleeding in asymptomatic varices secondary to schistosomal portal hypertension. *Sudan Med J* 2009; **45**: 35-41
 - 33 dos Santos Fernandes CJ, Jardim CV, Hovnanian A, Hoette S, Dias BA, Souza S, Humbert M, Souza R. Survival in Schistosomiasis Pulmonary Hypertension. *Journal of the American College of Cardiology JACC*. 2010; **56**: 9
 - 34 Mies S. Hemodinâmica sistêmica e hepática na esquistossomose mansônica. Ação do propranolol. São Paulo. (Livre-Docência - Faculdade de Medicina da Universidade de São Paulo), 1992
 - 35 Chou YH, Chiou HJ, Tiu CM, Chiou SY, Lee SD, Hung GS, Wu SC, Kuo BI, Lee RC, Chiang JH, Chang T, Yu C. Duplex Doppler ultrasound of hepatic Schistosomiasis japonica: a study of 47 patients. *Am J Trop Med Hyg* 2003; **68**: 18-23
 - 36 Kardorff R, Olveda RM, Acosta LP, Duebbelde UJ, Aligui GD, Alcorn NJ, Doehring E. Hepatosplenic morbidity in schistosomiasis japonica: evaluation with Doppler sonography. *Am J Trop Med Hyg* 1999; **60**: 954-959
 - 37 Martins RD, Szejnfeld J, Lima FG and Ferrari AP. Endoscopic, ultrasonographic and US-Doppler parameters as indicators of variceal bleeding in patients with schistosomiasis. *Dig Dis Sci* 2000; **45**: 1013-1018
 - 38 Veozzo DC, Farias AQ, Cerri GG, Da Silva LC, Carrilho FJ. Assessment of Portal Hemodynamics by Doppler Ultrasound and of Liver Morphology in the Hepatosplenic and Hepatointestinal Forms of Schistosomiasis Mansoni. *Dig Dis Sci* 2006; **51**: 1413-1419
 - 39 Qurashi Mohamed-Ali, Nasr-Eldin M. A. Elwali, Ahmed A. Abdelhameed, Adil Mergani, Siddig Rahoud, Kamal E. Elagib, Osman K. Saeed, Laurent Abel, Mubarak M. A. Magzoub, and Alain J. Dessein. Susceptibility to Periportal (Symmers) Fibrosis in Human Schistosoma mansoni Infections: Evidence That Intensity and Duration of Infection, Gender, and Inherited Factors Are Critical in Disease Progression. *JID* 1999; **180**: 1298-306
 - 40 Souza MR, Toledo CF and Borges DR. Thrombocytopenia as a predictor of portal hypertension in schistosomiasis. *Dig Dis Sci* 2000; **4**: 51964-1970
 - 41 Moriyasu F, Nishida A, Ban N, Nakamura T, Sakai M, Miyake T, Uchino H. "Congestion index" of the portal vein. *Am J Roentgenol* 1986; **146**: 735-739
 - 42 Sallam MA, Salem AA and Bahgat MH. Correlation of congestion index of the portal vein with liver function tests and platelet count in liver cirrhosis. *The Egypt J Gastroenterol* 1996; **1**: 1-7

Peer reviewer: Nasser Hamed Mousa, MD, Associate Professor, Nasser hamed Mousa, Associate Professor, Tropical Medicine and Hepatology, Mansoura University, Mansoura City, 35516/20, Egypt.