

Is Colorectal Neoplasia Part of the Birt-Hogg-Dubé Syndrome?

Pia Snedker Boman, Lilian Bomme Ousager, Lennart Friis-Hansen, Thomas Van Overeem Hansen, Sigurd Broesby-Olsen, Anne-Marie Gerdes

Pia Snedker Boman, Kaplevej 95-2830 Sorgenfri-Virum, Department of Clinical Genetics, Rigshospitalet, University of Copenhagen, Copenhagen, Denmark

Lilian Bomme Ousager, Department of Clinical Genetics, Odense University Hospital, Odense, Denmark

Lennart Friis-Hansen, Center for Genomic Medicin, Rigshospitalet, University of Copenhagen, Copenhagen, Denmark

Thomas Van Overeem Hansen, Center for Genomic Medicin, Rigshospitalet, University of Copenhagen, Copenhagen, Denmark

Sigurd Broesby-Olsen, Department of Dermatology and Allergy Centre, Odense University Hospital, Odense, Denmark

Anne-Marie Gerdes, Department of Clinical Genetics, Rigshospitalet, University of Copenhagen, Copenhagen, Denmark

Correspondence to: Pia Snedker Boman, Kaplevej 95-2830 Sorgenfri-Virum, Department of Clinical Genetics, Rigshospitalet, University of Copenhagen, Copenhagen, Denmark

Email: Piasnedkerboman@hotmail.com

Telephone: +45-26806690

Received: October 8, 2013 Revised: January 23, 2014

Accepted: January 30, 2014

Published online: April 21, 2014

ABSTRACT

Birt-Hogg-Dubé (BHD) syndrome is an autosomal dominant disease originally characterized by the cutaneous triad of multiple fibrofolliculomas, trichodiscomas and acrochordons. Besides these benign skin tumours this cancer syndrome is characterized by pulmonary cysts, spontaneous pneumothorax, and renal cell carcinoma. It is controversial if an increased risk of other internal malignancies is part of the syndrome. We report a three generation family with BHD syndrome with a germline mutation in the FLCN gene. Two family members were diagnosed with colorectal cancer (CRC). We have been able to demonstrate LOH of the wildtype allele of the FLCN gene in the two family members indicating that this cancer type is part of the phenotypic presentation in this Danish BHD family.

Key words: Cancer; Colon; Clinical genetics; Genetic screening/counselling

Boman PS, Ousager LB, Friis-Hansen L, Hansen TVO, Broesby-Olsen S, Gerdes AM. Is Colorectal Neoplasia Part of the Birt-Hogg-Dubé Syndrome? *Journal of Gastroenterology and Hepatology Research* 2014; 3(4): 1039-1042 Available from: URL: <http://www.ghrnet.org/index.php/joghr/article/view/658>

INTRODUCTION

Birt-Hogg-Dubé (BHD) syndrome was first described in 1977. It is an autosomal dominant disease originally characterized by the cutaneous triad of multiple fibrofolliculomas, trichodiscomas and acrochordons (skin tags) that usually appear in the third or fourth decades of life^[1]. Besides these benign skin tumours this cancer syndrome is characterized by pulmonary cysts, spontaneous pneumothorax, and renal cell carcinoma^[2,3]. It is controversial if an increased risk of other internal malignancies is part of the syndrome. Earlier reports have also suggested an increased risk of colorectal neoplasia as part of the syndrome^[1,4,5,6]. Recent studies have varied in conclusions and a large epidemiological study from 2002 found no association between colon cancer and BHD syndrome^[7].

Here, we report a three generation family with BHD syndrome with a germline mutation in the folliculin gene (FLCN). Two family members were diagnosed with colorectal cancer (CRC) and loss of heterozygosity (LOH) of the wildtype FLCN allele was found in colorectal tumors in both family members.

CASE REPORT

A 45-year-old woman (the proband) and her father were referred to genetic counselling from the Department of Dermatology based on skin manifestations suspicious of BHD syndrome.

The proband had developed cosmetically annoying skin lesions in the face from the age of 20. Objective skin examination revealed multiple, small 2-4 millimeter, dome-shaped, firm, skin colored papules with symmetric distribution in the face, on the nose, upper chins and forehead. In addition, axillary acrochordons were found. A skin punchbiopsy from the chin showed histological changes

compatible with fibrofolliculoma. The proband was otherwise healthy.

The father also had fibrofolliculomas in the face and axillary acrochordons. He had experienced a pneumothorax several years ago after a minor traffic accident. He was moreover diagnosed with two colorectal tumours at age 69. Histology report described two separate adenocarcinomas in rectum and sigmoid with a normal expression of MLH1, MSH2 and MSH6 proteins in the sigmoid tumour.

The proband's paternal aunt had characteristic skin lesions and had had two spontaneous pneumothoraces in her thirties. At age 59 she was diagnosed with an adenocarcinoma in sigmoid colon and immunohistochemical analyses revealed normal expression of MLH1, MSH2 and MSH6 proteins. She was later diagnosed with a primary lung cancer at age 63 and pathology report described a basaloid carcinoma with focal neuroendocrine differentiation.

Mutation analysis identified a mutation in the FLCN gene (c.1062+2T>G), which previously has been predicted to cause aberrant splicing, since it is located in the conserved splice donor site^[8].

Mutation carriers are shown in the pedigree (Figure 1).

To examine whether LOH was present in the colorectal tumours of both patients, DNA from paraffin embedded normal and tumor tissue was extracted, amplified by PCR and sequenced. Only the sigmoid tumour from the father was examined. The analysis revealed LOH of the wild type allele in both tumor samples as the relative peak area for the FLCN c.1062+2T>G from normal and tumour tissue samples were calculated to be approximately 1:0.8 and 1:0.4, respectively (Figure 2).

DISCUSSION

The BHD syndrome is caused by germline mutations in the FLCN gene on chromosome 17 (17p11.2). The gene contains 14 exons and encodes a 579 amino acids protein^[9,10,11]. FLCN has recently been shown to belong to a family of Rab guanine nucleotide exchange factors (GEFs). The protein is thought to function as a tumour suppressor gene based on the presence of inactivating FLCN mutations in BHD patients as well as LOH findings in a significant proportion of BHD related tumours^[8,12]. A hypermutable polycytosine (C8) tract in exon 11 is a hotspot for germline mutations in this region and 53% of BHD families have mutations^[8]. The FLCN mutation

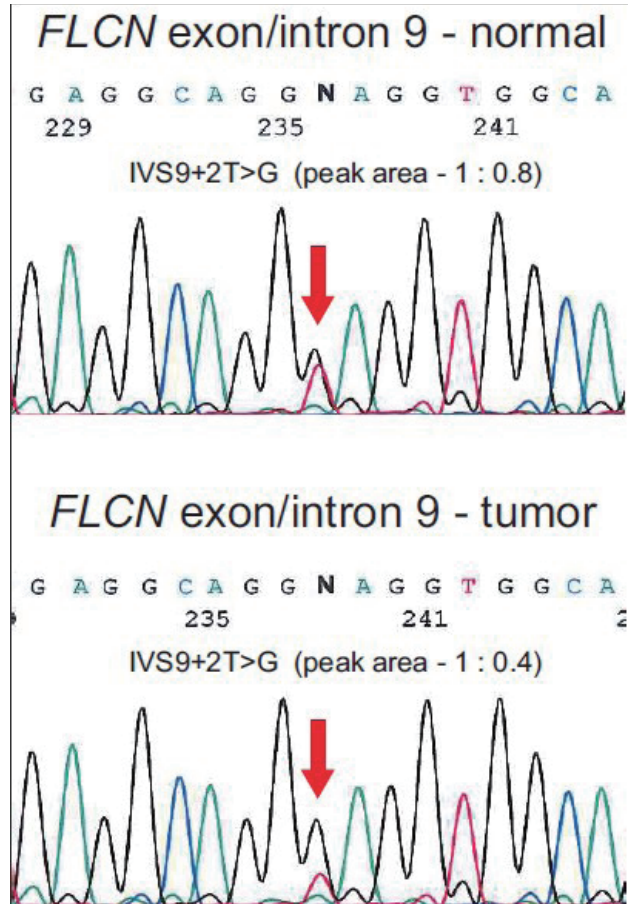


Figure 2 Identification of loss of heterozygosity (LOH) of the FLCN IVS9+2T>G mutation in tumor tissue. DNA was purified from normal and tumour tissue samples from the probands father and FLCN exon 9 were amplified using intronic primer pairs flanking exon 9 and sequenced. DNA sequences from normal and tumour tissue from the patient are shown. The FLCN c.1062+2T>G position is indicated by an arrow. The relative peak area for the FLCN c.1062+2T>G from normal and tumour tissue samples were calculated to be approximately 1:0.8 and 1:0.4, suggesting loss of heterozygosity (LOH) in the tumour tissue.

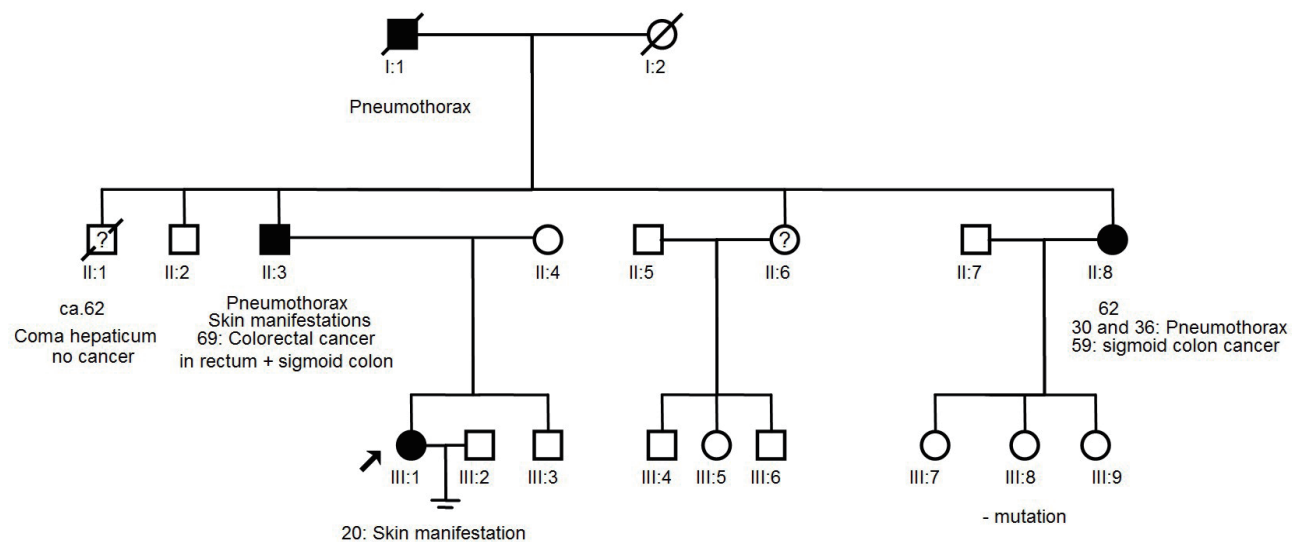


Figure 1 Mutation carriers are shown in the pedigree.

in this Danish BHD family was a T to G transversion in position +2 in intron 9 and it has been predicted to cause aberrant splicing. This mutation has been found in several Danish BHD families indicating a founder mutation.

The phenotype in BHD syndrome varies between families and there is also intrafamilial variability. It is debated whether CRC is part of the phenotype of BHD. No correlation between the location or type of FLCN mutation and the BHD phenotype has been described^[13]. Toro *et al*^[2] did not find a correlation between BHD syndrome and intestinal malignancies in their study of 152 patients in 1999, neither did Zbar *et al*^[7] in a study of 111 BHD patients. Both studies concluded that there is no significantly increased risk of colonic polyps or CRC in BHD patients.

However, several studies have shown an association between BHD and colonic polyps or CRC. Khoo *et al* studied a French three generation BHD pedigree. This family was first described in 1986 and is a large family with 20 family members where 10 persons are assumed to be affected due to typical skin lesions^[14]. Khoo *et al* found that six members of the family had colonic polyps and they were all mutation carriers^[10]. Furthermore two obligate mutation carriers died of suspected gastrointestinal cancer, but nor DNA nor histology reports were available.

Another case report described a BHD patient with the classic skin tumours, spontaneous pneumothorax, renal cell adenocarcinoma and several adenomas in the colon with severe dysplasia. Genetic studies found a 4 nucleotide deletion in exon 9 of the FLCN gene^[15]. There were no reports of CRC among family members.

Latest Kluger *et al* found a significant link to colorectal pathology in 10 French families with BHD syndrome. Colorectal polyps were diagnosed in 9 patients (50%) but histology reports were not available for all cases. No CRCs were diagnosed^[16].

The role of the FLCN gene in unselected sporadic colorectal tumours has been investigated and LOH was found in 81% of the analysed colorectal tumours. The result suggests an involvement of the FLCN gene in tumorigenesis in some microsatellite stable (MSS) sporadic colorectal tumours, and that allelic loss in the region close to the FLCN gene may participate in the progression of colorectal carcinomas^[12]. Other data showed that the FLCN gene is involved in microsatellite instable sporadic CRCs and it was demonstrated that somatic FLCN mutations were present in 5/32 (16%) cases^[17,18].

CONCLUSION

We have been able to demonstrate LOH of the wildtype allele of the FLCN gene in two family members with CRC indicating that this cancer type is part of the phenotypic presentation in this Danish BHD family. This supports an association between CRC and BHD syndrome which has also been concluded recently^[18]. It also seems that the FLCN gene is involved in tumorigenesis of sporadic CRCs. Further studies are needed to clarify if colorectal neoplasia is part of the tumour spectrum in BHD families.

CONFLICT OF INTERESTS

There are no conflicts of interest with regard to the present study.

REFERENCES

- 1 Birt AR, Hogg GR, Dubé WJ. Hereditary multiple fibrofolliculomas with trichodiscomas and acrochordons. *Arch Dermatol* 1977; **113**(12): 1674-1677
- 2 Toro JR, Glenn G, Duray P, Darling T, Weirich G, Zbar B, Linehan WM, Turner ML. Birt-Hogg-Dubé syndrome: a novel marker of kidney neoplasia. *Arch Dermatol* 1999; **135**: 1195-1202
- 3 Pavlovich CP, Walther MM, Eyler RA, Hewitt SM, Zbar B, Linehan WM, Merino MJ. Renal tumours in the Birt-Hogg-Dubé syndrome. *Am J Surg Pathol* 2002; **26**: 1542-1552
- 4 Hornstein OP. Generalized dermal perifollicular fibromas with polyps of the colon. *Hum Genet* 1976; **33**: 193-197
- 5 Rongioletti F, Hazini R, Gianotti G, Rebora A. Fibrofolliculomas, trichodiscomas and acrochordons (Birt-Hogg-Dubé) associated with intestinal polyposis. *Clin Exp Dermatol* 1989; **14**: 72-74
- 6 Schachtschabel AA, Kuster W, Happle R. Perifollicular fibroma of the skin and colonic polyps: Hornstein-Knickenberg syndrome. *Der Hautarzt; Zeitschrift für Dermatologie, Venerologie und verwandte Gebiete* 1996; **47**: 304-306
- 7 Zbar B, Alvord WG, Glenn G, Turner M, Pavlovich CP, Schmidt L, Walther M, Choyke P, Weirich G, Hewitt SM, Duray P, Gabril F, Greenberg C, Merino MJ, Toro J, Linehan WM. Risk of renal and colonic neoplasms and spontaneous pneumothorax in the Birt-Hogg-Dubé syndrome. *Cancer Epidemiol Biomarkers Prev* 2002; **11**: 393-400
- 8 Toro JR, Wei MH, Glenn G, Weinreich M, Toure O, Vocke C, Turner M, Choyke P, Merino MJ, Pinto PA, Steinberg SM, Schmidt LS, Linehan WM. BHD mutations, clinical and molecular genetic investigations of Birt-Hogg-Dubé syndrome: a new series of 50 families and a review of published reports. *J Med Genet* 2008; **45**: 321-331
- 9 Schmidt LS, Warren MB, Nickerson ML, Weirich G, Matrosova V, Toro JR, Turner ML, Duray P, Merino M, Hewitt S, Pavlovich CP, Glenn G, Greenberg CR, Linehan WM, Zbar B. Birt-Hogg-Dubé syndrome, a genodermatosis associated with spontaneous pneumothorax and kidney neoplasia, maps to chromosome 17p11.2. *Am J Hum Genet* 2001; **69**: 876-882
- 10 Khoo SK, Giraud S, Kahnoski K, Chen J, Motorna O, Nickolov R, Binet O, Lambert D, Friedel J, Lévy R, Ferlicot S, Wolkenstein P, Hammel P, Bergerheim U, Hedblad MA, Bradley M, Teh BT, Nordenskjöld M, Richard S. Clinical and genetic studies of Birt-Hogg-Dubé syndrome. *J Med Genet* 2002; **39**: 906-912
- 11 Nickerson ML, Warren MB, Toro JR, Matrosova V, Glenn G, Turner ML, Duray P, Merino M, Choyke P, Pavlovich CP, Sharma N, Walther M, Munroe D, Hill R, Maher E, Greenberg C, Lerman ML, Linehan WM, Zbar B, Schmidt LS. Mutations in a novel gene lead to kidney tumors, lung wall defects, and benign tumors of the hair follicle in patients with the Birt-Hogg-Dubé syndrome. *Cancer Cell* 2002; **2**: 157-164
- 12 Kahnoski K, Khoo SK, Nassif NT, Chen J, Lobo GP, Segelov E, Teh BT. Alterations of the Birt-Hogg-Dubé gene (BHD) in sporadic colorectal tumours. *J Med Genet* 2003; **40**: 511-515
- 13 Schmidt LS, Nickerson ML, Warren MB, Glenn GM, Toro JR, Merino MJ, Turner ML, Choyke PL, Sharma N, Peterson J, Morrison P, Maher ER, Walther MM, Zbar B, Linehan WM. Germline BHD-mutation spectrum and phenotype analysis of a large cohort of families with Birt-Hogg-Dubé syndrome. *Am J Hum Genet* 2005; **76**: 1023-1033
- 14 Binet O, Robin J, Vicart M, Ventura G, Beltzer-Garely E. Fibromas périfolliculaires, polypose colique familiale, pneumothorax spontané familiaux. *Ann Dermatol Venerol* 1986; **113**: 928-930
- 15 Stavrakoglou A, Dubrey SW, Dorkins H, Coutts I. The Birt-Hogg-Dubé syndrome: dermatological features and internal malignancies. *Q J Med* 2010; **103**: 987-990
- 16 Klüger N, Giraud S, Coupier I, Avril MF, Dereure O, Guillot B, Richard S, Bessis D. Birt Hogg Dubé syndrome: clinical and genetic studies of 10 French families. *Br J Dermatol* 2010;

Boman PS *et al.* Is colorectal Neoplasia Part of the Birt-Hogg-Dubé Syndrome?

- 162: 527-537
- 17 Shin J, Shin Y, Ku J, Jeong S, Hong S, Park S, Kim W, Park J. Mutations of the Birt Hogg Dubé (BHD) gene in sporadic colorectal carcinomas and colorectal carcinoma cell lines with microsatellite instability. *J Med Genet* 2003; **40**: 364-367
- 18 Raffaele Palmirotta, Annalisa savonarola, Giorgia Ludovici, Pietro Donati, Francesco Cavaliere, Maria Laura De Marchis, Patrizia Ferroni, Fiorella Guadagni. Association

Between Birt Hogg Dubé Syndrome and Cancer Predisposition. *Anticancer Research* 2010; **30**: 751-758

Peer reviewers: Takahisa Fujikawa, Director, Department of Surgery, Kokura Memorial Hospital, 3-2-1 Asano, Kokurakita-ku, Kitakyushu, Fukuoka 802-8555, Japan; Michael Kew Lim, Department of Colorectal Surgery, Christchurch Hospital, Riccarton Avenue, Christchurch 8011, New Zealand.