

## Increased Nuclear Localization of Interleukin 33 in Eosinophilic Esophagitis

Adrian Nathan Holm, Leana Gurein, Andrew Michael Bellizzi, Levent Bayman, Ron Schey

Adrian Nathan Holm, Bayman Levent, Schey Ron, Division of Gastroenterology, Department of Internal Medicine, Iowa City, IA, the Unites States

Guerin Leana, Andrew Michael Bellizzi, Department of Pathology, University of Iowa Carver College of Medicine, Iowa City, IA, the Unites States

Schey Ron, Division of Gastroenterology, Department of Medicine, Temple University School of Medicine, Temple University Hospital, Philadelphia, PA, the Unites States

Correspondence to: Schey Ron, Division of Gastroenterology, Department of Medicine, Temple University School of Medicine, Temple University Hospital, Philadelphia, PA, the Unites States

Email: Ron.Schey@tuhs.temple.edu

Telephone: +1-215-707-9900

Received: June 23, 2014 Revised: July 16, 2014

Accepted: July 30, 2014

Published online: August 21, 2014

of the pathophysiology, diagnosis and treatment of EoE.

© 2014 ACT. All rights reserved.

**Key words:** Eosinophilic esophagitis; GERD; Interleukin-33; Nuclear localization

Holm AN, Guerin L, Bellizzi AM, Bayman Le, Schey R. Increased Nuclear Localization of Interleukin 33 in Eosinophilic Esophagitis. *Journal of Gastroenterology and Hepatology Research* 2014; 3(8): 1188-1192 Available from: URL: <http://www.ghrnet.org/index.php/joghr/article/view/814>

### INTRODUCTION

Eosinophilic esophagitis (EoE) is a relatively recently described chronic immune and antigen mediated disease. The histopathological characteristics include increased eosinophilic inflammation within the esophagus which is not driven by gastroesophageal reflux disease (GERD), eosinophilic predominant inflammation within esophageal biopsies (typically  $\geq 15$  eosinophils/hpf). Additional histologic abnormalities including peak eosinophil concentration, eosinophilic microabscesses, surface predominance of eosinophilic infiltration, eosinophilic degranulation, basal cell hyperplasia, dilation of squamous intracellular spaces and lamina propria fibrosis may also be reported<sup>[1]</sup>.

The inflammation should be isolated to the esophagus, elimination of other causes of eosinophilia (particularly PPI responsive eosinophilia) should be performed, and patients should demonstrate improvement with therapies including dietary modification and/or topical corticosteroids<sup>[1]</sup>. Clinically, patients may present from any age group and frequently suffer from dysphagia and food impaction, failure to thrive, vomiting, epigastric or chest pain<sup>[2,3]</sup>. Endoscopic findings may include esophageal rings, strictures, furrowing, and white plaques, although the esophagus may often appear normal endoscopically as well. The disorder is common, affecting 15% of patients being evaluated for dysphagia and up to 6.5 % of patients undergoing upper endoscopy in recent studies<sup>[4,5]</sup>.

### ABSTRACT

**AIM:** Investigate the intensity and distribution of IL-33 staining in patients with EoE compared to healthy controls and patients with GERD.

**METHODS:** A retrospective study and reviewed pathology specimens from 20 patients with EoE and 20 patients with GERD and 20 healthy subjects. We performed immunohistochemical staining for IL-33 on these samples. The staining distribution was compared with respect to intranuclear or intracytoplasmic IL-33 intensity and the depth of staining intensity in the biopsies.

**RESULTS:** There was increased intensity of nuclear IL-33 staining in biopsies from patients with EoE as compared to healthy subjects patients with GERD ( $P < 0.001$ ), and no difference in cytoplasmic staining, or IL-33 distribution within biopsies thickness among the groups ( $P = 0.42$ ).

**CONCLUSION:** This study describes enhanced nuclear expression of IL-33 in EoE, a disorder characterized by a predominantly Th2 response and esophageal hypereosinophilia in the absence of GERD. Our observations may have implications for improved understanding

The precise cause of the aberrant inflammatory response that characterizes this disorder has not yet been identified, although there has been a proposed role for several Th2 cytokines including IL-5, IL-13 and IL-15<sup>[6,7]</sup>. A genome wide association study reported an association in pediatric patients with EoE with variants at chromosome 5q22, a locus that includes genes related to the Th2 immune response<sup>[8]</sup>.

Interleukin (IL)- 33 is a recently identified member of the IL-1 family of immunoregulatory proteins which had been found to exert function via Toll-like receptor (TLR)/IL-1R superfamily, and has been the subject of extensive recent investigation into the regulation and functioning of the cytokine in differing cell lines and disease states<sup>[9,10]</sup>. The IL-33 receptor ST2 had been previously cloned and the ligand subsequently identified 12 years later. The membrane bound ST2 receptor (ST2L) has been identified predominantly in cells of myeloid origin including mast cells, basophils, eosinophils, T cells, NKT cells and NK cells, and activation of the receptor complex leads to a predominantly Th2 cytokine profile<sup>[11]</sup>.

Expression of IL-33 has been identified in tissues and organs throughout the body including endothelial cells, smooth muscle, fibroblasts, adipocytes, epithelial cells, and hematopoietic cells<sup>[12-14]</sup>. The IL-33 protein localizes to the nucleus, an unusual although not unique pattern in cytokines. Although the role on intranuclear IL-33 continues to be the subject of investigation, studies showed that IL-33 functions to modify transcription of NF- $\kappa$ B induced gene expression, leading to dampened pro-inflammatory signaling resulting in cellular necrosis and tissue damage leading to functional cytokine<sup>[15]</sup>. Clinically, increased expression of the IL-33 activity has been identified in several pro-inflammatory conditions including asthma, autoimmune disease, arthritis, and anaphylaxis<sup>[16]</sup>. The Th2 profile induced by IL-33 leads to increased IgE levels, eosinophilic inflammation in the lung and gastrointestinal tract, and endothelial injury.

There is a remarkable association of EoE with Connective Tissue Disease (CTD) and it has been demonstrated that IL-33 plays an important role in the development and progression of rheumatic disease<sup>[17-21]</sup>.

Thus far there have been no studies evaluating the role of IL-33 in the esophagus in patients with EoE. We hypothesized that excessive levels of IL-33 may be associated with EoE, particularly as compared with an alternative promoter of esophageal eosinophilia such as GERD.

## METHODS

A retrospective designed study where distal and mid esophagus biopsy samples which were previously obtained from patients diagnosed with GERD and EoE were retrieved from archive storage. The samples were randomly selected from our clinical data base of GERD and EoE diagnosed patients between the years 2009-2013.

All patients were diagnosed, treated, and followed-up at the University of Iowa Hospital and Clinics outpatient clinic. The study was approved by the University of Iowa Hospitals and Clinics institutional review board.

A total of 60 samples were retrieved, 20 from patients diagnosed with EoE, 20 from patients with GERD and 20 normal esophageal biopsies. In patients with symptoms related to esophageal dysfunction EoE was diagnosed according to recent guidelines<sup>[1]</sup>:

(1) Eosinophil- predominant inflammation on esophageal biopsy with a peak value of  $\geq 15$  eos/hpf after 8 weeks of Proton Pump inhibitors treatment

(2) Eosinophilia limited to the esophagus.

(3) Exclusion of GERD based on documentation of normal esophageal acid exposure.

All biopsies had been previously formalin-fixed and paraffin-embedded. All biopsy samples were randomly selected from a database of patients with diagnosis of EoE and GERD. The GERD biopsy specimens were obtained from symptomatic patients who were found to have erosions on endoscopy, reflux esophagitis on microscopic analysis, and documentation of increased esophageal acid exposure based on 24 hour pH monitoring. Diagnosis of EoE was established based on the maximum esophageal eosinophil count per high-power field (hpf) (400 $\times$ ) and lack of improvement with acid suppression therapy. GERD patients typically had 0-14 eosinophils/hpf and no basal layer expansion, whereas EoE samples had  $\geq 15$  eosinophils/hpf.

The slides were numbered and patient identifiers removed. Staining had been previously performed with standard H&E preparation. These biopsy specimens were then stained with a Anti-IL33 antibody [Nessy-1] monoclonal antibody (mAb) directed against IL-33 (Biotin). Concentration and control staining were performed. Two experienced pathologists (LG, AB) rated 60 subjects in three different groups (EoE, GERD, Normal; 20 subjects each) in ordinal scale (1 to 4 in severity) by Nuclear staining and Nuclear distribution methods in two different blocks (proximal and distal). The slides were reviewed independently and the raters were unaware of the patient diagnosis or others rating. The biopsies were graded with respect to the intensity of IL-33 staining in a nuclear or cytoplasmic predominance, and with regards to where in the depth of the biopsy the staining was distributed (basal to surface). The scoring system utilized (Table 1) is based on similar scales developed for evaluation of staining in other tissues previously described<sup>[13]</sup>.

Data were analyzed by Mann-Whitney analysis given the non-parametric nature of the scoring used and non-paired samples obtained. *P* values less than 0.05 were considered statistically significant with a two-tailed analysis.

**Table 1** Scoring based on anti-IL-33 immunoreactivity.

	Scoring	Nuclear Intensity	Scoring	Cytoplasmic Distribution	Scoring	Cytoplasmic Intensity	Scoring
None	1	None	1	None	1	None	1
Surface	2	Mild	2	Surface	2	Mild	2
Surface/mid	3	Focal mild	3	Surface>basal	3	Moderate	3
Surface/basal	4	Moderate	4	Middle	4	Strong	4
Surface>basal	5	Strong	5	Basal>surface	5		
Basal>surface	6			Basal	6		
Basal	7			Full thickness	7		
Full thickness	8						

## RESULTS

A total of 60 esophageal biopsies were obtained from 20 EoE patients, 20 GERD patients, and 20 healthy controls. The groups did not differ significantly regarding acid suppression, or BMI. However, average age was lower in the group of subjects with EoE, and control group had more females than the other groups (Table 2). Tissue biopsies had been fixed in formaldehyde, and paraffin sections were used for immunohistochemistry staining by using a mAb against human IL-33. All samples were reviewed and staining intensity and distribution scored by an expert pathologist in a blinded fashion.

Samples were scored based on anti-IL-33 immunoreactivity in the tissue in four categories: Distribution of nuclear staining from

surface to basal pattern, intensity of nuclear staining, distribution of cytoplasmic staining from surface to basal pattern, and intensity of cytoplasmic staining.

The rater Agreement on Nuclear Staining Method was high for all locations (Table 3).

IL-33 staining was identified in cytoplasmic and nuclear aspects of esophageal squamous cells (Figure 1 and 2). The mean intensity of nuclear IL-33 staining in EoE subjects was significantly higher compared to GERD and healthy subjects ( $3.4 \pm 1.2$ ,  $2.4 \pm 1.2$ ,  $p=0.02$ ). The cytoplasmic intensity of IL-33 staining in EoE patients did not significantly differ compared to GERD and healthy subjects ( $P=0.7$ ) as shown in Figure 1 and demonstrable histologic image as seen in Figure 3 (A and B). The comparison of nuclear and cytoplasmic distribution in the thickness of the biopsy specimens of IL-33 staining was not statistically different between the three groups ( $p=0.07$  and  $p=0.35$  respectively) (Table 4).

Demographics	Normal (n = 20)	EoE (n = 20)	GERD (n = 20)	p-value
Age (sd)	43.3 (16.2)	28.6 (13.7)*	46.1 (12.6)	* <0.001
BMI (sd)	31.0 (7.2)	28.1 (5.9)	31.4 (7.2)	>0.05
Sex, male (%)	3 (15)	14 (70)	8 (40)	* < 0.01
Caucasian (%)	19 (95)	19 (100)	17 (89)	>0.05

Agreement Between Raters	Nuclear Staining (95% CI)
Proximal; Overall	0.71 (0.61; 0.82)
Proximal in EoE	0.73 (0.54; 0.91)
Proximal in GERD	0.70 (0.53; 0.87)
Proximal in Normal	0.69 (0.48; 0.88)

Table 4 Results from Wilcoxon Rank-Sum analyses of Raters' scores in Nuclear Staining and Nuclear Distribution methods in proximal esophagus.

Rater	N	Nuclear Staining			Nuclear Staining		
		Rank sum	Expected	P-value	Rank sum	Expected	P-value
<b>Rater 1</b>				<0.001* <sup>1</sup>			<0.001* <sup>1</sup>
EoE	20	822.5	610.0		822.5	610.0	
GERD	20	572.5	610.0		572.5	610.0	
Normal	20	435.0	610.0		435.0	610.0	
<b>Rater 2</b>				0.025* <sup>2</sup>			0.025* <sup>2</sup>
EoE	20	730.0	610.0		730.0	610.0	
GERD	20	642.5	610.0		642.5	610.0	
Normal	20	457.5	610.0		457.5	610.0	

\*<sup>1</sup>: EoE vs GERD <0.05 (Bonferroni adjusted  $p=0.009$ ); EoE vs Normal <0.05 (Bonferroni adjusted  $p<0.001$ ); EoE vs Normal >0.05.

\*<sup>2</sup>: EoE vs Normal <0.05 (Bonferroni adjusted  $p=0.013$ ); Normal vs GERD <0.05; EoE vs GERD <0.05.

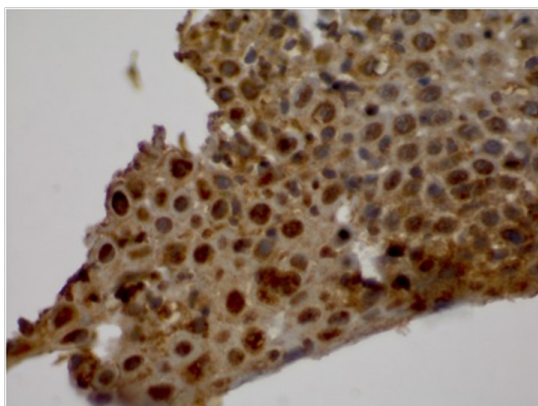


Figure 1 High power view of esophageal squamous mucosa stained with IL-33 Ab showing prominent nuclear staining.

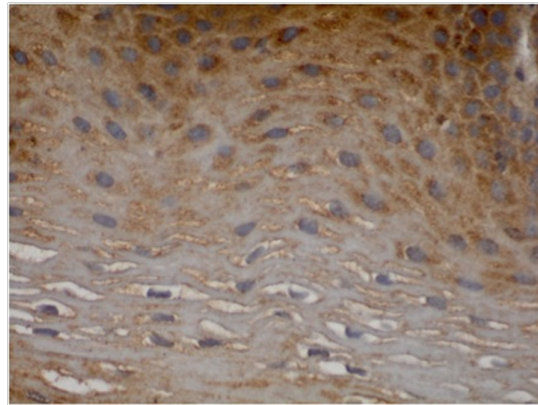


Figure 2 High power view of esophageal squamous mucosa stained with IL-33 Ab showing prominent cytoplasmic staining.

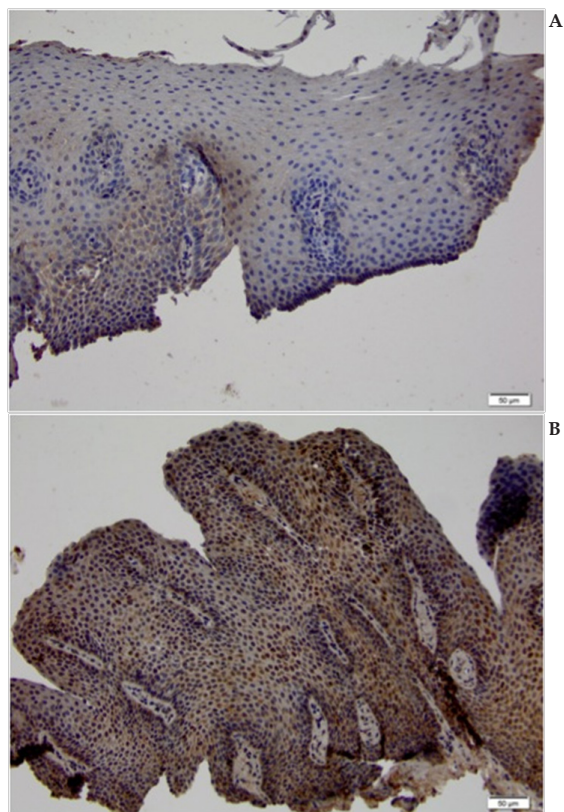


Figure 3 Comparison of IL-33 staining of squamous esophageal mucosa in patients with GERD (A) and EoE (B).

## DISCUSSION

Eosinophils are major effector cells in type 2 inflammatory responses and become activated in response to IL-4 and IL-33, yet the molecular mechanisms and cooperative interaction between these cytokines remain unclear. Recently, Bouffi *et al* have identified a novel activation pathway in murine eosinophils that is induced by IL-33 and differentially dependent upon an IL-4 auto-amplification loop<sup>[16]</sup>. Although IL-33 has been investigated in patients with asthma and generalized inflammatory disorders, there have been no prior evaluations of its role in patients with EoE.

We compared esophageal biopsies of patients with EoE patients with GERD, a disorder that has also been shown to result in increased esophageal intraepithelial eosinophils although via

differing mechanisms, and healthy subjects. We utilized a sensitive and specific method of identifying IL-33 in biopsy specimens. IL-33 immunoreactivity was demonstrated in both cytoplasmic and nuclear compartments, however there was significantly increased staining within the nuclei in patients with EoE as compared with the GERD specimens. The nuclear localization is consistent with the currently understood behavior of IL-33, although the role of the increased levels in patients with EoE remains uncertain. The potential functions of IL-33 in this population include induction of IL-4, IL-5 and IL-13, degranulation of mast cells, with subsequent attraction of eosinophils and additional pro-inflammatory cascade. Although we did not evaluate the levels of IL-4, IL-5, and IL-13 in our study, these have been investigated previously<sup>[18]</sup>.

While IL-33 is cleaved and inactivated by proteases during apoptosis, once bound to the heterodimer receptor complex of ST2 and IL-1R accessory protein, intracellular signaling is initiated. Recently, it has been shown that Anti-S T2 monoclonal antibody inhibits eosinophil infiltration<sup>[19]</sup>. The specific signaling pathways appear variable depending on the cell lines involved, but include association of myeloid differentiation primary response protein 88 (MYD88) and subsequent activation of nuclear factor  $\kappa$ B (NF- $\kappa$ B) inhibitor of NF- $\kappa$ B- $\alpha$  (I $\kappa$ B $\alpha$ ), extracellular signal-related kinase 1 (ERK1), ERK2, p38, JUN N-terminal kinase-1 (JNK-1) and (TRAF6) which have been described elsewhere<sup>[20,25,26]</sup>. The resulting actions include predominantly Th2 deviation and inflammatory reaction with mast cell degranulation, production of IL-1, IL-3, IL-4, IL-5, IL-6, IL-13 and TNF<sup>[21]</sup>. Ho *et al* recently demonstrated that genetic variation of ILRL1 can result in increased levels of sST2 and alter immune and inflammatory signaling through ST2/IL-33 pathway<sup>[22]</sup>.

IL-33 is localized simultaneously to nuclear euchromatin and membrane-bound cytoplasmic vesicles, and is secreted by living cells to carry out its extracellular functions without the need for cellular necrosis<sup>[23]</sup>. Although it is constitutively produced and sequestered in the nucleus, it does not induce there Th2 immune deviation and necessitates appropriate Damage-Associated Molecular Pattern molecules (DAMPs) to initiate the inflammatory process<sup>[24]</sup>.

IL-33 appears to promote broad pro-inflammatory changes by initiating a cascade of downstream effects leading to recruitment and degranulation of eosinophils, activation of dendritic cells, and TNF- $\alpha$  release.

Thus far it is not known what is IL-33's exact role in the nucleus. Our hypothesis is that it does not induce any genes that support allergic inflammatory disorders, and, more specifically genes that EC actually make like eotaxins, IL-25, and TSLP, or alternatively, induces homeostasis or repair genes. In order for it to play a role in the generation of Th2 cytokines, it must be secreted. Therefore, we assume that the intra-nuclear IL-33 in esophageal squamous mucosa actually serves as a holding area for eventual secretion in EoE patients.

Our findings provide information which could have future implications in terms of diagnostic utility particularly in differentiating patients with EoE from those with other disorders that lead to esophageal eosinophilia such as GERD. This could be useful clinically as these differing disorders are managed by different treatment strategies.

The other important consideration from the findings reported here are the potential utility of IL-33 as a therapeutic target which could allow inhibition of pro-inflammatory changes characteristic of EoE at an early common pathway of inflammation rather than treating the downstream effects as currently being performed with topical and systemic steroids.

Although initial treatments in animal models directed at depletion of IL-5 and IL-13 showed promise, subsequent human studies of IL-5 inhibition have been relatively unsuccessful in treatment of patients with EoE<sup>[27,28]</sup>. The pro inflammatory effects of IL-33 bring into question the potential role of this cytokine in the disease.

Recently Ravi *et al* proposed the possible existence of a subgroup of EoE patients who have low-grade esophageal eosinophilia (<15 Eos/HPF) and, at minimum, defy the guidelines used to diagnose this disorder<sup>[29]</sup>.

Other modifiers of IL-33 expression and function may also be useful for future investigation. In particular, TGF $\beta$  has been shown to mediate improvement in other models of intestinal inflammation and reduce IL-33 production<sup>[30]</sup>.

This intra nuclear localization may pose a challenge for directed therapeutic modalities such as antibodies currently used to decrease circulating levels of functional cytokines.

Future studies designed to evaluate the mechanisms which lead to IL-33 promotion in EoE, the diagnostic utility of IL-33 in patients with other esophageal hypereosinophilia syndromes, and treatment with Anti IL-33 inhibition are warranted.

## ACKNOWLEDGMENTS

Holm, Adrian -Design of the study, Data analysis and interpretation, drafting the manuscript; Guerin, Leana and Bellizzi, Andrew -Histopathology acquisition and evaluation; critical revising of the article for important intellectual content; Bayman, Levent- Data analysis and interpretation; Schey, Ron -Study design, Organization, Analysis and interpretation of data, Critical revising of the article for important intellectual content

## CONFLICT OF INTERESTS

There are no conflicts of interest with regard to the present study.

## REFERENCES

- 1 Dellon ES, Gonsalves N, Hirano I, et al. ACG clinical guideline: evidence-based approach to the diagnosis and management of esophageal eosinophilia and eosinophilic esophagitis (EoE). *Am J Gastroenterol* 2013; **108**(5): 679-692
- 2 Liacouras CA, Furuta GT, Hirano I, Atkins D, Attwood SE, Bonis PA, Burks AW, Chehade M, Collins MH, Dellon ES, Dohil R, Falk GW, Gonsalves N, Gupta SK, Katzka DA, Lucendo AJ, Markowitz JE, Noel RJ, Odze RD, Putnam PE, Richter JE, Romero Y, Ruchelli E, Sampson HA, Schoepfer A, Shaheen NJ, Sicherer SH, Spechler S, Spigelman JM, Straumann A, Wershil BK, Rothenberg ME, Aceves SS. Eosinophilic esophagitis: updated consensus recommendations for children and adults. *J Allergy Clin Immunol* 2011 Jul; **128**(1): 3-20
- 3 Liacouras CA, Spigelman JM, Ruchelli E, Verma R, Mascarenhas M, Semeao E, Flick J, Kelly J, Brown-Whitehorn T, Mamula P, Markowitz JE. Eosinophilic esophagitis: a 10-year experience in 381 children. *Clin Gastroenterol Hepatol* 2005 Dec; **3**(12): 1198-206
- 4 Veerappan GR, Perry JL, Duncan TJ, Baker TP, Maydonovitch C, Lake JM, Wong RK, Osgard EM Prevalence of eosinophilic esophagitis in an adult population undergoing upper endoscopy: a prospective study. *Clin Gastroenterol Hepatol* 2009
- 5 Van Rhijn BD, Verheij J, Smout AJ, Bredenoord AJ Rapidly increasing incidence of eosinophilic esophagitis in a large cohort. *Neurogastroenterol Motil* 2013 Jan; **25**(1): 47-52
- 6 Calman Prussin MD, Joohee Lee MD and Barbara Foster MS. Eosinophilic gastrointestinal disease and peanut allergy are alternatively associated with IL-5+ and IL-5- TH2 responses. Mecha-

- nisms of allergy and clinical immunology. *J Allergy Clin Immunol* 2009; **124**: 1326-1332
- 7 Blanchard C, Mingler MK, Vicario M, Abonia JP, Wu YY, Lu TX, Collins MH, Putnam PE, Wells SI, Rothenberg ME. IL-13 involvement in eosinophilic esophagitis: transcriptome analysis and reversibility with glucocorticoids. *J Allergy Clin Immunol* 2007 Dec; **120**(6): 1292-300
  - 8 Rothenberg ME, Spergel JM, Sherrill JD, Annaiah K, Martin LJ, Cianferoni A, Gober L, Kim C, Glessner J, Frackelton E, Thomas K, Blanchard C, Liacouras C, Verma R, Aceves S, Collins MH, Brown-Whitehorn T, Putnam PE, Franciosi JP, Chiavacci RM, Grant SF, Abonia JP, Sleiman PM, Hakonarson H. Common variants at 5q22 associate with pediatric eosinophilic esophagitis. *Nat Genet* 2010; **42**(4): 289-291
  - 9 Calman Prussin MD, Joohee Lee MD and Barbara Foster MS. Eosinophilic gastrointestinal disease and peanut allergy are alternatively associated with IL-5+ and IL-5- TH2 responses. Mechanisms of allergy and clinical immunology. *J Allergy Clin Immunol* 2009; **124**: 1326-1332
  - 10 Blanchard C, Mingler MK, Vicario M, Abonia JP, Wu YY, Lu TX, Collins MH, Putnam PE, Wells SI, Rothenberg ME. IL-13 involvement in eosinophilic esophagitis: transcriptome analysis and reversibility with glucocorticoids. *J Allergy Clin Immunol* 2007 Dec; **120**(6): 1292-300
  - 11 Schmitz J, Owyang A Oldham E, Song Y, Murphy E, McClanahan TK, Zurawski G, Moshrefi M, Qin J, Li X, Gorman DM, Bazan JF, Kastelein RA. IL-33, an interleukin-1-like cytokine that signals via the IL-1 receptor-related protein ST2 and induces T helper type 2-associated cytokines. *Immunity* 2005; **23**(5): 479-490
  - 12 Préfontaine D, Nadigel J, Chouiali F, Audusseau S, Semlali A, Chakir J, Martin J, Hamid Q. Increased IL-33 Expression by Epithelial Cells in Bronchial Asthma. *J Allergy Clin Immunol* 2010 **125**(3): 752-754
  - 13 Moussion C, Ortega N, Girard J. The IL-1-like cytokine IL-33 is constitutively expressed in the nucleus of endothelial cells and epithelial cells in vivo: a novel alarmin? *PLoS ONE* 2008; **3**(10): Article ID e3331
  - 14 Nile C, Barksby J, Jitprasertwong P, Preshaw PM, Taylor JJ. Expression and regulation of interleukin-33 in human monocytes. *Immunology* 2010; **130**(2): 172-180
  - 15 Ali S, Mohs A, Thomas M, Klre J, Ross R, Schmitz ML, Martin MU. The dual function cytokine IL-33 interacts with the transcription factor NF- $\kappa$ B to dampen NF- $\kappa$ B-stimulated gene transcription. *The Journal of Immunology* 2011; **187**: 1609-1616
  - 16 Bouffi C, Rochman M, Zust CB, Stucke EM, Kartashov A, Fulker PC, Barski A, Rothenberg ME. IL-33 markedly activates murine eosinophils by an NF- $\kappa$ B-dependent mechanism differentially dependent upon an IL-4-driven autoinflammatory loop. *J Immunol* 2013 Oct 15; **191**(8): 4317-4325
  - 17 Abonia JP, Wen T, Stucke EM, Grotjan T, Griffith MS, Kemme KA, Collins MH, Putnam PE, Franciosi JP, von Tiehl KF, Tinkle BT, Marsolo KA, Martin LJ, Ware SM, Rothenberg ME. High prevalence of eosinophilic esophagitis in patients with inherited connective tissue disorders. *J Allergy Clin Immunol* 2013 Aug; **132**(2): 378-386
  - 18 Lucendo AJ. Cellular and molecular immunological mechanisms in eosinophilic esophagitis: an updated overview of their clinical implications. *Expert Rev Gastroenterol Hepatol* 2014 Apr 18. [Epub ahead of print]
  - 19 Chuang CC, Chen CW, Huang YT, Du WY. Anti-ST2 monoclonal antibody inhibits eosinophil infiltration in *Angiostrongylus cantonensis*-infected mice. *J Microbiol Immunol Infect* 2014 Mar 20. [Epub ahead of print]
  - 20 Funakoshi-Tago M, Tago K, Hayakawa M, Tominaga S, Ohshio T, Sonoda Y, Kasahara T. TRAF6 is a critical signal transducer in IL-33 signaling pathway. *Cell Signal* 2008 Sep; **20**(9): 1679-1686
  - 21 Straumann A, Conus S, Grzonka P, Kita H, Kephart G, Bussmann C, Beglinger C, Smith DA, Patel J, Byrne M, Simon HU. Anti-interleukin-5 antibody treatment (mepolizumab) in active eosinophilic oesophagitis: a randomised, placebo-controlled, double-blind trial. *Gut* 2010 Jan; **59**(1): 21-30
  - 22 Ho JE, Chen WY, Chen MH, Larson MG, McCabe EL, Cheng S, Ghorbani A, Coglianese E, Emilsson V, Johnson AD, Walter S, Franceschini N, O'Donnell CJ, CARDIoGRAM Consortium, CHARGE Inflammation Working Group, Dehghan A, Lu C, Levy D, Newton-Cheh C; CHARGE Heart Failure Working Group, Lin H, Felix JF, Schreiter ER, Vasan RS, Januzzi JL, Lee RT, Wang TJ. Common genetic variation at the IL1RL1 locus regulates IL-33/ST2 signaling. *J Clin Invest* 2013 Oct 1; **123**(10): 4208-4218. doi: 10.1172/JCI67119. Epub 2013 Sep
  - 23 Kakkar R, Hei H, Dobner S, Lee RT. Interleukin 33 as a mechanically responsive cytokine secreted by living cells. *J Biol Chem* 2012; **287**: 6941-6948
  - 24 Paris G, Pozharskaya T, Asempa T, Lane AP. Damage-associated molecular patterns stimulate interleukin-33 expression in nasal polyp epithelial cells. *Int Forum Allergy Rhinol* 2014 Jan; **4**(1): 15-21
  - 25 Liew FY, Pitman NI, McInnes IB. Disease-associated functions of IL-33: the new kid in the IL-1 family. *Nat Rev Immunol* 2010; **10**: 103-110
  - 26 Ali S, Huber M, Kollwe C, Bischoff SC, Falk W, Martin MU. IL-1 receptor accessory protein is essential for IL-33-induced activation of T lymphocytes and mast cells. *Proc Natl Acad Sci U S A* 2007; **104**: 18660-18665
  - 27 Conus S, Straumann A, Bettler E, and Simon HU. Mepolizumab does not alter levels of eosinophils, T cells, and mast cells in the duodenal mucosa in eosinophilic esophagitis. *J Allergy Clin Immunol* 2010; **126**(1): 175-177
  - 28 Assa'ad, AH, Gupta, SK, Collins MH, Thomson M, Heath AT, Smith DA, Perschy TL, Jurgensen CH, Ortega HG, Aceves SS. An Antibody Against IL-5 Reduces Numbers of Esophageal Intraepithelial Eosinophils in Children with Eosinophilic Esophagitis. *Gastroenterology* 2011 Nov; **141**(5): 1593-1604
  - 29 Ravi K, Talley NJ, Smyrk TC, et al. Low grade esophageal eosinophilia in adults: An unrecognized part of the spectrum of eosinophilic esophagitis? *Dig Dis Sci* 2011 Jul; **56**(7): 1981-1986
  - 30 Rani R, Smulian AG, Greaves DR, Hogan SP, Herbert DR. TGF- $\beta$  limits IL-33 production and promotes the resolution of colitis through regulation of macrophage function. *Eur J Immunol* 2011; **41**(7): 2000-2009
- Peer reviewer:** Luis Rodrigo, Professor, Department of Gastroenterology, University Hospital Central of Asturias, c/ Celestino Villamil s. nº, 33.006. Oviedo. Spain.