

Analysis of Epidermal Growth Factor Receptor Expression in Hepatocellular Carcinoma: A Comparison of Fluorescence in Situ Hybridization and Immunohistochemistry

Serap Uslu, Hale Kirimlioglu, Umit Ince

Serap Uslu, PhD, Histology and Embryology, Instructor, Acibadem University Vocational School of Health Services, Istanbul, Turkey

Hale Kirimlioglu, MD, Associate Professor, Acibadem University, School of Medicine, Department of Pathology, Istanbul, Turkey

Umit Ince, MD, Professoir, Acibadem University, School of Medicine, Department of Pathology, Istanbul, Turkey

Correspondence to: Serap Uslu, PhD, Histology and Embryology, Instructor, Acibadem University Vocational School of Health Services, Istanbul, Turkey.

Email: musiuslu@gmail.com

Telephone: +90-5323258849

Received: May 22, 2014

Revised: July 2, 2014

Accepted: July 5, 2014

Published online: August 21, 2014

ABSTRACT

AIM: Epidermal growth factor receptor altered activity has been implicated in the development and growth of many tumors including hepatocellular carcinoma. In our study, we aimed to demonstrate and compare the epidermal growth factor receptor gene aberration by fluorescence in situ hybridization and immunohistochemical method. We also aimed to demonstrate the relation between epidermal growth factor receptor and established prognostic features, like tumor differentiation, vascular invasion, cytokeratin-19 immunohistochemical positivity.

METHODS: Twenty-six patients with hepatocellular carcinoma without having any metastasis and recurrences clinically at the time of tumor resection were recruited in our study. All cases were divided into two groups, according to their immunohistochemical cytokeratin-19 expression as either cytokeratin-19 positive or cytokeratin-19 negative hepatocellular carcinomas. Immunohistochemistry for epidermal growth factor receptor, and fluorescence in situ hybridization analyses were performed. The clinical and pathologic prognostic features were noted.

RESULTS: We have shown that the immunohistochemistry expression of

epidermal growth factor receptor in hepatocellular carcinoma is not related to epidermal growth factor receptor gene copy number.

CONCLUSION: As there is considerable disparity in the literature about the relationship of epidermal growth factor receptor expression and prognostic features in hepatocellular carcinoma further studies of larger series are needed.

© 2014 ACT. All rights reserved.

Key words: Hepatocellular carcinoma; Epidermal growth factor receptor; Fluorescence in situ hybridization; Immunohistochemistry

Uslu S, Kirimlioglu H, Ince U. Analysis of Epidermal Growth Factor Receptor Expression in Hepatocellular Carcinoma: A Comparison of Fluorescence in Situ Hybridization and Immunohistochemistry. *Journal of Gastroenterology and Hepatology Research* 2014; 3(8): 1193-1197 Available from: URL: <http://www.ghrnet.org/index.php/joghr/article/view/815>

INTRODUCTION

Hepatocellular carcinoma (HCC) is a poor prognostical tumor. Though it is a leading cause of death, the conventional systemic therapy strategies are ineffective and following surgical resection highly recur. One of the key molecular pathways is epidermal growth factor receptor (EGFR) in HCC development. The EGFR pathways plays an essential role in cell proliferation, survival and migration and its altered activity has been implicated in the development and growth of many tumors including HCC. The overexpression of EGFR has been observed in around 40%-70% of conventional HCCs and associated with more aggressive liver tumors^[1-8].

In recent studies the expression of EGFR in the majority of HCCs makes it a promising target of anti-EGFR therapies^[9,4,10,11]. Several studies have demonstrated positive immunopositivity of cytokeratin (CK) 19 in HCC, and CK19-positive HCC has a high metastatic

potential, which is also associated with a poor prognosis^[12,13,14]. Recent studies indicate that, the activation of the EGF-EGFR signaling pathway by inducing CK19 expression, is associated with the development of CK19-positive HCC and the EGF-induced increase in proliferative abilities and invasive properties of HCC, may account for the poor prognosis of the patients^[1,2,15].

The aim of this study was to demonstrate compare the epidermal growth factor receptor gene aberration by fluorescence in situ hybridization and immunohistochemical method and also the relation between epidermal growth factor receptor and established prognostic features, like tumor differentiation, vascular invasion, cytokeratin-19 immunohistochemical positivity in HCC.

METHODS

Patients

This study was approved by the Human Ethics Committee at Acibadem University School of Medicine (ATADEK). Twenty-six patients with hepatocellular carcinoma (HCC) without having any metastasis and recurrences clinically at the time of tumor resection were recruited in our study. All cases were divided into two groups, one of the group had CK19 positive and the other had CK19 negative immunohistochemistry expression. The age, gender, chronic liver disease and the size of the tumor were extracted from clinical and pathologic in records.

Histopathologic examination

Five-micrometer thick sections were cut from paraffin blocks and were stained with hematoxyline and eosin (H&E) (Thermo Sandon automatic stainer). The pattern of the tumor, presence of clear cell change, steatosis, giant cell formation, tumor necrosis and tumor grade were noted.

Immunohistochemistry

Three-micrometer thick serial sections were cut using a microtome. Streptavidin-biotin method was made for immunohistochemistry in full automatic system Ventana Benchmark XT (Arizona, USA). Sections were incubated with primary antibody EGFR (clone: EGFR.25, Ready to use, Novocastra), CK19 (clone: A53-B/A2.26, Ready to use, Neomarkers) for 40 minutes at 24°C. Then sections incubated biotinylated secondary antibody (iView DAB Delection Kit, Ventana, USA) for 4 minutes and streptavidin conjugated to Horseradishperoxidase (iView DAB Delection Kit, Ventana, USA) for 8 minutes. After incubating Diaminobenzidine (DAB, iView DAB Delection Kit, Ventana, USA) for 8 minutes applying Copper (iView DAB Delection Kit, Ventana, USA) for mordanting. All sections were stained hematoxylin II (Ventana, USA) for 12 minutes. After washing with tap water, sections were dehydrated through a graded ethanol series, cleared in xylene, and mounted with embedding agent Consul-Mount (Thermo Scientific, UK). All slides were evaluated by conventional light microscopy (Olympus BX51, Olympus America Inc., USA). Membranous staining of the EGFR was defined as positive. Tumor on the entire slide was assessed, and was graded according to both intensity and distribution. EGFR expression was classified into four categories: 0-5% positive cells were considered grade 0; 5 to 25% positive cells, moderate intensity and weakly stained cases more than 50%, graded as 1; more than 25 % positive cells, moderate staining intensity, and strong staining less than 50%, graded as 2; more than 50% having strong staining, graded as 3. For negative controls, the primary antibodies were omitted and nonimmune serum was used instead. For positive controls, sections of suitable tissues (as indicated in manufacturer protocols) were

stained. HSCORE was calculated using the following equation: $HSCORE = \sum Pi (i+1)$, where *i* is the intensity of labeling with a grade of 0, 1, 2 or 3 (weak, moderate, or strong, respectively) and *Pi* is the percentage of labelled cells for each intensity, varying from 0% to 100%.

In situ hybridization

Prior to the hybridization process, 5- μ m-thick sections obtained from paraffin blocks were deparaffinized, mounted on slides and subjected to a decreasing, graded alcohol series. An initial procedure with 98°C heat pretreatment and incubation in a citric solution was performed. The slides were exposed to pepsin for 10 minutes at 37°C and then washed with SSC wash buffer. Then, we exposed our slides to an increasing, graded alcohol series and air-dried them. Ten microliters of probe (ZytoLight, ZytoVision GmbH, Germany) was then added to each slide, and denaturation was performed for 10 minutes at 75°C, followed by 14 hours of hybridization at 37°C. After hybridization was performed, the slides were washed at 37°C with wash buffer. We incubated the slides in 30 μ L of DAPI for 15 minutes for negative staining (ZytoLight, ZytoVision GmbH, Germany). After the FISH procedure, the slides were examined on an Olympus Bx 50 microscope and photographed with an Olympus Dp20 camera. For fluorescence microscope examination of ZyGreen-labeled probes, an excitation of 503 nm and an emission of 523 nm were used, which are similar wavelengths to those used for FITC; for ZyOrange-labeled probes, an excitation of 547 and an emission of 547 nm were used, which are wavelengths similar to those used for rhodamine visualization.

Conditions of Interpretation

One hundred non-overlapping nuclei were counted by a histologist in a double-blind manner. No amplification: 1-5 copies of the gene present per nucleus in >50% cancer cells, low amplification: 6-10 copies of the gene, or a small gene cluster, present per nucleus >50% cancer cells, amplification >10 copies, or large clusters, of the gene present per nucleus in >50% cancer cells^[16,17].

Statistical Analysis

Statistical analyses were performed using the NCSS (Number Cruncher Statistical System) 2007&PASS (Power Analyses and Sample Size) 2008 Statistical Software (Utah, USA). Groups of data were evaluated definitive statistical methods besides compare to quantitative datas were used Students *t* Test and for analysing the datas which shown normal range were used Mann Whitney U test. When we used Yates Continuity Correction and Fisher's Exact test for qualitative datas. For all studies, values of $p < 0.01$ and $p < 0.05$ were considered to be significant.

RESULTS

Clinicopathologic Features of HCC Tumors

Total of 26 cases, the mean patient age was 55.43 years for women and 58.17 for men and one of our cases (24 men and 2 women) had either metastasis or recurrence. There were not any statistically differences mean ages and gender among cases ($p > 0.05$). The cause of HCC among the CK19 negative cases were 77.8% hepatitis B ($n=7$), 11.1% hepatitis C ($n=1$) and 11,1% hepatitis B and C ($n=1$) and among the CK19 positive cases were 12.5% hepatitis B ($n=1$), 12.5% hepatitis C ($n=1$), 12.5% hepatitis B and C ($n=3$). Additionally 37.5% cryptogenic ($n=3$) and 12.5% steatohepatitis ($n=1$). When we compare to tumor diameter between CK19 positive and negative tumors, the CK19 positive tumors were larger than CK19 negative

tumors ($p < 0.05$). We found a correlation with lenfovascular invasion between the groups ($p < 0.01$). When we compared to chronic hepatitis etiology, tumor pattern presence of clear cell change, steatosis, giant cell formation, tumor necrosis and tumor grade, we did not find any statistically differences ($p > 0.05$) (Table 1).

Immunohistochemical Findings

EGFR immunohistochemistry results were classified weak (+1), moderate (+2) and strong (+3). We found grade 1 EGFR immunoexpression in twelve cases, 5 cases were grade 2 and 2 cases were grade 3, 7 cases had no EGFR immunoexpression. 73% of the cases had EGFR immunoexpression only 27% of them were had moderate to severe expression. We found CK19 expression in 12 cases and CK19 was negative in 14 cases. When we examined CK19-negative cases, in one of cases was grade 3, in twelve of cases were grade 2 and in one of cases was grade 1 in EGFR immunoexpressions. In four of cases were grade 3, in eight of cases grade 2 in EGFR immunoexpression among CK19-positive cases. We could not find any statistically differences between all cases ($p > 0.05$) (Figure 1).

Fluorescence In Situ Hybridization

FISH was performed in all 26 cases (Table 1). One hundred non-overlapping nuclei were counted in every cases. We found 1-5 copies of the gene present per nucleus in >50% cancer cells in all cases. FISH results showed that, no statistically significant amplification between CK19 positive and negative cases ($p > 0.05$) (Figure 2).

Correlation of immunohistochemistry expression and FISH amplification

Although specificity was 73% for EGFR positivity and 27% of them were had moderate to severe positivity, we could not find statistically correlation between immunohistochemistry expression and gene amplification in FISH results ($p > 0.05$).

DISCUSSION

For the hepatocellular carcinoma if the patient is not fit for the surgery we don't have a good therapy strategie. As a promising target of anti-EGFR therapies in new therapy strategies are investigating, in recent years some selected patients can respond to anti-EGFR therapies in tumors^[18,19]. It remains unclear whether determination of EGFR status by immunohistochemical analysis or FISH has predictive or prognostic value in tumors^[20,21].

In our study we found EGFR overexpression by immunohistochemical analysis in HCCs thus is similar with the other studies. As in the literature we could not find any correlation between the overexpression of EGFR and the gene amplification in FISH analysis.

EGFR immunohistochemical analysis has been used with varying degrees of success to predict response to anti-EGFR therapies^[22,23] and is more likely to be predictive of response to anti-EGFR antibodies. For small-molecule inhibitors of EGFR such as TKIs, surface expression may be less relevant than other parameters such as gene copy number. It has been suggested that a high EGFR copy number shown by FISH (defined as ≥ 4 copies in $\geq 40\%$ of tumor

Table 1 Clinicopathologic Features of HCC Tumors.

Case	FISH Amp.	EGFR Exp.	Age/Gender	Ck19	Patern	Clear cell	Giant Cell	Necrosis	Steatosis	Histo. grade	Nucleer grade	Lenfov. invasion	Diameter
1	-	+1	51/F	-	T	yes	yes	no	no	3	3	no	1
2	-	+1	41/M	-	M	yes	yes	focal	no	3	2	yes	2
3	-	+1	56/M	-	T	yes	yes	yes	no	3	3	yes	1
4	-	0	60/M	-	T	no	yes	no	no	2	3	no	1
5	-	+1	57/M	-	M+T	yes	yes	yes	no	3	2	yes	3
6	-	+1	62/F	-	P+T	yes	no	no	focal	2	2	no	0
7	-	0	58/M	-	T	no	yes	focal	focal	2	3	no	0
8	-	+2	54/M	-	P+T	no	no	no	no	2	2	no	0
9	-	+2	50/M	-	P+T	no	no	no	no	2	1	no	0
10	-	0	62/M	-	P+T	yes	no	no	focal	1	2	no	1
11	-	+1	54/M	-	A	no	yes	yes	no	3		yes	3
12	-	+2	50/M	-	A	no	no	no	no	2		no	2
13	-	+1	56/M	-	T	no	no	no	no	2		no	3
14	-	+1	65/M	-	T	yes	yes	yes	yes	3		yes	3
15	-	+2	65/M	+	P+M	yes	yes	yes	yes	2	3	yes	3
16	-	+3	65/M	+	M+T	yes	yes	yes	focal	3	2	yes	3
17	-	+1	55/F	+	P+T	yes	yes	yes	no	3	3	yes	3
18	-	+0	48/M	+	P+T	no	no	yes	no	2	3	yes	3
19	-	+2	65/M	+	P+T	no	yes	yes	no	3	2	yes	3
20	-	0	56/M	+	P	yes	yes	no	no	2	3	yes	3
21	-	+1	38/F	+	T	no	no	no	no	3	3	yes	1
22	-	0	49/M	+	T	no	no	no	no	2		no	3
23	-	+1	74/M	+	T	yes	yes	yes	yes	2		yes	3
24	-	0	68/M	+	A	no	no	no	no	3		yes	1
25	-	+3	68/M	+	A	no	no	no	no	3		yes	1
26	-	+1	47/M	+	A	no	yes	yes	no	3		yes	3

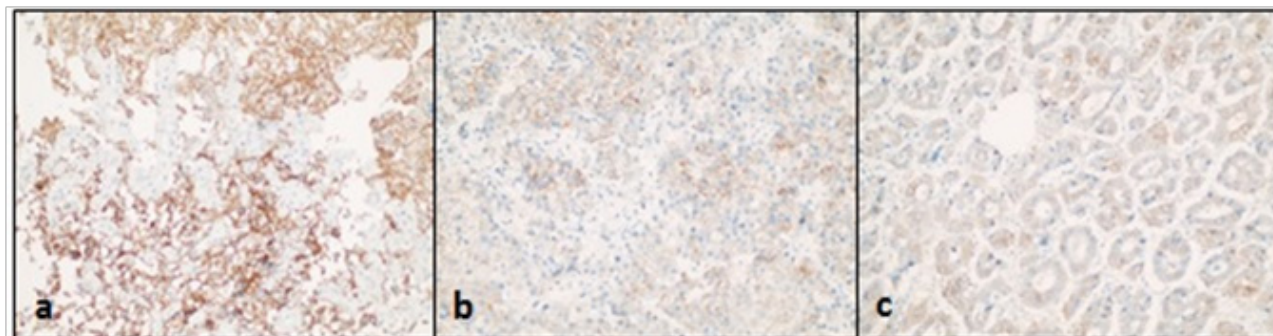


Figure 1 Immunohistochemical analysis for epidermal growth factor receptor showing strong membrane expression (a), moderate membrane expression (b), mild expression (c) in hepatocellular carcinoma ($\times 40$).

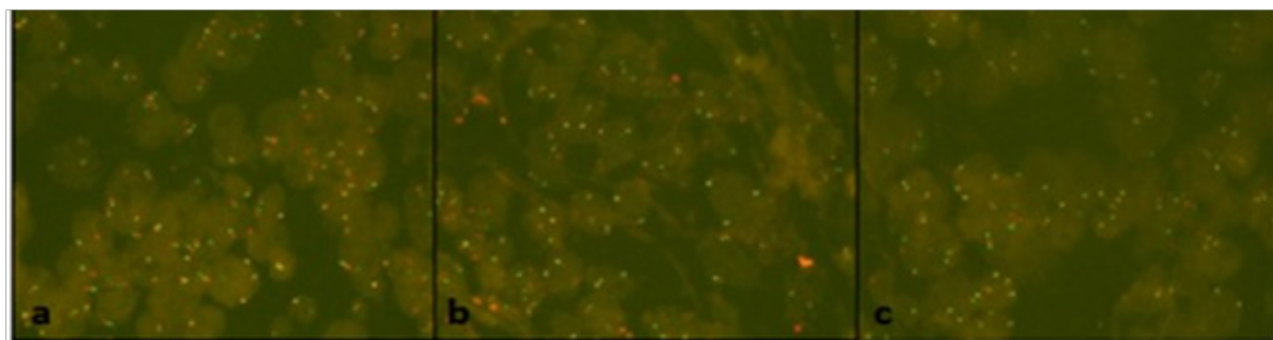


Figure 2 Fluorescence in situ hybridization using probes directed against the epidermal growth factor receptor (EGFR) gene (green) and centromere of chromosome 7 (red) ($\times 1000$).

cells) is a good selection criterion for gefitinib therapy. Although recent studies that were demonstrated that the strong expression of EGFR in the majority of HCCs suggested its important role in hepatocarcinogenesis, there is considerable disparity in the literature about the relationship of EGFR expression and clinicopathologic features in HCC.

In our study we tried to find out both the correlation between the immunohistochemical EGFR expression and EGFR gene copy number and prognostic role of EGFR in HCC. We could not find any relation between EGFR expression and EGFR gene copy number in HCC. Normal copy numbers of the EGFR gene identified by FISH were observed in 50% of HCCs with positive EGFR expression by immunohistochemical analysis, whereas 36% of HCCs that were immunohistochemically negative for EGFR had increased EGFR gene copy numbers. On the other hand, 57% of tumors with a normal EGFR gene copy number showed EGFR overexpression.

In the literature in some of the studies^[6,24-27] were found the relationship of EGFR expression and clinicopathologic features in HCC, however other studies as in our study, have failed to demonstrate a correlation between EGFR expression and differentiation^[24], vascular or extrahepatic invasion^[6,27], metastasis^[6,27] and survival^[8]. A positive correlation has been reported with hepatitis B viral infection^[28], but our study did not show any relationship of EGFR expression with hepatitis B or C. These differences are likely be related to differences in assays used to determine EGFR status and/or variability in the populations studied. The high frequency of EGFR overexpression suggests that it has an important role in hepatocarcinogenesis, but lack of consistent correlation with clinicopathologic features and survival may indicate that it is less important in disease progression. Similar to EGFR expression, an increased EGFR copy number shown by FISH also did not correlate with clinicopathologic features and survival.

Although HCC remains a promising target for anti-EGFR therapies, selection criterias are unclear. Several studies have demonstrated

that the positive immunoexpression of cytokeratin (CK) 19 in HCC, and CK19-positive HCC has a high metastatic potential, which is associated with a poor prognosis. Recent studies indicate that the activation of the EGF-EGFR signaling pathway is associated with the development of CK19-positive HCC, and the EGF-induced increase in growth abilities of HCC may account for the poor prognosis of the patients^[29]. In our study although there was correlation between tumor differentiation and vascular invasion; we could not find any association between EGFR expression and immunohistochemical CK19 positivity.

Despite some of the studies in our study we could not demonstrate any correlation between the EGFR overexpression shown by immunohistochemical analysis or an increase in copy number demonstrated by FISH. Although the strong expression of EGFR in HCCs makes it a promising target of anti-EGFR therapies, further studies are necessary to demonstrate the role of EGFR overexpression in HCC and in selecting patients for treatment^[3].

EGFR overexpression is present in a majority of hepatocellular carcinomas, suggesting a role for EGFR antagonists in therapy. The increased expression does not correlate with an increase in the EGFR gene copy number. However, the nuances, compared with the other studies suggested that, the EGFR may also pose a role of the HCC progression. As there is a considerable disparity in the literature about the relationship of EGFR expression and prognostic features in HCC further studies of larger series are needed.

CONFLICT OF INTERESTS

There are no conflicts of interest with regard to the present study.

REFERENCES

- 1 Yoneda N, Sato Y, Kitao A, Ikeda H, Sawada-Kitamura S, Miyakoshi M, Harada K, Sasaki M, Matsui O, Nakanuma Y.

- Epidermal growth factor induces cytokeratin 19 expression accompanied by increased growth abilities in human hepatocellular carcinoma. *Laboratory Investigation* 2011; **91**: 262-272
- 2 Berasain C, Latasa MU, Urtasun R, Goñi S, Elizalde M, Garcia-Irigoyen O, Azcona M, Prieto J, Ávila MA. Epidermal growth factor receptor (EGFR) crosstalks in liver cancer. *Cancers* 2011; **3**: 2444-2461
 - 3 Buckley AF, Burgart LJ, Sahai V, Kakar S. Epidermal growth factor receptor expression and gene copy number in conventional hepatocellular carcinoma. *Am J Clin Pathol* 2008; **129**: 245-251
 - 4 Schiffer E, Housset C, Cacheux W, Vendum D, Desbois-Mouyhon C, Rey C, Clergue F, Poupon R, Barbu V, Rosmorduc O. Gefitinib, an EGFR inhibitor, prevents hepatocellular carcinoma development in the rat liver with cirrhosis. *Hepatology* 2005; **41**: 307-314
 - 5 Tanaka H. Immunohistochemical studies on epidermal growth factor receptor in hepatocellular carcinoma. *Nippon Shokakibyō Gakkai Zasshi* 1991; **88**: 138-144
 - 6 Tang Z, Qin L, Wang X, Zhou G, Liao Y, Wenig Y, Jiang X, Lin Z, Liu K, Ye S. Alterations of oncogenes, tumor suppressor genes and growth factors in hepatocellular carcinoma: with relation to tumor size and invasiveness. *Chin Med J (Engl)* 1998; **111**: 313-318
 - 7 El-Bassiouni A, Nosseir M, Zoheiry M, El-Ahwany E, Ghali A, El-Bassiouni N. Immunohistochemical expression of CD95 (Fas), c-myc and epidermal growth factor receptor in hepatitis C virus infection, cirrhotic liver disease and hepatocellular carcinoma. *APMIS* 2006; **114**: 420-427
 - 8 Ito Y, Takeda T, Sakon M, Tsujimoto M, Higashiyama S, Noda K, Miyoshi E, Moden M, Matsuura N. Expression and clinical significance of erb-B receptor family in hepatocellular carcinoma. *Br J Cancer* 2001; **84**: 1377-1383
 - 9 Liu Y, Poon RTP, Shao W, Sun X, Chen H, Kok TW, Fan ST. Blockage of epidermal growth factor by quinazoline tyrosine kinase inhibitors suppresses growth of human hepatocellular carcinoma. *Cancer Lett* 2007; **248**: 32-40
 - 10 Hoffner M, Sutter AP, Huether A, Schuppan D, Zeitz M, Scherubl H. Targeting the epidermal growth factor receptor by gefitinib for treatment of hepatocellular carcinoma. *J Hepatol* 2004; **41**: 1008-1016
 - 11 Philip PA, Mahoney MR, Allmer C, Thomas J, Pitot HC, Kim G, Donehower RC, Fitch T, Picus J, Erlichman C. Phase II study of erlotinib (OSI-774) in patients with advanced hepatocellular carcinoma. *J Clin Oncol* 2005; **23**: 6657-6663
 - 12 Uenishi T, Kubo S, Yamamoto T, Shuto T, Ogawa M, Tanaka H, Tanaka S, Kaneda K, Hirohashi K. Cytokeratin 19 expression in hepatocellular carcinoma predicts early postoperative recurrence. *Cancer Sci* 2003; **94**: 851-857
 - 13 Wu PC, Fang JW, Lau VK, Lai CL, Lo CK, Lau JY. Classification of hepatocellular carcinoma according to hepatocellular and biliary differentiation markers. *Clinical and biological implications Am J Pathol* 1996; **149**: 1167-1175
 - 14 Ding SJ, Li Y, Tan YX, Jiang MR, Tian B, Liu YK, Shao XX, Ye SL, Wu JR, Zeng R, Wang HY, Tang ZY, Xia QC. From proteomic analysis to clinical significance: overexpression of cytokeratin 19 correlates with hepatocellular carcinoma metastasis. *Mol Cell Proteomics* 2004; **3**: 73-81
 - 15 Roayaie S, Minguez B, Sole M, Battiston C, van Laarhoven S, Fiel MI, Di Feo A, Hoshida Y, Yea Y, Toffanin S, Ramos A, Martignetti JA, Mazzaferro V, Bruix J, Waxman S, Schwartz M, Meyerson M, Friedman SL, Llovet JM. Pivotal role of mTOR signaling in hepatocellular carcinoma. *Gastroenterology* 2008; **135**: 1972-1983
 - 16 Bernardes VF, Gleber-Netto FO, Sousa SF, Rocha RM, Aguiar MCF. EGFR status in oral squamous cell carcinoma: comparing immunohistochemistry, FISH and CISH detection in a case series study. *BMJ open accessible medical research* 2013; **3**: e002077. Doi:10.1136/bmjopen-2012-002077
 - 17 Shia J, Klimstra DS, Li AR, Qin J, Saltz L, Teruya-Feldstein J, Akram M, Chung KY, Yao D, Paty PB, Gerald W, Chen B. Epidermal growth factor receptor expression and gene amplification in colorectal carcinoma: an immunohistochemical and chromogenic in situ hybridization study. *Modern Pathology* 2005; **18**: 1350-1356
 - 18 Lynch TJ, Bell DW, Sordella R, Gurubhagavatula S, Okimoto RA, Brannigan BW, Harris PL, Haserlat SM, Supko JG, Haluska FG, Louis DN, Christiani DC, Settleman J, Haber DA. Activating mutations in the epidermal growth factor receptor underlying responsiveness of non-small-cell lung cancer to gefitinib. *N Engl J Med* 2004; **350**: 2129-2139
 - 19 Moroni M, Veronese S, Benvenuti S, Marrapese G, Sartore-Bianchi A, Di Nicolantonio F, Gambacorta M, Siena S, Bardelli A. Gene copy number for epidermal growth factor receptor (EGFR) and clinical response to anti-EGFR treatment in colorectal cancer: a cohort study. *Lancet Oncol* 2005; **6**: 279-286
 - 20 Hirsch FR, Varella-Garcia M, Bunn PA Jr, Di Maria MV, Veve R, Bremmes RM, Barón AE, Zeng C, Franklin WA. Epidermal growth factor receptor in non-small-cell lung carcinomas: correlation between gene copy number and protein expression and impact on prognosis. *J Clin Oncol* 2003; **21**: 3798-3807
 - 21 Arteaga CL. Epidermal growth factor receptor dependence in human tumors: more than just expression? *Oncologist* 2002; **7**: 31-39
 - 22 Chung KY, Shia J, Kemeny NE, Shah M, Schwartz GK, Tse A, Hamilton A, Pan P, Schraq D, Schwartz L, Klimstra DS, Fridman D, Kelsen DP, Saltz LB. Cetuximab shows activity in colorectal cancer patients with tumors that do not express the epidermal growth factor receptor by immunohistochemistry. *J Clin Oncol* 2005; **23**: 1803-1810
 - 23 Dei Tos AP, Ellis I. Assessing epidermal growth factor expression in tumors: what is the value of current test methods? *Eur J Cancer* 2005; **41**: 1383-1392
 - 24 Zhao YN, Cao J, Wu FX, Ou C, Yuan WP, Mo QG, Wei W, Li Y, Su JJ, Liang AM. Expression and significance of EGF mRNA and EGFR mRNA in hepatocellular carcinoma. *Ai Zheng* 2004; **23**: 762-766
 - 25 Harada K, Shiota G, Kawasaki H. Transforming growth factor-alpha and epidermal growth factor receptor in chronic liver disease and hepatocellular carcinoma. *Liver* 1999; **19**: 318-325
 - 26 Kira S, Nakanishi T, Suemori S, Kitamoto M, Watanabe Y, Kajiyama G. Expression of transforming growth factor alpha and epidermal growth factor receptor in human hepatocellular carcinoma. *Liver* 1997; **17**: 177-182
 - 27 Hamazaki K, Yunoki Y, Tagashira H, Mimura T, Mori M, Orita K. Epidermal growth factor receptor in human hepatocellular carcinoma. *Cancer Detect Prev* 1997; **21**: 355-360
 - 28 Kannangai R, Sahin F, Torbenson S. EGFR is phosphorylated at Ty845 in hepatocellular carcinoma. *Mod Pathol* 2006; **19**: 1456-1461
 - 29 Yoneda N, Sato K, Kitao A, Ikeda H, Sawada-Kitamura S, Miyakos M, Harada K, Sasaki M, Matsui O, Nakanuma Y. Epidermal growth factor induces cytokeratin 19 expression accompanied by increased growth abilities in human hepatocellular carcinoma. *Lab Invest* 2011; **91**: 262-272
- Peer reviewers:** Hidekazu Suzuki, Division of Gastroenterology and Hepatology, Department of Internal Medicine, Keio University School of Medicine, 35 Shinanomachi, Shinjuku-ku, Tokyo 160-8582, Japan; Munachika Enjoji, MD, PhD, Health Care Center, Fukuoka University, 8-19-1 Nanakuma, Jonan-ku, Fukuoka 814-0180, Japan.