

Spontaneous Necrosis of Colonic Polyps: Two Cases of Disappearance of Polyps

Bilal Gondal, Roger Mitty, Anisha Varma-Wilson, David Cave

Bilal Gondal, Department of Medicine, UMass Memorial Medical Center, Worcester, 01655 MA, the United States

Roger Mitty, Anisha Varma-Wilson, Department of Medicine, St. Elizabeth's Medical Center, MA 02135, the United States

David Cave, Department of Gastroenterology, UMass Memorial Medical Center, Worcester, 01655 MA, the United States

Correspondence to: Bilal Gondal MD, MRCSI, Department of Internal Medicine, University of Massachusetts Memorial Medical School, 55 Lake Ave, Worcester, Massachusetts 01655, the United States.

Email: bilal.gondal@uchospitals.edu

Telephone: +1-774-242-6808

Fax: +1-508-856-3981

Received: June 8, 2014

Revised: July 7, 2014

Accepted: July 11, 2014

Published online: August 21, 2014

ABSTRACT

It is well known that not all adenomatous colonic polyps become malignant. A longstanding concept is that mechanical damage or loss of blood supply to a polyp could result in necrosis and auto amputation. We report seeing two cases of spontaneous necrosis of colon polyps in two men of age 64 and 88 years. These cases were observed during a nine year period out of 30,000 colonoscopies performed at our hospital. This is the first report of endoscopic visualization of spontaneous necrosis of polyps. It is a rare phenomenon, and has not been reported by the medical community. Polyps usually grow slowly over many years and the chance of endoscopically encountering a polyp in the process of necrosis, which is likely to occur over a few days, before auto amputation occurs, has a very low probability.

© 2014 ACT. All rights reserved.

Key words: Disappearance of polyps; Loss of polyp blood supply; Adenoma carcinoma; Colon cancer diagnosis; Polyp auto-amputation

Gondal B, Mitty R, Varma-Wilson A, Cave D. Spontaneous Necrosis

of Colonic Polyps: Two Cases of Disappearance of Polyps. *Journal of Gastroenterology and Hepatology Research* 2014; 3(8): 1210-1212 Available from: URL: <http://www.ghrnet.org/index.php/joghr/article/view/820>

INTRODUCTION

The spontaneous disappearance of colonic and other intestinal polyps has been rarely reported in the literature. There are a few isolated reports where such a phenomenon has been observed based on direct or radiological observations before and after but not during the event. We report 2 cases where there was spontaneous necrosis of colonic polyps seen on endoscopy and confirmed by histology.

CASE REPORT

Case 1

A 64 year old man was initially noted on a screening flexible sigmoidoscopy to have a 1cm pedunculated polyp in the sigmoid colon figure 1 A. Polypectomy was deferred, and the patient was scheduled for a complete colonoscopy and polypectomy 31 days later. At the time of the follow up colonoscopy, the same polyp had a black, necrotic appearance and biopsy of the lesion confirmed that the polyp was necrotic (Figure 1B).

Case 2

An 88 year old man underwent colonoscopy for evaluation of hematochezia. At the time of colonoscopy, a 5 cm black, mobile mass with a leathery consistency was noted in the sigmoid colon figure 2. Biopsies were obtained and India ink was injected into the colonic wall to identify the area for subsequent examination. Histology revealed necrotic tissue. Repeat colonoscopy 6 weeks later revealed a small area of granulation tissue at the site of the tattoo and the previously noted mass was completely absent.

DISCUSSION

We report the first endoscopic evidence that colonic polyps can undergo spontaneous necrosis. These observations are unlikely to be unique, and we report them to draw attention to the appearance of

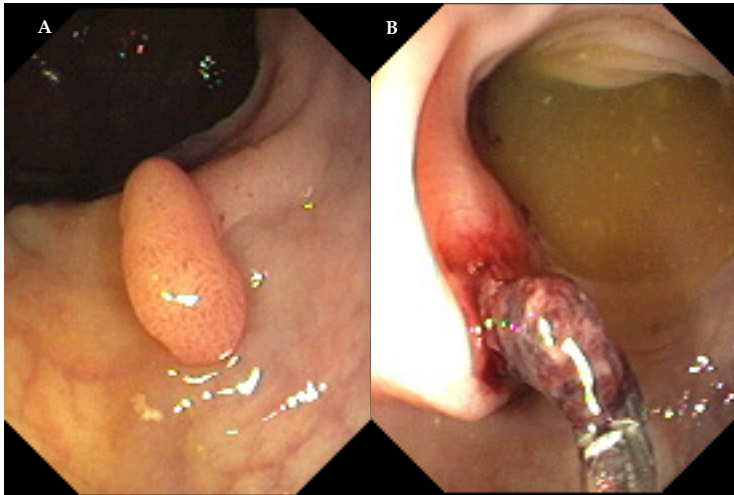


Figure 1 A: Case 1 Initial view of polyp at flexible sigmoidoscopy; B: Case 1 necrotic polyp 31 days later.

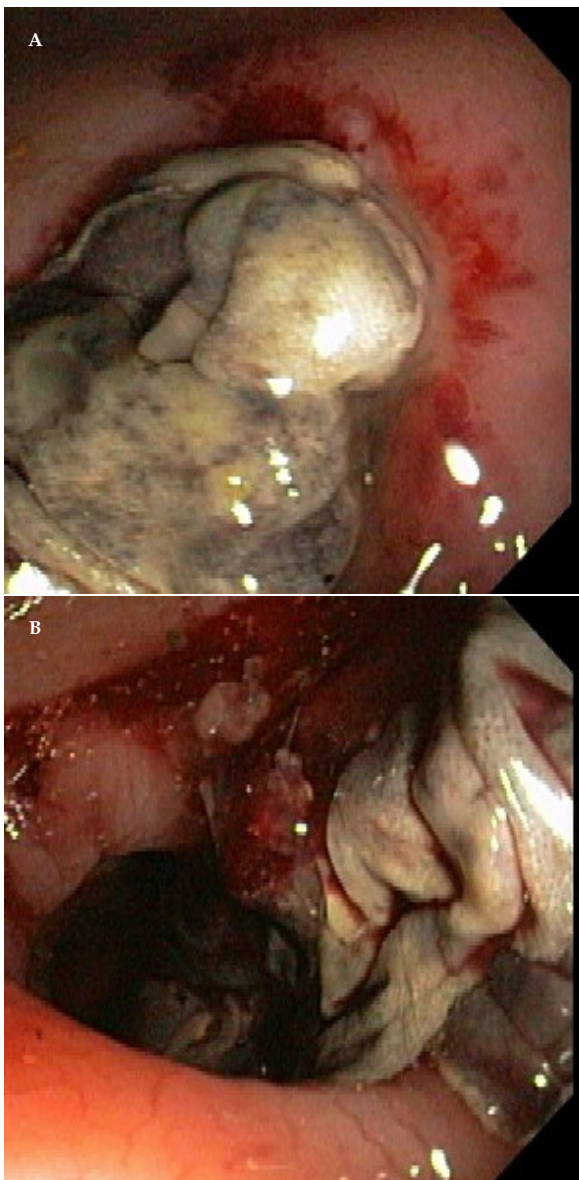


Figure 2 A: Case 2 necrotic sigmoid polyp; B: Case 2 necrotic sigmoid polyp after biopsy.

necrosis of polyps. The polyps were very different in size, but both appear to have been pedunculated. Such a structure could facilitate damage to the blood supply. We do not think that the colonic preparation played a role in this phenomenon, since preparation is uniformly required for colonoscopy.

We reviewed the literature electronically in PubMed, and manually for citations published before 1996 on the spontaneous disappearance of polyps in the gastrointestinal tract detected by radiological or endoscopic means.

In 1956, Anderen and Freiberg^[1] reported spontaneous regression of polyps of the colon in children, and described two such cases. Both the patients under investigation were 5-6 years of age. Decrease in the size of polyps was observed at certain intervals followed by complete regression. Cole and Holden^[2] in 1959 were the first to report post-colectomy regression of adenomatous polyps of the rectum. The authors reported that after total colectomy and ileoproctostomy, regression of the residual rectal polyps occurred. Sheppherd^[3] in 1971 reported on Familial Polyposis Syndrome (FPS) of the colon with reference to regression of rectal polyposis after subtotal colectomy. He studied a family who had established polyposis after subtotal colectomy with ileo-rectal anastomosis. He suggested that phenomenon of spontaneous regression of polyps in the rectal remnant is more frequent than was generally accepted at that time. Feinberg *et al*^[4] reported spontaneous resolution of rectal polyps in patients with familial polyposis following abdominal colectomy and ileorectal anastomosis. They carried out a study on 116 patients who had abdominal colectomy and ileorectal anastomosis. In this cohort, it was observed that spontaneous resolution of polyps occurred in 64% of cases with 38% complete and 26% partial resolution. Among these 55% redeveloped polyps during the follow up period. It was further seen in 9.3 years span of follow up, that 7 patients developed rectal cancer which was more common in patients having innumerable polyps, prior to ileorectal anastomosis. Hofstad *et al*^[5] in 1996 did a longitudinal prospective study of colorectal polyps, by following polyps less than 10 mm for three years in 116 patients who were having yearly colonoscopy. They noted that 5-9 mm polyps showed a tendency to net regression, both for hyperplastic polyps and adenomas. The new adenomas were also significantly smaller and 71% were located in the right colon. They concluded that follow-up of unresected colorectal polyps till 9 mm may be safe, and this growth retardation of medium sized polyps may partly explain the inconsistency between prevalence of polyps and colorectal cancer incidence. Filippakis *et al*^[6] in 2007 reported four cases of spontaneous regression of rectal polyps following abdominal colectomy and ileo rectal anastomosis for Familial Adenomatous Polyposis (FAP) without treatment with sulindac.

Tsukamoto *et al*^[7] reported that they performed upper gastrointestinal studies on 88 patients. In two patients the polyps disappeared, and in two more a decrease in size was noted over a period of 2 to 22 months. However the authors were not able to establish any obvious reason for such spontaneous disappearances. All these cases were about women of ages between 36 and 62 years. In another report, Iida *et al*^[8] reported spontaneous disappearance of fundic gland polyposis from three Japanese female patients over a period of 9 to 34 months. In 2003, Nakajima *et al*^[9], also reported a case of autoamputation of a gastric polyp that was observed endoscopically just before and after autoamputation in a 61-year-old woman with a hyperplastic polyp in the gastric antrum. She had presented with hematemesis, and emergency gastroscopy revealed a

bleeding point near the polyp; gastroscopy the next day revealed the polyp had disappeared.

It is widely accepted that adenomas are the precursors to adenocarcinoma based on the observations of Jackman and Mayo^[10] and followed up by Morson^[11]. However the majority of adenomatous polyps fail to develop overt malignancy. The reasons behind this failure of progression are still not clear. We suggest that at least some may spontaneously necrose due to occlusion or strangulation of the blood supply. We do note that both polyps had endoscopically visible cuffs of erythema at their base. This may be due to the necrosis and secondary infection or related to the primary process causing necrosis. Whatever the causation of the necrosis, we present the first visual and histological evidence for this process. It is clearly a rare event, occurring twice in an estimated 30,000 colonoscopies we performed over a 9 year period at our institution. However it is likely that this phenomenon has been seen by other endoscopists and not reported. The chances of seeing this event is small since the duration of the necrosing process is only a few days and requires the coincidence of concurrent colonoscopy.

In summary, we report for the first time the visualization of two cases of the spontaneous necrosis of colonic polyps. Such a process may account for the failure of some polyps to progress to adenocarcinoma.

ACKNOWLEDGMENTS

Anisha Varma-Wilson MD, Initial draft of manuscript. Edition of paper and final review; Roger Mitty MD, Collection of data. and edition of paper and final review; David Cave, MD, PhD, Collection of data. Overall supervision of publication, and final review of paper. Bilal Gondal. MD, MRCSI, Analysis of data, preparation of final draft of the manuscript with electronic and literature review, Corresponding author.

CONFLICT OF INTERESTS

There are no conflicts of interest with regard to the present study.

REFERENCES

- 1 Andren L, Frieberg S. Spontaneous regression of polyps of the colon in children. *Acta Radiologica* 1956; **46(3)**: 507-510. [PMID: 13372375 DOI: 10.3109/00016925609171441]
- 2 Cole JW, Holden WD. Postcolectomy regression of adenomatous polyps of rectum. *Arch Surgery* 1959; **79**: 385-392. [PMID:

- 13811118 DOI: 10.1001/archsurg.1959.04320090033005]
- 3 Shepherd JA. Familial polyposis of the colon with special reference to regression of rectal polyposis after subtotal colectomy. *Brit J Surgery* 1971; **58**: 85-91. [PMID: 5548512 DOI: 10.1002/bjs.1800580202]
- 4 Feinberg SM, Gagelman DG, Sarre RG, McGannon E, Fazio VW, Lavery IC, Weakley FL, Easley KA. Spontaneous resolution of rectal polyps in patients with familial polyposis following abdominal colectomy and ileorectal anastomosis. *Dis Col & Rect* 1988; **31**: 169-175. [PMID: 2832137 DOI: 10.1007/BF02552541]
- 5 Hofstad B, Vatn MH, Andersen SN, Huitfeldt HS, Rognum T, Larsen S, Osnes M. Growth of colorectal polyps: redetection and evaluation of unresected polyps for a period of three years. *Gut* 1996; **39**: 449-456
- 6 Filippakis GM, Zografos G, Pararas N, Lanitis S, Georgiadou D, Filippakis MG. Spontaneous Regression of Rectal polyps following abdominal colectomy and Ileorectal anastomosis for familial adenomatous polyposis, without sulindac treatment: report of four cases. *Endoscopy* 2007; **39**: 665-668. [PMID: 17611924 DOI: 10.1055/s-2007-966643]
- 7 Tsukamoto Y, Nishitani H, Oshiumi Y, Okawa T. Spontaneous disappearance of gastric polyps: report of four cases. *Am J Roentgenol* 1979; **129**: 893-897. [PMID: 410259 DOI:10.2214/ajr.129.5.893]
- 8 Iida M, Yao T, Watanabe H, Imamura K, Fuyuno S, Omae T. Spontaneous disappearance of fundic gland polyposis: report of three cases. *Gastroenterology* 1980; **79**: 725-728. [PMID: 7409391]
- 9 Nakajima T, Kamano T, Watanabe K, Meguro H, Shibasaki K. A gastric hyperplastic polyp observed endoscopically before and after autoamputation. *Endoscopy* 2003; **35(12)**: 1069-71. [PMID: 14648422 DOI: 10.1055/s-2003-44592]
- 10 Jackman RJ, Mayo CW. The adenoma-carcinoma sequence in cancer of the colon. *Surg Gynecol Obstet* 1951 Sep; **93(3)**: 327-330. [PMID: 14866716]
- 11 Morson B: resident's address. The polyp-cancer sequence in the large bowel 1974. *Proc R Soc Med* 1974 June; **67(6 Pt 1)**: 451-457. [PMID: 4853754]

Peer reviewers: Francis Seow-Choen, Seow-Choen Colorectal Centre, 290 Orchard Road. Paragon #06-06 Singapore; Mitsunori Yamakawa, Professor, Department of Pathological Diagnostics, Yamagata University Faculty of Medicine, 2-2-2 Iida-Nishi, Yamagata 990-9585, Japan; Marco Bustamante, MD, PhD, Endoscopy Unit, University Hospital La Fe, Bulevar Sur, sn, Valencia 46017. Spain; Maha Maher Shehata, Professor, Internal Medicine Department, Gastroenterology and Hepatology Unit, Mansoura University, Specialized Medical hospital, 35516, Mansoura, Egypt.