

Lipids in Parenteral Nutrition on Liver Regeneration After Massive Liver Resection in Rats

Shinn Young Kim, Dong-Goo Kim, Jong-Young Choi, Eun Sun Chung, Myung-Duk Lee

Shinn Young Kim, Dong-Goo Kim, Myung-Duk Lee, Department of Surgery, Seoul St. Mary's Hospital, The Catholic University of Korea, Seoul, South Korea

Jong-Young Choi, Department of Gastroenterology, Seoul St. Mary's Hospital, The Catholic University of Korea, Seoul, South Korea

Eun Sun Chung, Department of Clinical Pathology, Seoul St. Mary's Hospital, The Catholic University of Korea, Seoul, South Korea

Correspondence to: Myung-Duk Lee, Department of Surgery, Seoul St. Mary's Hospital, The Catholic University of Korea, Banpodong 505, Seochogu, Seoul, South Korea

Email: myungdlee@gmail.com

Telephone: +821087417575 Fax: +8225962944

Received: June 23, 2014 Revised: July 18, 2014

Accepted: July 23, 2014

Published online: September 21, 2014

significantly higher in the lipid-containing PN group compared to the lipid-free PN at 48 hours ($p=0.036$) and a similar pattern was noticed for the fatty changes ($p=0.005$).

CONCLUSION: Lipid-containing PN seemed to enhance liver regeneration and increase hepatic steatosis in rats after 75% hepatectomy compared to lipid-free PN within a short-term period.

© 2014 ACT. All rights reserved.

Key words: Liver regeneration; Lipids; Hepatic steatosis; Parenteral nutrition; Hepatectomy

Kim SY, Kim DG, Choi JY, Chung ES, Lee MD. Lipids in Parenteral Nutrition on Liver Regeneration After Massive Liver Resection in Rats. *Journal of Gastroenterology and Hepatology Research* 2014; 3(9): 1233-1237 Available from: URL: <http://www.ghrnet.org/index.php/joghr/article/view/854>

ABSTRACT

AIM: The aim of this study is to elucidate the influence of lipids contained in the parenteral nutrition (PN) solution on hepatic regeneration and steatosis after massive hepatectomy when the animals are fed with total PN.

METHODS: Four groups of young adult rats were used according to the different types of PN and the harvesting time. In each animal, 75% partial hepatectomy and central line insertion via the internal jugular vein for PN were performed. Either lipid-free (PNG) or lipid-containing (PNL) PNs were used, both of which were isocaloric and isonitrogenous formula. Animals were sacrificed after 24 hours or 48 hours of PN infusion. Cell proliferation marker Ki-67, mitotic index, and relative liver weight gain were utilized to assess hepatic regeneration. Hepatic steatosis was evaluated by the histologic findings of the regenerating liver.

RESULTS: Ki-67 index was significantly higher in the lipid-containing PN groups compared to the lipid-free PN groups at 24 and 48 hours ($p=0.023$ and $p=0.008$, respectively). Mitotic index was

INTRODUCTION

Liver regeneration after injury is an orchestrated process induced by internal and external stimuli, involving sequential changes in gene expression, growth factor production, and morphological structure^[1]. Although numerous experimental animal models have been utilized to study the various factors contributing to liver regeneration, much more still remains to be elucidated.

Liver resection has become a popular surgical procedure due to the improvements in preoperative preparation, postoperative care and overall survival. Nutritional therapy is an important part of postoperative care after major hepatectomy. However, only limited factors of nutritional support are known to be influential on hepatic regeneration. Among the three macronutrients, glucose and fat are the main fuels^[2]. Since hepatic steatosis with inflammation is known to impair regeneration^[3,4], a large number of surgeons prefer to use lipid-free parenteral nutrition (PN). On the other hand, excess glucose intake is known to be a risk factor for developing nonalcoholic fatty liver disease and nonalcoholic steatohepatitis^[2,5,6]. Therefore, this

arouses one's curiosity about whether lipid-containing PN would have a beneficial or a harmful effect on regenerating liver after massive liver resection.

This study is to clarify whether the infusion of lipid-containing PN in 75% hepatectomized rats enhances hepatic regeneration and/or hepatic steatosis within a short-term duration of 48 hours.

METHODS

Experimental groups

Young adult male Sprague-Dawley rats, 7–9 weeks of age and weighing 250–400 g, were used for the experiment. Rats were acclimated to laboratory conditions for one week at a constant temperature of 22±5°C with a 12-hour light-dark cycle and fed a standard gamma ray sterilized rodent diet (Pico5053, LabDiet/America) and autoclaved tap water. All of the surgical interventions and presurgical and postsurgical animal care were provided in accordance with the Laboratory Animals Welfare Act, the Guide for the Care and Use of Laboratory Animals and the Guidelines and Policies for Rodent Survival Surgery provided by the IACUC (Institutional Animal Care and Use Committee) of School of Medicine, The Catholic University of Korea. (Approval number: CUMS-2011-0143-03).

Animals were divided into four groups each with five animals according to the different types of PN (lipid-containing or lipid-free) and time of liver harvest (at 24 hours or 48 hours after PN). All rats underwent 75% hepatectomy and insertion of a central line via the internal jugular vein for PN. After hepatectomy, rats had nothing per oral (NPO) except for water, and PN was administered using infusion pumps. Two types of PN formulas were adopted; lipid-free PN, consisting of glucose and amino acids (PNG), and lipid-containing PN (PNL). Each PN solution had an iso-caloric and isonitrogenous composition. After the infusion of each PN formula, animals were sacrificed at 24 hours (PNG1, PNL1) or 48 hours (PNG2, PNL2). At the end of the experiment, blood samples and liver tissues were taken for serum analysis and histology, respectively. The animals that died during the experiment were replaced to fulfill a total number of 5 rats in each group.

Surgical procedures

Rats were anesthetized using isoflurane inhalation. Gentamicin 5 mg/kg was given before starting the operative procedure. After cleansing the abdomen, midline abdominal laparotomy was performed. Seventy-five percent partial hepatectomy including the median lobe, the left lateral lobe, and the right inferior lobe was performed as was reported previously by others^[7,8]. The resected liver tissue was weighed, and a small piece was taken and immersed in 10% neutral buffered formalin. After hemostasis was confirmed, the wound was closed in a single layer. Right internal jugular venotomy was performed to insert a central catheter for PN (polyethylene tube, single lumen, ID 0.58 mm OD 0.965 mm, Jungdo Bio & Plant Co., Korea)^[9]. The catheter was brought out through the subcutaneous tunnel to the back of the neck, and was stabilized using a rodent harness and swivel (Harvard, USA).

During the experimental periods, water was allowed ad libitum, but pellet diet was not allowed at all. After 24 or 48 hours of PN infusion, the animals were anesthetized again. Inferior vena cava was directly punctured for collecting blood samples, then the animal was sacrificed by total hepatectomy. The wet weight of the remnant liver was checked and a piece of the regenerated liver tissue was preserved in formalin.

Preparation of the PN solutions

PN formulas (Table 1) were compounded by the Nutrition Support Team of Seoul St. Mary's Hospital. The prescriptions were the same formulas as those used for clinical patients in our hospital. Each PN solution consisted of an equal amount of total calories and nitrogen, either free of lipids (PNG) or containing lipids (PNL). Lipids were made of soybean oil, which supplies about 40% of the total calories of PNL. The rats were given 120 kcal/kg/day, by continuous infusion at a constant rate at room temperature using a syringe pump (STC-523, Terumo, Japan).

Table 1 Parenteral nutrition solutions.

	PNG ¹	PNL ²
Dextrose (50% DW)	50 mL	30 mL
Amino acid (Freemine 8.5%)	50 mL	50 mL
Lipid (20% Intralipose)	None	20 mL
Nitrogen (g)	0.68	0.68
Nonprotein calories to nitrogen ratio (NPC:N)	147:1	147:1
Kcal/mL	1	1

¹ A mixture of glucose and amino acids in PN; ² A mixture of glucose, amino acids and lipids in PN

Assessment of liver regeneration

Ki-67 index, mitotic index, and relative liver weight gain were utilized as the parameters of liver regeneration. The resected liver tissue was embedded in a paraffin bloc, cut in thin sections (5 µm thick), and processed for mounting on a slide as usual. One section was specially stained for Ki-67 antibodies (rabbit polyclonal anti-rat Ki-67 antibodies, Abcom) for the evaluation of the cell proliferation rate of the regenerating liver tissue. Another specimen was stained with hematoxylin and eosin (H and E) for histologic measurements of mitotic index and fatty degeneration. Ki-67 index was expressed as the percentage of stained cells per total cells counted in 10 consecutive high-power fields (×40)^[10]. Mitotic index (MI) was calculated by dividing the mitotic cell count determined in 30 consecutive high-power fields (×40) by the total cell number on the H and E staining and was expressed as the number of mitotic figures per 1,000 cells^[11]. The wet weight of the 75% removed liver tissue and the remnant regenerated liver after PN were measured. Liver regeneration rate (%) was calculated as $100 \times [C - (A - B)] / A$, where A is the estimated total liver weight at the time of partial hepatectomy, B is the resected liver weight, and C is the weight of the remnant regenerated liver at the end of the experiment^[12].

Assessment of hepatic fatty degeneration

Through the microscopic examination of the H&E stained slides, macrovesicular and microvesicular fatty changes were graded from 0 to 3 as was previously reported^[13]: absent or minimal (score 0, <5% hepatocytes involved), mild (score 1, 5–33% hepatocytes involved), moderate (score 2, 33–66% hepatocytes involved), or severe (score 3, >66% hepatocytes involved).

Serum chemical analysis

The blood samples were centrifuged and the serum was stored for analysis of aspartate aminotransaminase (AST), alanine aminotransaminase (ALT), lactate dehydrogenase (LDH), total bilirubin, total cholesterol, triglycerides, and glucose.

Statistical analysis

Statistical analysis was performed using SPSS ver. 18.0. All values were expressed as mean±standard deviation (SD). Differences between the groups were compared using the Mann-Whitney U test and $p < 0.05$ was considered to be statistically significant.

RESULTS

Hepatic regeneration

1.1 Ki-67 index: The status of liver regeneration with each PN solutions after 24 and 48 hours of hepatectomy is shown in Table 2. Ki-67 index was significantly higher in the PNL groups compared to the PNG groups. After 24-hour infusion of lipid-free PN (PNG1), Ki-67 index was minimal ($18 \pm 8.36\%$, Figure 1A) but in lipid-containing PN (PNL1), Ki-67 staining was observed in less than half of the cells ($42 \pm 16.04\%$, Figure 1C, $p=0.023$). After 48 hours, the difference between the two PN groups became more evident. Little more than half of the cells in the PNG2 group stained positive for Ki-67 antibodies ($57 \pm 9.08\%$, Figure 1B), while almost all of the cells in the PNL2 group were stained positive ($84 \pm 8.22\%$, Figure 1D, $p=0.008$).

Table 2 Status of liver regeneration assessed by Ki-67 index, mitotic index, and liver regeneration rate.

Parameter	24 h			48 h		
	PNG1	PNL1	<i>p</i> -value	PNG2	PNL2	<i>p</i> -value
Ki-67 (%)	18 ± 8.36	42 ± 16.04	0.023	57 ± 9.08	84 ± 8.22	0.008
Mitotic index	2 ± 1.00	2 ± 1.22	0.913	23.8 ± 4.44	34.0 ± 6.52	0.036
Liver regeneration rate (%)	15.67 ± 4.33	16.09 ± 5.82	0.917	23.89 ± 4.21	25.96 ± 3.37	0.346

PNG1, lipid-free PN for 24 hours; PNL1, lipid-containing PN for 24 hours; PNG2, lipid-free PN for 48 hours; PNL2, lipid-containing PN for 48 hours; All values are shown as mean \pm standard deviation.

Mitotic index: Mitotic index at 24 hours was not significantly different between the two PN groups, however at 48 hours, the PNL2 group demonstrated a significantly higher mitotic index than the PNG2 group (34 ± 6.52 vs 23.8 ± 4.44 , $p=0.036$).

Relative liver weight gain: Regardless of whether or not the PN contained lipids, relative liver weight increased progressively according to the intervals of 24 and 48 hours. However, there was no significant difference between the two groups, with or without lipids, at 24 and 48 hours of infusion.

Hepatic steatosis

The H and E staining showing the degree of hepatic steatosis is

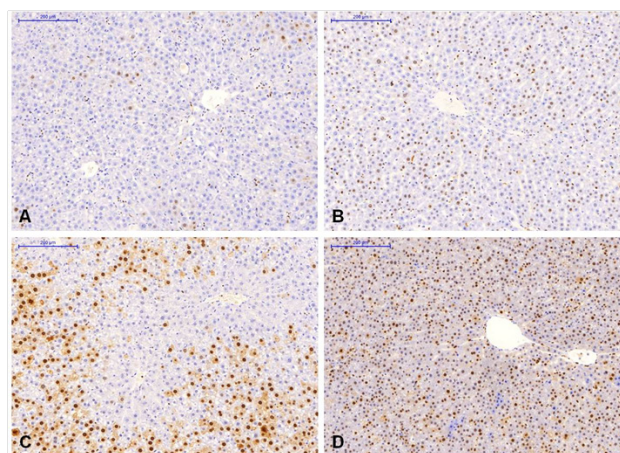


Figure 1 Ki-67 antibodies special staining (magnification $\times 20$).

shown in Figure 2. Histologic findings of the normal liver tissue (Figure 2A and D) did not show any microvesicular fatty changes at all. Fatty changes were not noticed in the lipid-free PN group at 24 hours (Figure 2B), and a few fatty vacuoles and mild (score 1.4 ± 0.5) fatty degeneration were observed at 48 hours (Figure 2C). On the other hand, a minimal amount of fatty change was present at 24 hours (score 0.2 ± 0.4) in lipid-containing PN (E), and more definite diffuse microvesicular and macrovesicular fatty changes were noticed at 48 hours (score 3, Figure 2F). Fat accumulation in the lipid-containing PN group was significantly higher than that in the lipid-free PN group especially at 48 hours of infusion ($p=0.005$).

Serum biochemistry

Most of the biochemical parameters between the two PN groups compared respectively at 24 and 48 hours did not show any significant differences (Table 3). Increased levels of AST and ALT at 24 hours recovered rapidly after 48 hours of administration of PN, and were not influenced by the presence of the lipids. Alanine aminotransferase (ALT) showed a significant difference between the PNG2 group and the PNL2 group (85 ± 16 U/L and 132 ± 38 U/L respectively; $p=0.016$). Cholesterol level was also significantly higher

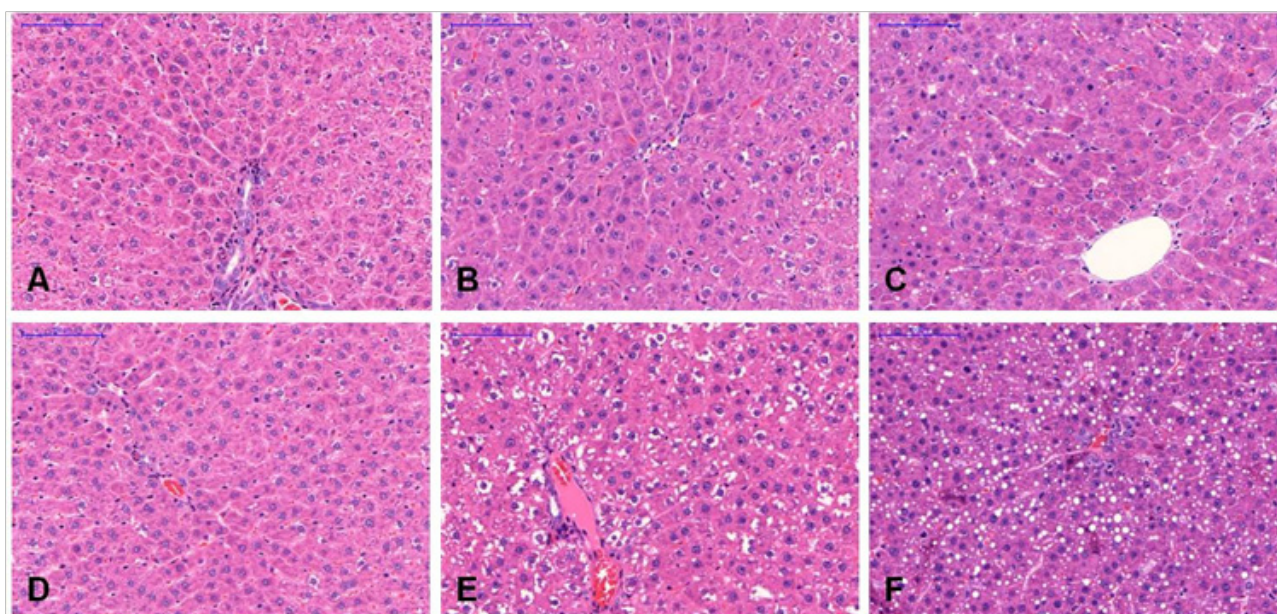


Figure 2 Hepatic steatosis after infusion of PN (magnification $\times 40$).

in the PNL1 and PNL2 groups than that in the PNG1 and PNG2 groups (at 24 hours, 56±7 mg/dL and 32±5 mg/dL, respectively, $p=0.008$; at 48 hours, 73±10 mg/dL and 41±8 mg/dL, respectively, $p=0.008$).

Table 3 Serum levels of biochemical markers after 24 and 48 hours of PN administration.

Parameter	24 h			48 h		
	PNG1	PNL1	<i>p</i> -value	PNG2	PNL2	<i>p</i> -value
AST (U/L)	1212±780	1003±631	0.917	251±69	371±131	0.117
ALT (U/L)	540±420	375±147	0.600	85±16	132±38	0.016
TB (mg/dL)	0.32±0.08	0.34±0.2	0.584	0.18±0.04	0.28±0.08	0.095
LDH (U/L)	1442±632	1464±305	0.754	847±320	1094±579	0.421
TG (mg/dL)	8	7	0.584	19	13	0.095
Cholesterol (mg/dL)	5	7	0.008	8	10	0.008
Glucose (mg/dL)	90	51	0.754	23	48	0.917

All values are shown as mean ± standard deviation.

DISCUSSION

The aim of this study is to observe the effects of lipids that are given intravenously, not enterally, on liver regeneration. Studies on liver regeneration and hepatic steatosis using various experimental models have been undertaken so far, but most of them are concerned about the enteral dietary modulation. There are a few reports that have assessed the effect of intravenous lipid infusion on the development of hepatic steatosis^[14-16]. The ideal composition of intravenous nutrients has been debated. Excess glucose is known to induce hepatosteatosis, inflammation, and nonalcoholic steatohepatitis (NASH)^[17]. On the other hand, lipid infusion is known to provoke PN-associated liver disease accompanied by various degrees of hepatic steatosis, steatohepatitis, hepatocellular injury, and cholestasis^[18]. Therefore, the next question that needs to be answered would be whether the lipid-containing PN helps or inhibits the induction of hepatic regeneration and/or hepatic steatosis in the setting of massive liver resection. In this study, liver regeneration seemed to be enhanced with the use of lipid-containing PN. Ki-67 protein is present in the nucleus during all active phases of the cell cycle and is used as a cell proliferation marker^[19]. After 48 hours of administration of PNL, most of the cells in the centrilobular areas were stained with Ki-67 antibodies, and this result is compatible with the peak time of cell proliferation between 36 to 48 hours after injury^[1]. Both the lipid-free PN groups had lower Ki-67 indices at 24 and 48 hours compared to those in the lipid-containing PN groups, based on which we may suggest that lipid-containing PN enhances hepatocellular proliferation. Mitosis at 24 hours, regardless of the type of PN, was not so prominent, but was remarkably prominent at 48 hours especially after the administration of PNL. This finding is also compatible with the other reports which suggest that liver regeneration based on the evidence of DNA synthesis reaches its peak after 48 hours of hepatectomy^[1,20].

The sequence of the appearance of the markers for liver regeneration after injury has been known to be as follows: Ki-67 index, followed by subsequent mitosis, and then restoration of the liver mass to its original weight in 5 to 7 days^[20]. The above sequence of the regeneration markers was certainly observed in this experiment; however, significant liver weight gain was not so evident because of the limited duration of the experimental period of 48 hours. Further studies with an extended duration of experimental period would be required to achieve this endpoint.

Fatty changes were remarkably prominent in the lipid-containing PN groups compared to the lipid-free groups. At 24 hours,

microvesicular fatty changes were not so evident in both the lipid-containing and the lipid-free PN groups. However at 48 hours, the lipid-containing PN group clearly showed severe microvesicular fatty changes compared to the mere fatty changes in the lipid-free group. This result is contradictory to that in previous reports by other authors, in which adverse effects of hepatic steatosis on liver regeneration were noted^[2,3,21]. However, there are additional reports demonstrating that simple hepatic steatosis might not impair liver regeneration, but it may enhance liver regeneration, particularly in the early phase^[22-27]. Other metabolic factors that cause hepatic steatosis, such as obesity-induced dyslipidemia and insulin resistance, which induce an inflammatory process of the hepatocytes and apoptosis, might contribute to the suppression of liver regeneration^[3]. In the current study, lipid-containing PN groups showed a higher degree of fatty changes as well as a higher degree of liver regeneration.

Even though the quantification of the fatty degeneration of the regenerated liver using histological analysis is still the current standard, it is known to have some limitations especially concerning the discordance between different pathologists^[28]. Recent studies have reported magnetic resonance (MR) techniques to be more accurate and noninvasive for measuring the fat fraction of the liver even in small animals^[29]. However, the technique is complex and not easily accessible, especially considering the cost for the device. In our study, the histology showed fairly distinct differences between the two PN formulas; results after 48 hours could be easily distinguished by even non-experts. However, further studies using MR techniques, if possible, could bring about more accurate quantification of the fatty changes of the regenerated liver.

For this particular study, there are a couple of points that need to be pointed out. First of all, this experiment was performed under distinct conditions of complete NPO and administration of total PN. In clinical settings, only limited conditions are similar to this experimental situation. The second point is that this experiment was performed in rats with under-nutrition status. In rats, the total calorie requirement is thought to be around 250 Kcal/kg/day in general, because of the high metabolic rate of the rodents. However, during the pilot study of this experiment, a PN infusion of 250 mL/kg/day (1 Kcal/mL) after massive hepatectomy was nearly a lethal dose to the rats after only 24 hours. Therefore, the plan was changed and the dose of PN was reduced to 120 Kcal/kg/day, which resulted in a survival rate of more than 95%. However, as a result, this experiment was performed in animals with an obvious under-nutrition status throughout the entire study period. The rats actually showed an approximately 10-20% weight loss compared to their pre-experimental status in only one or two days of this experiment. These findings were not observed in other reports of massive hepatectomy; most of the studies assessed the effects of enteral feeding on liver regeneration after massive hepatectomy, or the effects of PN on liver regeneration in cases without massive hepatectomy. These findings might be related to the reduced hepatic and/or portal circulation (reduced volumes of splanchnic drainage) that causes stasis and congestion. The actual cause of death in the animals was not validated, but overfeeding, overhydration, or relative portal hypertension with consequent splanchnic venous stasis could be suspected. Nonetheless, this experiment was inevitably performed under the particular condition of iatrogenic malnutrition. In addition, fatty degeneration might also be related to malnutrition^[30]. However, there is no report of enhanced liver regeneration with malnutrition in the literatures.

Even though this study did not perform molecular analysis nor assess the signaling factors contributing to liver regeneration, the beneficial effects of the administration of lipid-containing PN on liver

regeneration after massive hepatectomy were clearly demonstrated. In addition, hepatic steatosis was also remarkably prominent in the lipid-containing PN groups, which might bring up a question whether these fatty changes are persistent or temporary and may be resolved by the time complete liver regeneration is achieved. A further study of PN with a longer observation period is required for the answer of this question.

CONCLUSION

In conclusion, the lipid-containing PN seemed to increase liver regeneration after hepatectomy in rats. Hepatic fatty degeneration was also more prominent, requiring further studies on the changes in histology after longer period of experimental time.

CONFLICT OF INTERESTS

There are no conflicts of interest with regard to the present study.

REFERENCES

- 1 Michalopoulos GK. Liver Regeneration. *Science* 1997; **276**: 60-66
- 2 Bechmann LP, Hannivoort RA, Gerken G, Hotamisligil GS, Trauner M, Canbay A. The interaction of hepatic lipid and glucose metabolism in liver diseases. *J Hepatol* 2012; **56**: 952-964
- 3 Vetelainen R, van Vliet AK, van Gulik TM. Severe steatosis increases hepatocellular injury and impairs liver regeneration in a rat model of partial hepatectomy. *Ann Surg* 2007; **245**: 44-50
- 4 Zabielski P, Baranowski M, Blachnio-Zabielska A, Zendzian-Piotrowska M, Gorski J. The effect of high-fat diet on the sphingolipid pathway of signal transduction in regenerating rat liver. *Prostaglandins Other Lipid Mediat* 2010; **93**: 75-83
- 5 Hubscher SG. Histological assessment of non-alcoholic fatty liver disease. *Histopathology* 2006; **49**: 450-465
- 6 Chandrasekaran K, Swaminathan K, Chatterjee S, Dey A. Apoptosis in HepG2 cells exposed to high glucose. *Toxicol In Vitro* 2010; **24**: 387-396
- 7 Emond J, Capron-Laudereau M, Meriggi F, Bernuau J, Reynes M, Houssin D. Extent of hepatectomy in the rat. Evaluation of basal conditions and effect of therapy. *Eur Surg Res* 1989; **21**: 251-259
- 8 Madrahimov N, Dirsch O, Broelsch C, Dahmen U. Marginal hepatectomy in the rat: from anatomy to surgery. *Ann Surg* 2006; **244**: 89-98
- 9 Brenner U, Muller JM, Walter M, Keller HW. A catheter system for long-term intravenous infusion in unrestrained rats. *Laboratory Animals* 1985; **19**: 192-194
- 10 Gerlach C, Sakkab DY, Scholzen T, Dassler R, Alison MR, Gerdes J. Ki-67 expression during rat liver regeneration after partial hepatectomy. *Hepatology* 1997; **26**: 573-578
- 11 Fabrikant JI. The kinetics of cellular proliferation in regenerating liver. *J Cell Biol* 1968; **36**: 551-565
- 12 Selzner M, Clavien PA. Failure of regeneration of the steatotic rat liver: disruption at two different levels in the regeneration pathway. *Hepatology* 2000; **31**: 35-42
- 13 Kleiner DE, Brunt EM, Van Natta M, Behling C, Contos MJ, Cummings OW, Ferrell LD, Liu YC, Torbenson MS, Unalp-Arida A, Yeh M, McCullough AJ, Sanyal AJ, Nonalcoholic Steatohepatitis Clinical Research N. Design and validation of a histological scoring system for nonalcoholic fatty liver disease. *Hepatology* 2005; **41**: 1313-1321
- 14 Meisel JA, Le HD, de Meijer VE, Nose V, Gura KM, Mulkern RV, Akhavan Sharif MR, Puder M. Comparison of 5 intravenous lipid emulsions and their effects on hepatic steatosis in a murine model. *J Pediatr Surg* 2011; **46**: 666-673
- 15 Javid PJ, Greene AK, Garza J, Gura K, Alwayn IP, Voss S, Nose V, Satchi-Fainaro R, Zausche B, Mulkern RV, Jaksic T, Bistrrian B, Folkman J, Puder M. The route of lipid administration affects parenteral nutrition-induced hepatic steatosis in a mouse model. *J Pediatr Surg* 2005; **40**: 1446-1453
- 16 Chen WJ, Yeh SL, Huang PC. Effects of fat emulsions with different fatty acid composition on plasma and hepatic lipids in rats receiving total parenteral nutrition. *Clin Nutr* 1996; **15**: 24-28
- 17 Keim NL, Mares-Perlman JA. Development of hepatic steatosis and essential fatty acid deficiency in rats with hypercaloric, fat-free parenteral nutrition. *J Nutr* 1984; **114**: 1807-1815
- 18 Buchman A. Total parenteral nutrition-associated liver disease. *JPEN J Parenter Enteral Nutr* 2002; **26**: S43-48
- 19 Scholzen T, Gerdes J. The Ki-67 Protein: From the Known and the Unknown. *J Cell Physiol* 2000; **182**: 311-322
- 20 Michalopoulos GK. Liver regeneration. *J Cell Physiol* 2007; **213**: 286-300
- 21 Brookheart RT, Michel CI, Schaffer JE. As a matter of fat. *Cell Metab* 2009; **10**: 9-12
- 22 Cho JY, Suh KS, Kwon CH, Yi NJ, Lee KU. Mild hepatic steatosis is not a major risk factor for hepatectomy and regenerative power is not impaired. *Surgery* 2006; **139**: 508-515
- 23 Sydor S, Gu Y, Schlattjan M, Bechmann LP, Rauen U, Best J, Paul A, Baba HA, Sowa JP, Gerken G, Canbay A. Steatosis does not impair liver regeneration after partial hepatectomy. *Lab Invest* 2013; **93**: 20-30
- 24 Gazit V, Weymann A, Hartman E, Finck BN, Hruz PW, Tzekov A, Rudnick DA. Liver regeneration is impaired in lipodystrophic fatty liver dystrophy mice. *Hepatology* 2010; **52**: 2109-2117
- 25 Thevananther S. Adipose to the rescue: peripheral fat fuels liver regeneration. *Hepatology* 2010; **52**: 1875-1876
- 26 Kawamoto M, Mizuguchi T, Nagayama M, Nobuoka T, Kawasaki H, Sato T, Koito K, Parker S, Katsuramaki T, Hirata K. Serum lipid and lipoprotein alterations represent recovery of liver function after hepatectomy. *Liver Int* 2006; **26**: 203-210
- 27 Newberry EP, Kennedy SM, Xie Y, Luo J, Stanley SE, Semenkovich CF, Crooke RM, Graham MJ, Davidson NO. Altered hepatic triglyceride content after partial hepatectomy without impaired liver regeneration in multiple murine genetic models. *Hepatology* 2008; **48**: 1097-1105
- 28 El-Badry AM, Breitenstein S, Jochum W, Washington K, Paradis V, Rubbia-Brandt L, Puhan MA, Slankamenac K, Graf R, Clavien PA. Assessment of hepatic steatosis by expert pathologists: the end of a gold standard. *Ann Surg* 2009; **250**: 691-697
- 29 d'Assignies G, Fontes G, Kauffmann C, Latour M, Gaboury L, Boulanger Y, Van Beers BE, Soulez G, Poitout V, Tang A. Early detection of liver steatosis by magnetic resonance imaging in rats infused with glucose and intralipid solutions and correlation to insulin levels. *Metabolism* 2013; **62**: 1850-1857
- 30 Skullman S, Ihse I, Larsson J. Influence of malnutrition on regeneration and composition of the liver in rats. *Acta Chir Scand* 1990; **156**: 717-722

Peer reviewers: Paul E Sijens, P.E. Sijens PhD, Radiology, Room G2.19, UMCG, Hanzplein 1, 9713 GZ, Groningen, Netherlands.