

Efficacy of Ursodeoxycholic Acid in Chinese Patients with End-Stage Primary Biliary Cirrhosis

WAN Yue-MENG, YANG Li-Hong, YANG Jun-Hui, XU Ying, YANG Jing, TANG Ying-Mei, XU Zhi-Yuan, LI Yan, LI Yu-Hua, CHENG Yu, ZHOU Wei, CHENG Ju-Bin, ZHU Yan-Ping

WAN Yue-MENG, YANG Li-Hong, YANG Jun-Hui, XU Ying, YANG Jing, TANG Ying-Mei, XU Zhi-Yuan, LI Yan, LI Yu-Hua, CHENG Yu, ZHOU Wei, CHENG Ju-Bin, ZHU Yan-Ping, Hepatology center of the 2nd Affiliated Hospital of Kunming Medical University, Yunnan Province, China

Correspondence to: YANG Jun-Hui, Professor, Hepatology center of the 2nd Affiliated Hospital of Kunming Medical University, Yunnan Province, China

Email: august19840820@126.com

Telephone: +86-0871-65351281 Fax: +86-0871-65361017

Received: August 2, 2014 Revised: September 2, 2014

Accepted: September 2, 2014

Published online: September 21, 2014

ABSTRACT

AIM: To investigate the efficacy of ursodeoxycholic acid (UDCA) in Chinese patients with advanced primary biliary cirrhosis (PBC).

METHODS: 55 PBC in-patients were treated with UDCA(1000mg/day) for 12 days(12.7±3.7 days). The biochemical response to UDCA treatment was evaluated before and after treatment.

RESULTS: Biochemical markers such as ALT, AST, ALP, GGT, TP, ALB, GLO,TBA, TBIL, DBIL were not improved significantly. During the therapy, no severe adverse effects leading to discontinuing the treatment were observed.

CONCLUSIONS: UDCA is not effective for improving liver biochemical tests in patients with advanced PBC for short duration.

© 2014 ACT. All rights reserved.

Key words: Ursodeoxycholic acid; Primary biliary cirrhosis; Biochemical markers

WAN YM, YANG LH, YANG JH, XU Y, YANG J, TANG YM, XU ZY, LI Y, LI YH, CHENG Y, ZHOU W, CHENG JB, ZHU YP.

Efficacy of Ursodeoxycholic Acid in Chinese Patients with End-Stage Primary Biliary Cirrhosis. *Journal of Gastroenterology and Hepatology Research* 2014; 3(9): 1248-1251 Available from: URL: <http://www.ghrnet.org/index.php/joghr/article/view/>

INTRODUCTION

Primary biliary cirrhosis (PBC) is a chronic liver disease characterized by the immune mediated slow progressive destruction of the portal interlobular bile ducts caused by chronic nonsuppurative cholangitis. The loss of bile ducts leads to cholestasis, which further leads to hepatic damage, fibrosis, cirrhosis, and ultimately, liver failure^[1]. Most cases are asymptomatic and only suspected based upon routine liver tests. Those with symptoms typically complain of pruritus and fatigue^[2]. Clinical features of PBC include female predominance, fatigue, pruritus, jaundice, liposoluble vitamin deficiency and portal hypertension^[3]. Biochemical features of PBC include preferentially elevated serum alkaline phosphatase(ALP),g-glutamyl transpeptidase(g-GT), positive serum anti-mitochondrial antibodies (AMA) and increased levels of immunoglobulin M (IgM). It is associated with such autoimmune disorder as thyroid dysfunction, Sjögren's syndrome, Raynaud's disease and inflammatory bowel disease^[4].

Ursodeoxycholic acid (UDCA) is the only Food and Drug Administration (FDA)-approved drug and the first-line medication for the treatment of PBC^[5]. UDCA administration may improve liver function, and a meta-analysis study demonstrates that UDCA administration can delay the histological progression in early-stage PBC^[6]. PBC patients with complete biochemical response to UDCA therapy have similar life expectancy to that of the matched control population^[7]. However, there are few studies about the efficacy of UDCA on Chinese patients with end-stage PBC(Child-pugh B). The current study was undertaken to observe the efficacy of UDCA on Chinese patients with PBC at a dose of 1,000mg/day.

METHODS

Patients

62 Chinese Patients (9 males and 53 females) diagnosed and treated in Hepatology Center of the 2nd Affiliated Hospital of KunMing Medical University from June 2013 to February 2014 were enrolled in this study and 7 patients (6 females and 1 male) diagnosed as overlap syndrome (PBC plus autoimmune hepatitis) were excluded from this study. All patients were diagnosed as PBC following the American Association for the Study of Liver Diseases Practice Guidelines if two of the following criteria were met: (1) biochemical evidence of cholestasis based mainly on ALP elevation; (2) detection of AMA; (3) histological findings of nonsuppurative destructive cholangitis and destruction of interlobular bile ducts^[8]. Hepatitis virus infection, alcohol, drug and other etiology had been excluded.

Study Design

All patients ($n=55$) were treated with UDCA (1,000 mg/day) for at least 8 days (range 8-19 days) until they were discharged from hospital. Before and after UDCA therapy, blood samples were collected in the morning before breakfast after an overnight fasting, and immediately sent to clinic laboratory department for analysis. In this study, most patients (48/55) were treated in our department before and reports of liver biopsy carried out before this study and concluded as consistent to primary biliary cirrhosis by pathology department of KunMing medical university were reviewed. All enrolled patients were evaluated according to the Child-Pugh score and were treated with UDCA at a dose of 1000mg/day and other symptomatic treatment for at least 8 days (mean 12.7 days, range 8-19 days). Informed consent was obtained from all subjects and the study protocol was approved by the Ethics Committee of KunMing Medical University.

Statistical analysis

All analyses were performed using SPSS 17.0 (SPSS Inc., Chicago, IL, USA). Data were expressed as mean±standard deviation (SD). The statistical analysis was completed using paired-samples t-test. A P value < 0.05 was considered as statistically significant.

RESULTS

In this study, the median age of all patients was 60 years, with a range of 37-82 years, female patients with PBC were more common, accounting for 85.5% (47 females and 8 males). 45 patients were AMA-positive (81.8%). Previous liver biopsy reports were available in 48 patients (87.27%), with a Ludwig's classification of II, III and IV in 15, 12 and 21 patients, respectively^[9]. 33 patients in this study were graded as B, 10 patients as A and 12 as C according to Child-Pugh score (Table 1).

Serum ALT levels decreased significantly after UDCA treatment for at least 8 days ($p<0.05$). However, ALT level of most patients with advanced PBC were normal in this study. There was no significant change in AST ($p>0.05$), ALP ($p>0.05$) and GGT ($P>0.05$) levels after UDCA treatment (Table 2). Total bilirubin (TBIL, $p>0.05$) and direct bilirubin (DBIL, $p>0.05$) levels were not improved significantly, either. After UDCA treatment, TP and ALB levels were slightly increased ($p>0.05$), and GLO as well ($p>0.05$) (Table 2).

When stratified by Child-Pugh score, similar results were observed, namely there was no significant improvement of biochemistry after UDCA treatment in patients scored as A (Figure 1), B, C (data not

Table 1 Characteristics of all patients with PBC in this study.

Gender	Female ($n=47$)	Male ($n=8$)
Age	Median: 60 years	Range: 37-82 years
AMA-positivity	Positive ($n=45$)	Negative ($n=10$)
Histological stage	II ($n=15$),	III ($n=12$), IV ($n=21$)
Child-Pugh score	A ($n=10$),	B ($n=33$), C ($n=12$)

Table 2 Biochemical markers of PBC patients in this study.

Laboratory data	Before UDCA treatment	After UDCA treatment	t value	P value
TP (g/l)	62.73±9.96	63.99±8.94	-0.578	0.575
ALB (g/l)	28.43±6.71	29.40±4.91	-0.813	0.434
GLO (g/l)	34.30±7.52	36.69±8.29	-0.251	0.807
ALT (U/L)	25.75±13.99	20.50±11.29	3.169	0.009
AST (U/L)	47.42±20.60	45.83±21.12	0.794	0.444
ALP (U/L)	180.64±73.72	172.17±94.44	-0.408	0.692
GGT (U/L)	78.73±58.27	97.42±60.89	-1.559	0.15
Total bile acid (umol/L)	68.61±80.29	105.47±114.46	-1.376	0.196
Total bilirubin (umol/L)	41.86±28.57	49.28±42.03	-1.002	0.338
Direct bilirubin (umol/L)	21.14±18.75	32.64±29.17	-2.046	0.065

shown).

In this study, all patients tolerated UDCA at a dose of 1,000mg/day well. No one complained of any new symptoms associated with UDCA, such as hair thinning, diarrhea.

DISCUSSION

UDCA is a bile acid, naturally comprising 2% of human bile. Treatment with UDCA improves serum biomarkers such as bilirubin, ALP, GGT, alanine aminotransferase, aspartate aminotransferase, cholesterol and IgM levels in patients with early PBC^[11]. UDCA improves 10-year survival^[12] and delays the progression of hepatic fibrosis in early-stage disease^[13] and the development of esophageal varices in patients with PBC^[14].

Due to the fact that more than half of patients diagnosed today are asymptomatic at diagnosis, most patients do not seek medical service until the disease has progressed to the advanced stage in China. So we are more confronted with patients with end-stage PBC as doctors in China. Since it is reported that UDCA can lower biliary enzymes such as ALP and GGT, clinically we use it to manage all PBC patients with increased ALP and/or GGT. In this study, we only analyzed 55 PBC patients whose clinical data were available, retrospectively.

Previous studies showed that UDCA can improve serum levels of biliary enzymes and IgM, and may slow the histological progression to liver cirrhosis in the management of early-stage PBC^[13]. In spite of giving higher dose of UDCA, our study, however, showed that UDCA can not improve the biochemistry of patients with PBC. ALP level of 15 patients even increased after UDCA treatment for at least 12 days (range 12-19 days). The underlying reasons may be as following: First, all subjects in this study were patients with advanced stage of PBC, which is consistent with a study in Spain^[15]. Second, UDCA seems to be a slow-acting agent as indicated by most studies which observe the subjects taking UDCA for at least one year. Third, the sample size was relatively small.

The mechanisms of the anti-cholestatic and anti-inflammatory effects of UDCA have been reported to be due to the activation of the canalicular bile salt export pump (BSEP), canalicular multidrug resistance protein 3 (MDR3; ATP-binding cassette transporter B4 (ABCB4) and basolateral multidrug resistance-associated protein 4 (MRP4)^[16]. So we infer that due to chronic nonsuppurative cholangitis, bile ducts in patients with advanced PBC were severely

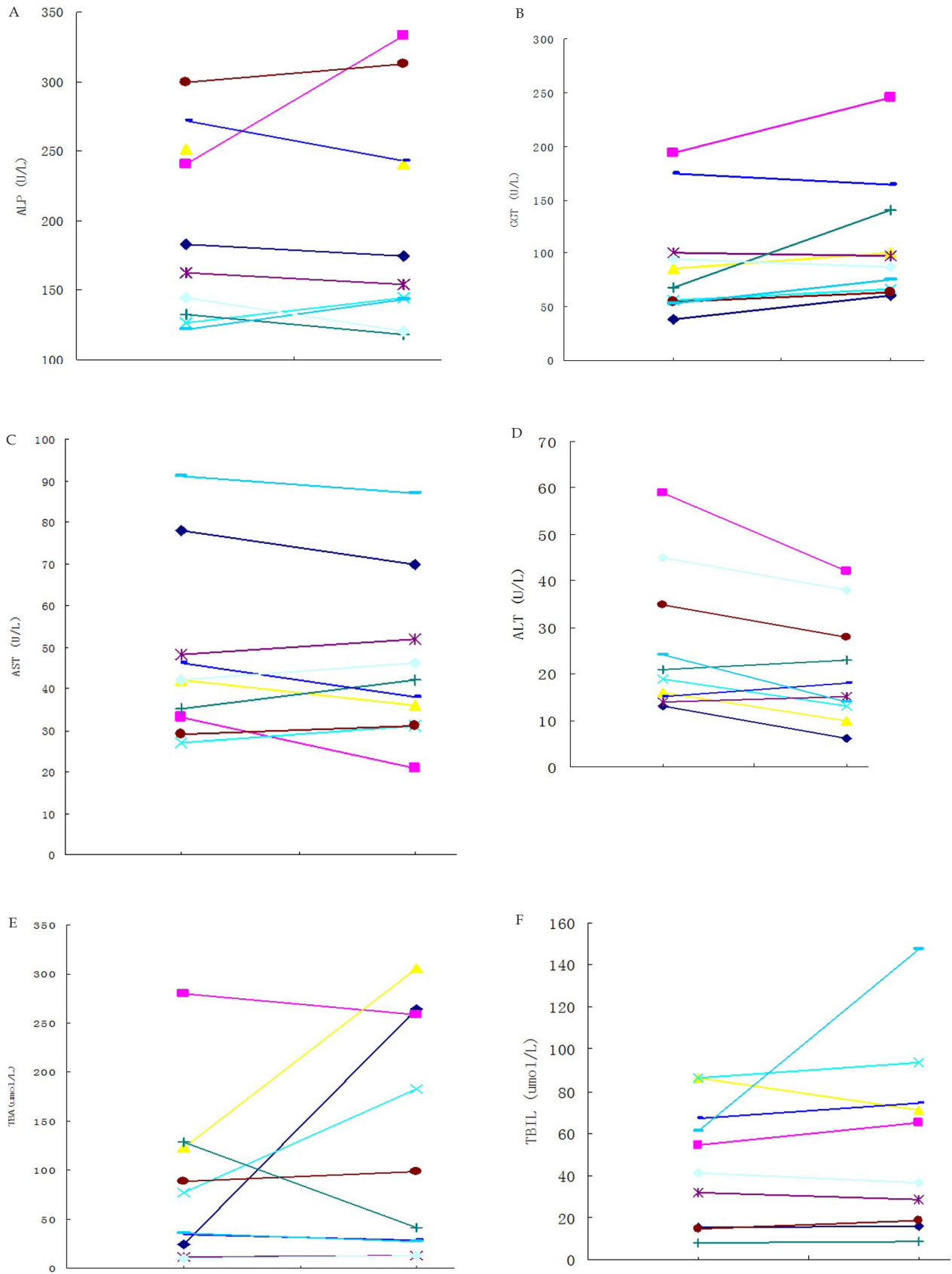


Figure 1 Serum biochemical markers of 10 PBC patients graded as A by Child-Pugh score (Before and after UDCA treatment, each line represents a patient).

destroyed, UDCA can no longer exert its anti-cholestatic effects by activating BSEP, MRP4 or ABCB4.

In conclusion, UDCA is well tolerated in most PBC patients and is not effective in patients with advanced stage PBC for short duration. Large sample, randomized control trials in the future are needed to confirm the efficacy of UDCA on patients with advanced stage PBC as far as serum biochemistry and overall survival concerned.

ACKNOWLEDGMENTS

We thank all the doctors providing clinical data of PBC patients managed by them. This study was instructed and supported by professor YANG Jin-Hui. The data was collected and statistically analyzed by Wan Yue-MENG, and the manuscript was also drafted by Wan Yue-Meng. The manuscript was reviewed and revised by Doctor YANG Li-Hong. We have settled conflict of interest.

REFERENCES

- Kaplan MM, Gershwin ME. Primary biliary cirrhosis. *N Engl J Med* 2005; **353**:1261-1273
- Prince M, Chetwynd A, Newman W, Metcalf JV, James OF: Survival and symptom progression in a geographically based cohort of patients with primary biliary cirrhosis: follow-up for up to 28 years. *Gastroenterology* 2002, **123**:1044-1051
- Xiao Feng HAN, Qi Xia WANG *et al.* Efficacy of fenofibrate in Chinese patients with primary biliary cirrhosis partially responding to ursodeoxycholic acid therapy. *Journal of Digestive Diseases* 2012, **13**: 219-224
- Mayo MJ, Jenkins RN, Combes B, Lipsky PE: Association of clonally expanded T cells with the syndrome of primary biliary cirrhosis and limited scleroderma. *Hepatology* 1999; **29**: 1635-1642
- Ikegami T, Matsuzaki Y. Ursodeoxycholic acid: mechanism of action and novel clinical applications. *Hepatol Res* 2008; **38**:123-131
- Shi J, Wu C, Lin Y, Chen YX, Zhu L, Xie WF. Long-term effects of mid-dose ursodeoxycholic acid in primary biliary cirrhosis: a meta-analysis of randomized controlled trials. *Am J Gastroenterol* 2006; **101**: 1529-1538
- Corpechot C, Abenavoli L, Rabahi N *et al.* Biochemical response to ursodeoxycholic acid and long-term prognosis in primary biliary cirrhosis. *Hepatology* 2008; **48**: 871-877
- Lindor KD, Gershwin ME, Poupon R, Kaplan M, Bergasa NV, Heathcote EJ; American Association for Study of Liver Diseases. Primary biliary cirrhosis. *Hepatology* 2009; **50**: 291-308
- Ludwig J, Dickson ER, McDonald GS: Staging of chronic nonsuppurative destructive cholangitis (syndrome of primary biliary cirrhosis). *Virchows Arch. A Pathol Pathol Anat* 1978; **379**: 103-112
- Pugh RN, Murray-Lyon IM, *et al.* "Transection of the oesophagus for bleeding oesophageal varices". *The British journal of surgery* 1973; **60(8)**: 646-649
- Pares A, Caballeria L, Rodes J, Bruguera M, Rodrigo L, Garcia-Plaza A, Berenguer J, Rodriguez-Martinez D, Mercader J, Velicia R: Longterm effects of ursodeoxycholic acid in primary biliary cirrhosis: results of a double-blind controlled multicentric trial. UDCA-Cooperative Group from the Spanish Association for the Study of the Liver. *J Hepatol* 2000; **32**: 561-566
- Poupon RE, Bonnand AM, Chretien Y, Poupon R: Ten-year survival in ursodeoxycholic acid-treated patients with primary biliary cirrhosis. The UDCA-PBC Study Group. *Hepatology* 1999; **29**:1668-1671
- Corpechot C, Carrat F, Bonnand AM, Poupon RE, Poupon R: The effect of ursodeoxycholic acid therapy on liver fibrosis progression in primary biliary cirrhosis. *Hepatology* 2000; **32**: 1196-1199
- Lindor KD, Jorgensen RA, Therneau TM, Malinchoc M, Dickson ER: Ursodeoxycholic acid delays the onset of esophageal varices in primary biliary cirrhosis. *Mayo Clin Proc* 1997; **72**: 1137-1140
- Pares A, Caballeria L, Rodes J: Excellent long-term survival in patients with primary biliary cirrhosis and biochemical response to ursodeoxycholic Acid. *Gastroenterology* 2006; **130**: 715-720
- Marschall HU, Wagner M, Zollner G, Fickert P, Diczfalusy U, Gumhold J, *et al.* Complementary stimulation of hepatobiliary transport and detoxification systems by rifampicin and ursodeoxycholic acid in humans. *Gastroenterology* 2005; **129**: 476-485

Peer reviewer: Rodrigo Liberal, Dr, Institute of Liver Studies, King's College London School of Medicine at King's College Hospital, 3rd Floor Cheyne Wing King's College Hospital Denmark Hill, London, SE5 9RS, UK.