

Head and Neck Diseases and Disorders Causing Oropharyngeal Dysphagia

Nicole Pizzorni, Daniela Ginocchio, Francesco Mozzanica, Luca Roncoroni, Letizia Scarponi, Antonio Schindler

Nicole Pizzorni, Francesco Mozzanica, Luca Roncoroni, Letizia Scarponi, Antonio Schindler, Department of Biomedical and Clinical Sciences "L. Sacco", University of Milan, Milan, Italy

Daniela Ginocchio, Department of, Audiology Unit, University of Milan, Milan, Italy

Correspondence to: Antonio Schindler, MD, Department of Biomedical and Clinical Sciences "L. Sacco", Via GB Grassi 74, University of Milan, Milan, Italy

Email: antonio.schindler@unimi.it

Telephone: +39 02 3043526

Received: January 31, 2014

Revised: July 9, 2014

Accepted: July 12, 2014

Published online: October 21, 2014

ABSTRACT

The swallowing mechanism requires the coordinated movements of several structures of the head and neck region; it is therefore not surprising that diseases of the mouth, pharynx, larynx and cervical spine can lead to dysphagia. Although each disorder per se is relatively rare, the combination of all clinical situation represents an important group of clinical conditions that can not be overlooked. Self-perception of dysphagia is usually high as the impairment often involves the oral phase or is due to pain or obstruction. This review focus on the most common and important clinical conditions of the head and neck districts associated with dysphagia: head and neck cancer and impairments associated with its treatment, Zenker's diverticulum, head and neck infections, cervical spine disorders and cranial nerves deficits. Head and Neck disorders may impair swallowing through different mechanisms; symptoms, dysphagia severity, treatment options and prognosis for this variety of clinical situations vary enormously. Clinicians involved in the management of oro-pharyngeal dysphagia should be aware of the different diseases of this area and build teams or connections with different medical specialists in order to guarantee the best treatment option for each patient.

© 2014 ACT. All rights reserved.

Key words: Cancer, Zenker's diverticulum; Dysphagia; Larynx; Pharynx; Cervical osteophytes

Pizzorni N, Ginocchio D, Mozzanica F, Roncoroni L, Scarponi L, Schindler A. Head and Neck Diseases and Disorders Causing Oropharyngeal Dysphagia. *Journal of Gastroenterology and Hepatology Research* 2014; 3(10): 1272-1280 Available from: URL: <http://www.ghrnet.org/index.php/joghr/article/view/884>

INTRODUCTION

The swallowing mechanism requires the coordinated movements of several structures of the head and neck region^[1]; it is therefore not surprising that diseases of the mouth, pharynx, larynx and cervical spine can lead to dysphagia, that is the impairment in bolus transit from the mouth to the stomach^[2]. Different mechanism may come into play in dysphagia due to head and neck diseases and disorders: (1) sensory-motor mechanisms, characterized by reduced sensibility or reduced dexterity, range of motion and muscle strength; (2) mechanical mechanisms, characterized by obstruction in bolus transit; (3) defective protection of the lower airways, characterized by reduced movement or disrupted structures of the larynx; (4) pain, usually due to mucosal inflammation or infection^[3]. Self-perception of dysphagia is usually high as the impairment often involves the oral phase or is due to pain or obstruction; this criterion does not apply to dysphagia associated to silent aspiration only which could occur after laryngeal surgery^[4].

Because of the different anatomic structures it is difficult to fully cover all the diseases and disorders of the head and neck area that impact on swallowing; this review focus on the most common and important clinical conditions of the head and neck districts associated with dysphagia: head and neck cancer and impairments associated with its treatment, Zenker's diverticulum, head and neck infections, cervical spine disorders and cranial nerves deficits.

HEAD AND NECK CANCER

Head and neck cancers represent the 3.2% of the newly diagnosed

tumors^[5]. Their incidence and prevalence vary by geographical area, age, gender and site of the tumor. In particular, the tumor incidence rate per 100,000 ranges from 7.0 to 11.4 for the oropharynx, from 7.0 to 13.4 for the hypopharynx, from 9.3 to 12.7 for the tongue and oral cavity and from 16.0 to 25.5 for the larynx. The 84-91% of the head and neck cancers are squamous cell carcinoma and they often metastasize to the neck lymph nodes^[6]. Treatment options for head and neck tumors generally have a curative intent and are represented by surgery and chemo-radiotherapy; recently, organ-sparing protocols combining radiotherapy, chemotherapy and surgery are increasingly used^[7-9]. Dysphagia and its complications (aspiration pneumonia and malnutrition) are common in patients with head and neck cancer, significantly impacting on quality of life^[10-12].

Dysphagia can be due to the tumor itself, to its treatment or, more rarely, to associated diseases, such as Parkinson's or stroke. Signs of dysphagia prior to treatment were reported in up to 59% of the patients, because of the obstruction, of the nerve involvement and of the pain caused by the tumor; in particular, dysphagia occurs more often in pharyngeal tumors than in oropharyngeal or laryngeal malignancies and it worsens significantly with increased tumor stage^[13-16]. Pre-treatment swallowing alterations vary among head and neck subsite. Aspiration and pharyngeal impairment occur more often in patients with hypopharyngeal and laryngeal cancer; esophageal impairment is more frequent in patients with hypopharyngeal cancer^[13,15]. On the other hand, a longer oral and pharyngeal transit time and a greater amount of oral and pharyngeal residue are typical of oral and pharyngeal tumors^[14].

Consequences of surgical treatment for Head and Neck Cancer

A large number of surgical procedures are available to treat head and neck cancer, depending on the tumor site, on its extension and on the patient's age and general conditions. Over time, patients treated primarily with surgical approach usually develop compensatory strategies and function was observed to improve thanks to the healing process and to the sensory recovery; however, the anatomic modifications consequent to surgery may cause different degrees of swallowing impairment. Amplitude and site of resection are the main factors influencing the severity of dysphagia and the recovery time^[17-19].

After marginal glossectomy or hemiglossectomy, swallowing impairment is mainly characterized by alterations of oral control and of lingual peristalsis, due to clumsiness in the tongue movement and difficulties in triggering the swallowing reflex. Anyway, dysphagia is usually temporary^[20]. When the lingual resection exceeds 50% of the tongue, lingual peristalsis and control of bolus in mouth are often severely reduced.

After resection of the anterior floor of the mouth, swallowing is usually preserved^[21]. When the tongue is sutured into the surgical defects, the patient may experience difficulties in oral control, in lingual peristalsis and in mastication. After lateral mouth floor resection involving the base of the tongue, lingual propulsion and oral transit time may be reduced and bolus may collect in the lateral sulcus and/or in the crevices, leading to severe dysphagia.

After surgery of oro-pharyngeal tumors, both oral and pharyngeal phases of swallowing are impaired. In particular, tongue propulsion will be reduced, patients may experience nasal regurgitation, the triggering of swallowing reflex may be delayed and the pharyngeal peristalsis may be reduced, leading to oral and pharyngeal residue. Also cricopharyngeal sphincter difficulties may sometimes arise.

After partial laryngectomies, particularly horizontal partial laryngectomies, significant alterations of swallowing are inevitable

and compensatory mechanisms, lasting several months, are necessary to restore it^[22-24]. Because of the tumor resection, laryngeal anatomy is severely modified and glottis closure impaired (Figure 1). Dysphagia is mainly related to airway protection impairment due to insufficient laryngeal vestibule and/or glottis closure during the pharyngeal phase of swallowing (Figure 2). Moreover, laryngeal sensation is often reduced because of superior laryngeal nerve function impairment; laryngeal elevation and upper esophageal sphincter opening may also be reduced and triggering of swallowing reflex can be delayed.

After total laryngectomy, swallowing is usually well preserved as the respiratory and digestive tracts are entirely separated. Nonetheless, oropharyngeal dysphagia may arise due to pharyngeal-esophageal stenosis, which may occur after large resections or as a consequence of adjuvant radiotherapy. Upper esophageal sphincter spasm may also arise leading to difficulty mainly with solid foods (Figure 3).

Neck dissection is often necessary in head and neck cancer treatment because of the neck metastasis. Neck dissection may impact on swallowing function as several muscular and nerve structure involved in swallowing may be damaged, leading to a

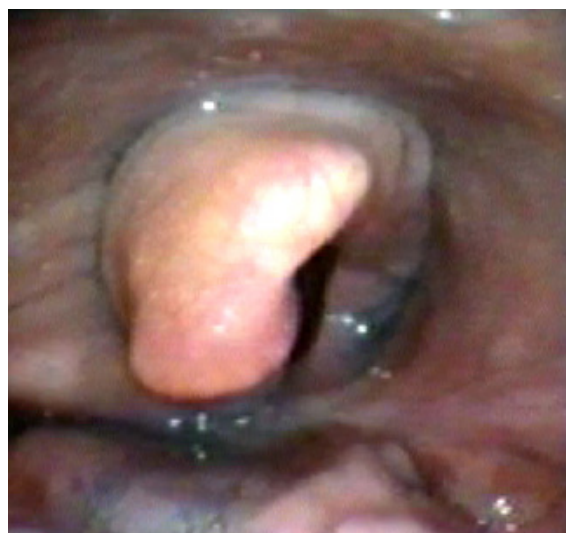

Figure 1 Endoscopic view of the hypopharynx in a patient who underwent supracricoid laryngectomy with crico-hyoido-epiglottopexy; the right arythenoid is visible.

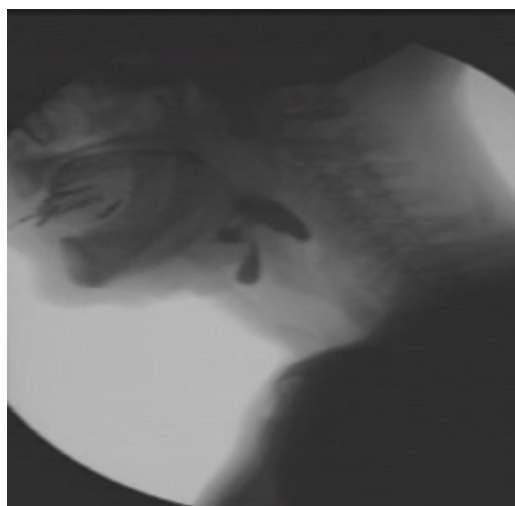

Figure 2 Videofluorographic swallow study with semisolid in a patient who underwent supraglottic laryngectomy; aspiration is clearly visible.

prolonged tube feeding dependence^[25-26]. Swallowing alterations after neck dissection are typically related to recurrent laryngeal nerve injury and suprahyoid muscle resection, causing a lower rest position of the hyoid bone, a decreased hyoid bone elevation and a higher percentage of penetration.

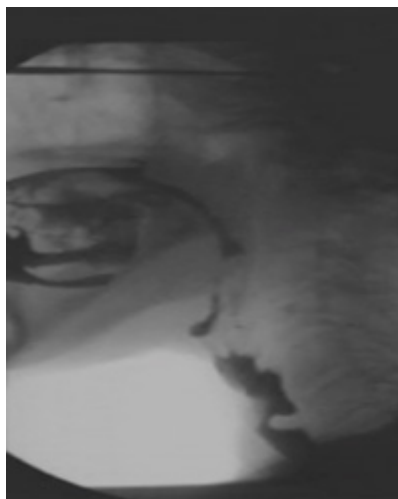

Figure 3 Videofluorographic swallow study with semisolid in a patient who underwent total laryngectomy; a posterior bar with stasis of the barium due to spasm of the upper esophageal sphincter is clearly visible.

Consequences of chemo-radiotherapy for Head and Neck Cancer

Chemo-radiotherapy can be used in the treatment of head and neck cancer with a curative intent, as an adjuvant to surgery or with a palliative intent in order to provide symptomatic relief. The overall survival rate for locally advanced head and neck cancer increased thanks to the application of concomitant chemo-radiotherapy protocols^[27-35]. However, dysphagia is a common complication and may worsen over time^[36-39]. Its incidence varies according to different factors related to the treatment and to the patient, such as total radiation dose, fraction size, radiated volume, interfraction interval, treatment techniques (e.g. intensity modulated radiotherapy), location and size of the primary tumor, age, history of heavy alcohol consumption^[40-41].

Radiation-induced dysphagia has multiple etio-pathogenetic factors involving acute inflammation, oedema, erythema, hyposalivation, fibrosis with consequent neurological and/or muscular injury. In particular, xerostomia, often lasting several years, may impair oral functions because of insufficient wetting and decreased bolus lubrication and significantly impact on patients' perception of dysphagia^[42]. Moreover, different neuromuscular mechanisms of swallowing may be damaged.

Different stages of swallowing are affected by chemo-radiotherapy^[43]. For what it concerns the oral phase, the following anatomic-physiological deficits can be found: reduced mouth opening, reduced range of lingual motion, reduced lingual strength, impaired bolus formation and transport through the oral cavity, prolonged oral transit time and increased oral residue. Impairment of pharyngeal stage can be due to: reduced tongue base posterior movement with consequent reduction of tongue-base contact with the posterior pharyngeal wall, defective velopharyngeal closure, reduced pharyngeal contraction, reduced laryngeal elevation, reduced glottis and laryngeal vestibule closure and reduced opening of the upper esophageal sphincter. Moreover, a sensibility impairment following concomitant chemo-radiotherapy is often reported in literature, leading to a delayed or absent swallowing reflex. Therefore, reduced

bolus clearance, oral and pharyngeal residue and silent aspiration, typically post-deglutition, mostly characterize dysphagia after concomitant chemo-radiotherapy.

Effects of chemo-radiotherapy on swallowing abilities can be life-long^[44]. Pathophysiology of dysphagia is related to the distance from the treatment. Approximately 80% of the patients undergoing a radiation treatment experience acute mucositis, both during treatment and in the first weeks after the treatment^[45]. At this stage, oral mucositis and xerostomia severely impact on oral intake. Over time, the mucositis healing process allows to improve oral intake^[46]. However, oro-pharyngeal deficits persist because of the late toxicity of the pharyngeal-laryngeal mucosa, because of the fibrosis process and because of the neurological impairment. Many years after the chemo-radiation treatment, dysphagia may still occur, probably due to soft tissue fibrosis, peripheral neuropathy and sensibility deficits.

HEAD AND NECK INFECTIONS

A short-term dysphagia, usually caused by mucosal inflammation and swelling, can be related to several infectious diseases; in most of the cases, odynophagia, that is pain during swallowing, is also present and significantly contributes to the swallowing impairment; in most of the cases the infections can be effectively treated and dysphagia resolves. The more common head and neck infections are: candidiasis of the oral mucosa, acute epiglottitis, Ludwig's angina, Vincent's angina, major aphthous ulcer, tonsillitis, peritonsillar abscess, herpes zoster and systemic infectious disorders such as acquired immunodeficiency syndrome and tetanus. Other local infections including tuberculosis, diphtheria and gonorrhoea, that can determine local inflammatory changes responsible of swallowing impairments, are nowadays extremely rare.

Candidiasis: candidiasis is a common opportunistic fungal infection frequently seen in infants and in dental wearers. The disease can occur also in patients with chronic oral steroid therapy, patients with diabetes mellitus or cellular immune deficiency states such as cancer or human immunodeficiency virus (HIV) infection. It is also not uncommon after radiotherapy, use of antibiotics that disrupted the normal oral flora or in patients who have undergone immunocompromising treatments. The pathogen more often responsible for candida infections is *Candida albicans*, a commensal micro-organism found to inhabit in the oral cavity in the majority of healthy individuals. Clinical presentation may vary but odynophagia is frequent and contributes to the genesis of the swallowing impairment. Candidiasis may involve the oral cavity as well as the pharynx and the esophagus.

Tonsillitis and peritonsillar abscess: acute tonsillitis is a common inflammatory process of the tonsillar tissue frequently seen in school-aged children (Figure 4). Both viral and bacterial agents can determine the disease that may lead to inflammatory changes of the mucosal surfaces with secondary pain and dysphagia. Diagnosis of acute tonsillitis is clinical, and it can be difficult to distinguish viral from bacterial infections^[47]. Similarly, abscess formation in the peritonsillar structures such as the tonsils, floor of mouth, buccal space, and retropharynx can also lead to inflammatory changes, oedema, and pain associated with severe dysphagia. Dysphagia is usually severe and mainly related to pain during swallowing. In rare cases stone may arise within the tonsils, leading to dysphagia^[48].

Acute epiglottitis: this rare condition results from an infection of the epiglottis and surrounding structures that may potentially cause an acute airway obstruction. The most common pathogen is *Haemophilus influenzae* type b but also *Streptococcus pyogenes*, *Streptococcus pneumoniae*, *Staphylococcus aureus*, *Herpes simplex*

virus, *Candida albicans* and non-infectious insults, such as thermal damage, may play a role in the genesis of this disease (especially after the introduction of the HIB vaccine)^[49]. Clinical features of acute epiglottitis include stridor, dyspnea, hoarseness, fever, sore throat, odynophagia, dysphagia, drooling, and cervical lymphadenopathy. General malaise and a globus sensation often precede presentation. The progression of the disease in adults is slower and less aggressive than in children. The gold standard for diagnosis is flexible endoscopy of the larynx. Medical and surgical management is focused on maintaining a patent airway and treating the infection.

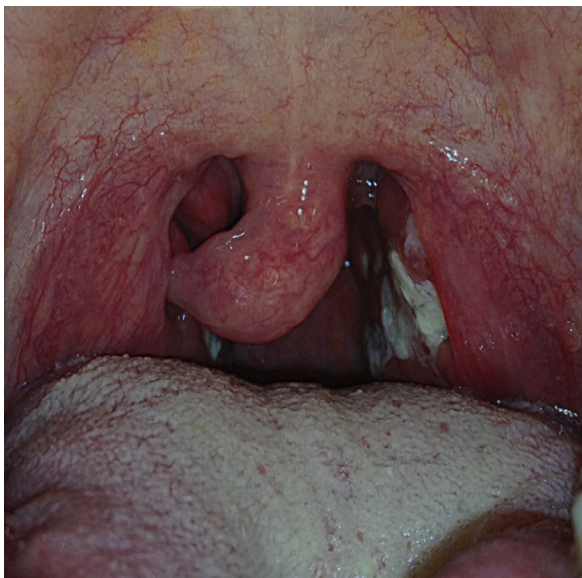

Figure 4 Photo of the oropharynx in a patient with acute tonsillitis.

Ludwig's angina: this potentially fulminant cellulitis of the mouth floor presents an acute onset and spreads rapidly bilaterally affecting the sublingual, submandibular and parapharyngeal spaces. The progressive swelling of the soft tissues and the elevation and posterior displacement of the tongue against the palate and into the hypopharynx, may result in airway obstruction. The majority of cases are related to dental infections (the second and third molars are frequently involved), even if also traumatic events, foreign bodies or spreading from other local infections may be implied^[50]. The bacterial agents more commonly isolated include: *Streptococcus viridans*, *Staphylococcus epidermidis*, *Staphylococcus aureus* and group A β -haemolytic *Streptococcus*. Clinical presentation is usually characterized by progressive difficulty of swallowing, odynophagia, dysphonia, trismus, extra-oral swelling and pain. The swallowing impairment is the presenting symptom in more than half of the patients and is largely due to the oral and pharyngeal oedema. The mortality rate approach 10% and is related to airway compromise (more frequently), pneumonia, mediastinitis, septic shock or empyema^[51]. The diagnosis of Ludwig's angina is made clinically, based on the physical findings of fever, neck and submandibular swelling, as well as elevation of the tongue. Imaging techniques and in particular the CT may be useful in order to determine the extent of the infection and the degree of airway compromise. The management of Ludwig's angina consists of airway stabilization and intravenous antibiotics. Surgery is considered when medical therapy fails or when abscess exists.

Systemic infectious disorders: not infrequently, systemic infectious diseases may determine dysphagia. Swallowing

impairment, for example, can occur in patients with HIV/AIDS. In this case dysphagia can result from weak neuromotor functioning with impairment of the tongue and pharyngeal function and/or from antiretroviral therapy. This latter has known side effects such as anorexia, nausea, dry mouth and mouth sores. In addition, lack of appetite, odynophagia (frequently caused by oral, palatal and oesophageal opportunistic infections as esophageal candidiasis) or aphthous ulcers and change in taste may determine poor oral intake^[52]. For this reason dysphagia management is critical in HIV/AIDS patients in order to maintaining quality of life and safe oral intake.

Tetanus: Tetanus is caused by a spore-forming, gram positive, anaerobic agent. The infectious process presents with trismus, risus sardonicus, muscle rigidity, often seen in the nuchal and pharyngeal musculature, dysphagia, odynophagia and spasms. These latter are overlaid on background rigidity, variable in duration, very painful and can be triggered by auditory, visual, tactile and emotional stimuli^[53]. The diagnosis is made by the clinical presentation (depends on the inoculation site, incubation and the time between the first symptom and the start of spasms) and a history of a prior wound. The course of the disease may be rapid in not vaccinated patients and death can occur by generalized muscle spasms and respiratory failure. The medical treatment is often supportive with the use of sedative agents against the spasms and the removal of the source of infection. In some cases it may be necessary to administer passive human tetanus immunoglobulin, followed by active immunization with the tetanus vaccine.

LARYNGEAL PARALYSIS

Isolated cranial nerve deficits can affect the facial nerve (CN VII), hypoglossal nerve (CN XII), glossopharyngeal nerve (CN IX), vagus nerve (CN X), leading to dysphagia. Facial nerve injury affects the manipulation and control of bolus inwardly oral cavity; hypoglossal nerve deficit leads to poor oral manipulation and difficulty in the transport of the bolus towards the pharynx; glossopharyngeal deficit results in limited bolus propulsion/clearance and delayed trigger of pharyngeal reflex, as a consequence of alteration of tongue base and pharyngeal sensitivity. The Vagus nerve splits into a sensitivity component (superior laryngeal nerve) which provides sensibility to the epiglottis, false vocal folds and pyriform sinus, and a motor division which controls motor skills of laryngeal (recurrent laryngeal nerve) and contributes to the pharyngeal plexus. Vagal nerve deficits determines vocal fold paralysis and poor initiation of swallowing reflex. Vocal fold paralysis can be unilateral or bilateral; in adults with vocal fold palsy most of cases are unilateral^[54]. Central lesions (stroke, intracranial neoplasm, meningitis, head trauma, ect) are more rare than peripheral lesions, which represents more than 90% of the cases and are traumatic/iatrogenic, infectious, neoplastic or idiopathic in origin. Unilateral vocal fold paralysis (UVFP) results in glottal insufficiency, which can determine change in vocal quality, dysphagia and weak cough^[55]. Bilateral vocal fold paralysis (BVFP) is very often caused by iatrogenic lesion in adults and congenital anomalies in childhood^[56]; BVFP is associated with dyspnea in 67% of patients, stridor in 48%, voice impairment in 47% and dysphagia/aspiration in 19% of patients^[57].

Dysphagia is common in both UVFP and BVFP as glottis closure, ensured by vocal cord abduction, allows airway closure during bolus passage and effective cough. Glottal incompetence results in aspiration or penetration with onset of coughing or choking during liquid intake. Kraus *and al* (1996) in accord to Hirano and Bless (1993)^[58-59] reported aspiration between 40%-53% of patients.

Bhattacharyya *et al*^[60] describes 12.5% of aspiration occurring during the swallow related to inadequate glottal closure and 10.9% after the swallow as pharyngeal pooling spilled in the airways. Some studies reveal dysphagia not only related to glottal insufficiency but also resulting in reduced hyolaryngeal movement, epiglottic and supraglottic structures closure and pharyngeal pooling^[61]. Individuals with VFP show more difficulty with liquids than solids.

Swallowing impairment and prognosis depend on paralysis etiology: as VFP recover swallowing is usually restored. Behavioural treatment of dysphagia is generally indicated to compensate altered swallowing mechanism: head turn or head tilt direct the bolus down the unaffected side of pharynx. Mendelsohn maneuver, laryngeal adduction exercises, supraglottic swallow technique and exercises to improve strength may be also indicated. Modified bolus consistence, thickening liquids, slows transit increasing time to allow laryngeal closure. The surgical treatment by itself, in particular medialization procedure, does not seem to improve swallowing ability while it is useful to improve cough strength.

Cranial nerve deficits may not only be an isolated deficits but also multiple cranial nerve deficits exist. Unilateral palsy of nerves IX, X and IXX is called Collect- Sicard syndrome^[62] and is due to diseases affecting the jugular foramen as metastasis to lymphnode, fractures of the occipital bone and internal carotid artery dissection. The most common sign and symptoms are: altered vocal quality, dysphagia and dysarthria. Vocal fold paralysis is often reported and seems to persist even after the dysphagia resolves^[63]. Dysphagia is due to both deficit in laryngeal closure and to pharyngeal paralysis with residue in the omolateral piriform sinus (Figure 5). There is not information in literature regarding the treatment of dysphagia in Collect Sicard

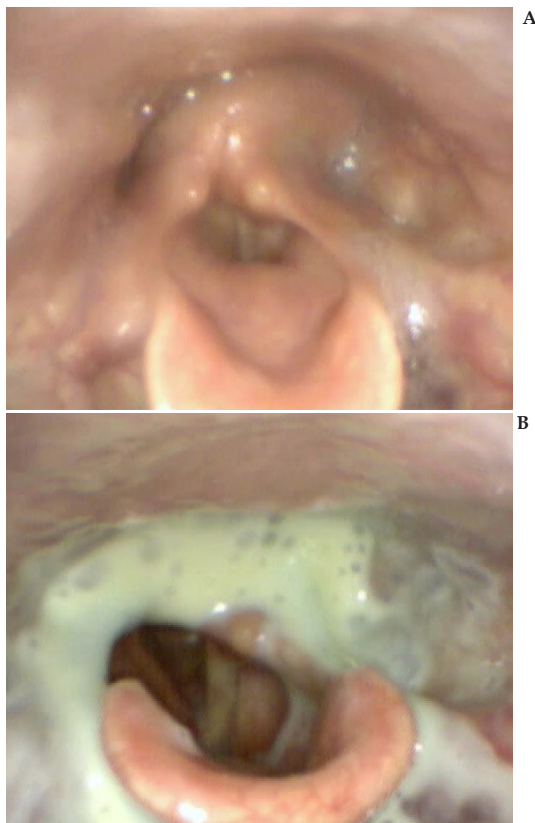


Figure 5 Endoscopic view of the hypopharynx in a patient with Collet-Sicard syndrome; a left pharyngeal paralysis (A), leading to residue in the left piriform sinus and in the post-cricoid region (B) during swallow of semisolid is clearly visible.

Syndrome because dysphagia often resolves treating the primary causes of cranial neuropathies. When dysphagia persists, tongue resistance exercises^[64] and compensatory technique may be useful.

Non-oncological Head and Neck obstructions

Bolus transit from the mouth to the esophagus may be impaired because of non-oncological obstructions; these include foreign bodies, hypo-pharyngeal polyps, cervical osteophytes and complications of anterior spine surgery.

Foreign body ingestion is particularly common in patients with intellectual disability and occurs mainly in the pediatric population, but it may occur in adults as well^[65]. Foreign body may be food related (f.i. bones) or non-food related (f.i. coins); entrapment occurs most frequently in the post-cricoid region the esophagus or the esophagus, obstructing bolus transit. Unless complications arise, dysphagia resolves as the foreign body is removed^[66].

Hypopharyngeal polyps are a very uncommon disease and only few cases of hypopharyngeal polyps have been reported in recent years^[67-68]. The vast majority of the hypopharyngeal and esophageal polyps reported in literature were of giant size (>5 cm), but smaller polyps may be also present (Figure 6). Progressive dysphagia and regurgitation of the mass into the mouth are the most common symptoms reported^[69].

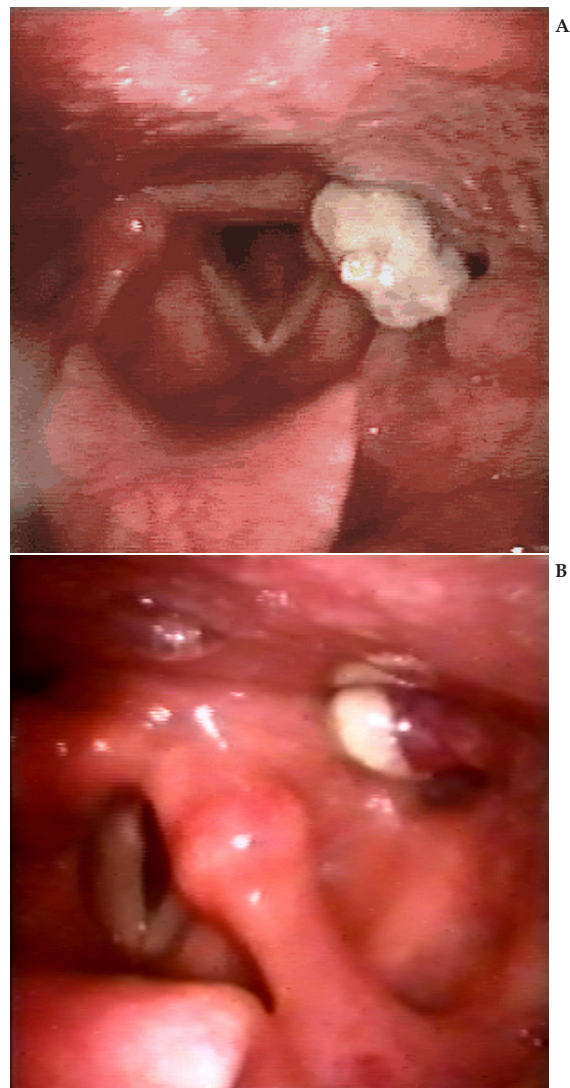


Figure 6 Endoscopic view of a left piriform sinus polyp.

Cervical osteophytes is a common clinical feature, occurring in up to 30% of the population^[70]; only in a small portion of individuals, however, cervical osteophytes impinge sufficiently in the pharynx to induce obstruction. Cervical osteophytes are typical of the aged population and may develop after trauma, even though often occur as a sign of general spinal degeneration, called Forestier diseases or diffuse idiopathic skeletal hyperostosis; in some cases they impact on the larynx causing dyspnea or dysphonia, because of impact on vocal fold movements. Dysphagia is usually due to mechanical obstruction and in some cases to impairment in epiglottic inversion (Figure 7); swallowing of solids is generally more compromised than semisolids or liquids^[71]. The challenge for the dysphagia clinician is to determine whether the osteophytes are the cause of dysphagia or other pathologic processes impair swallow or both condition coexists, as it happens in most of the cases. Although patients may benefit from behavioural treatment, only surgical removal allows resolution of the swallowing symptoms; however, surgical treatment should be limited to symptomatic cases and after exclusion of other mechanism of dysphagia^[72].

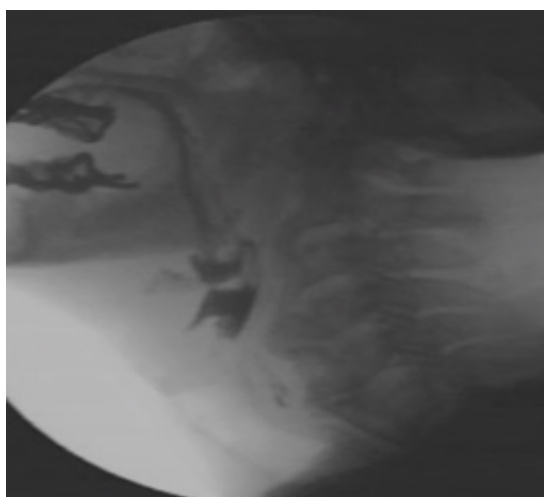


Figure 7 Videofluorographic swallow study with semisolid in a patient with cervical spine osteophytes at the level of the hypopharynx; the epiglottis can not invert during swallowing leading to penetration and residue in the valleculae.

Surgery of the anterior cervical spine is becoming more popular for the treatment of cervical nerve roots, cervical spinal cord or other cervical spine diseases such as infections, tumors or fractures; up to 40/100,000 individuals undergo this type of surgery^[73]. In the immediate post-surgical treatment dysphagia may arise as a complication in up to 50% of the population 1 month after surgery^[74-75]. Dysphagia is often due to retropharyngeal edema and decreased pharyngeal wall movement, impaired upper esophageal sphincter opening, incomplete epiglottic deflection and pharyngeal residue after swallow (Figure 8); symptoms are usually more evident with solids than with semisolids or liquids^[76]. Both behavioral and surgical treatment are possible, although there is not enough evidence to know the efficacy of either option.

ZENKER DIVERTICULUM

Zenker's Diverticulum (ZD) is an hypopharyngeal pouch herniating in the posterior part of the pharynx in the so called Killian's dehiscence. This is a triangular area of muscular weakness that plays an important role in the diverticulum development and is located between the oblique fibers of the inferior constrictor and

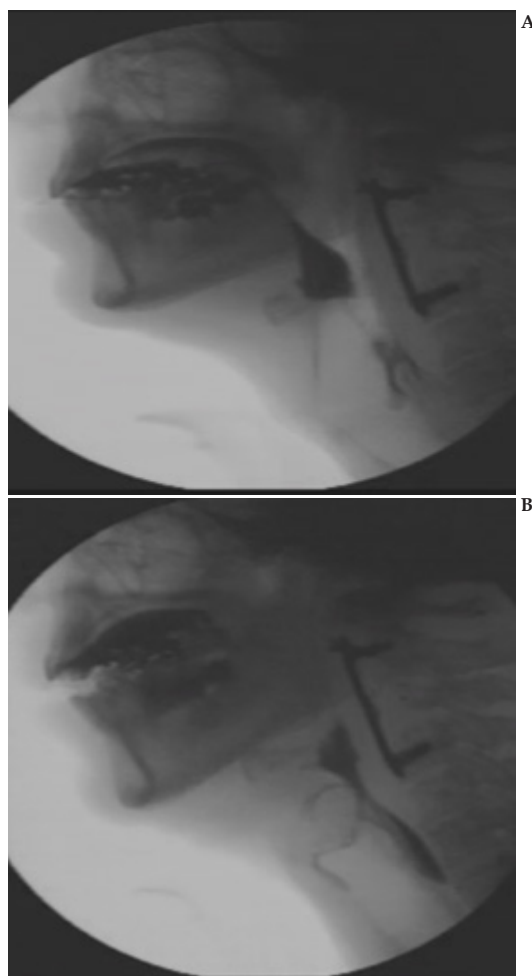


Figure 8 Videofluorographic swallow study with semisolid in a patient who underwent surgical removal of cervical metastasis. An anterior cervical plaque, with prevertebral swelling clearly visible (A); aspiration during the study is also visible (B).

the transverse fibers of the cricopharyngeal muscle below^[77]. Although the average incidence of this specific disease is 2/100,000, its effective occurrence is estimated to be more consistent, as individuals ZD could be asymptomatic or minimal symptomatic. ZD is more common in the elderly male people. The classical clinical presentation of ZD normally includes dysphagia combined with a varying degrees of regurgitation, a symptom which commonly affect 80% of these patients. In addition to these, aspiration, chronic cough, alitosis and weight loss (in severe cases) can also be considered as common symptoms^[78].

Achalasia or cricopharyngeal spasm, cricopharyngeal incoordination or congenital weakness are implicated in the pathogenesis of ZD^[79-81]. Even though a wide variety of abnormalities in UES function have been described, the most widely accepted theory is that inadequate UES relaxation causes a high intra-bolus pressure^[83-84]. ZD is frequently related to a focal or systemic myositis, as confirmed by histological analysis, hiatal hernia and gastroesophageal reflux disease^[85].

The gold standard for the diagnosis is a barium swallow. Videofluoroscopy is to be preferred to the static film, mainly because dynamic images are essential in the evaluation of the dysphagia severity through the analysis of aspiration timing and extension. An invariable association to ZD is cricopharyngeal bar, which consists in an indentation on the posterior hypopharyngeal wall visualized on videofluoroscopy (Figure 9). However, the finding of the bar should

not be taken as a certain proof that the bar itself causes the patient's dysphagia. Indeed, the patient symptoms are often caused by other problems, not infrequently distal to the bar in the esophagus.

The treatment for ZD is indicated for all symptomatic patients with or without associated complications and is invariably surgical in nature. Exceptions to this can be considered morbidly ill patients, patients with small diverticulum, and patients with minimal symptoms. The treatment could be endoscopic, like the ESD (Endoscopic Staple-assisted Diverticulostomy) and laser diverticulotomy or it could be classically open like diverticulopexy or diverticulectomy with cricopharyngeal myotomy^[86-90]. Endoscopic treatment should be preferred to the open ones in case of high-risk elderly patients. This kind of therapy for ZD is based on the division of the septum between the diverticulum and esophagus, within which the cricopharyngeus muscle is contained (cricopharyngeal myotomy).

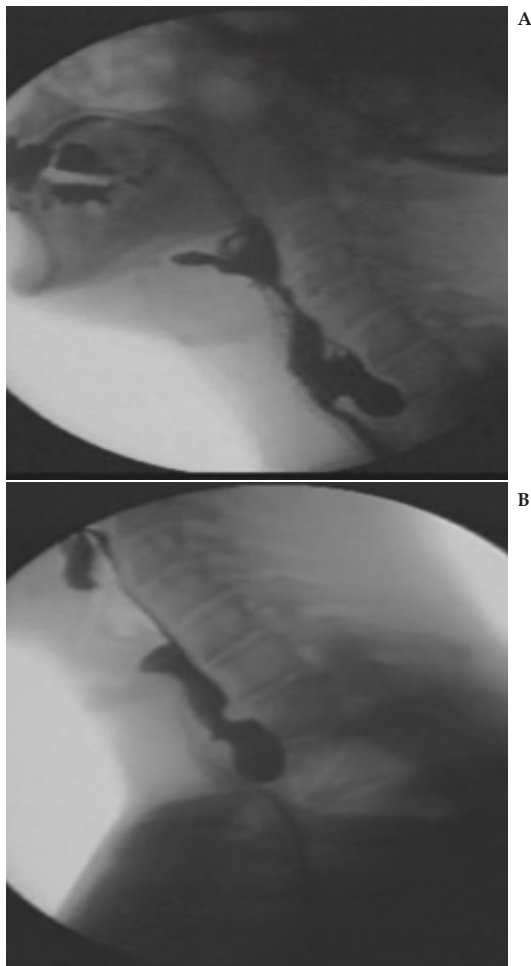


Figure 9 Videofluorographic swallow study with semisolid in a patient with Zenker's diverticulum; the contrast material fills the diverticulum (A) and a small posterior bar is also visible during regurgitation from the diverticulum back into the hypopharynx (B).

CONCLUSIONS

Dysphagia due to diseases and disorders of the head and neck area represent a smaller portion of oro-pharyngeal dysphagia compared to neurological diseases; although each disorder per se is relatively rare, the combination of all clinical situation represents an important group of clinical conditions that can not be overlooked.

Head and Neck disorders may impair swallowing through different mechanisms; symptoms, dysphagia severity, treatment options and prognosis for this variety of clinical situations vary enormously. Clinicians involved in the management of oro-pharyngeal dysphagia should be aware of the different diseases of this area and build teams or connections with different medical specialists in order to guarantee the best treatment option for each patient.

CONFLICT OF INTERESTS

There are no conflicts of interest with regard to the present study.

REFERENCES

- 1 Shaw SM, Martino R. The normal swallow: muscular and neurophysiological control. *Otolaryngol Clin North Am* 2013; **46**: 937-956
- 2 Rofes L, Clavè P, Ouyang A, Scharitzer M, Pokieser P, Vilardell N, Ortega O. Neurogenic and oropharyngeal dysphagia. *Ann N Y Acad Sci* 2013; **1300**: 1-10
- 3 Campisi G, Compilato D, Di Liberto C, Di Fede O, Pizzo G, Falaschini S, Lo Muzio L, Craxi A. Oral dysphagia. An unique symptom for a wide spectrum of diseases. *Panminerva Med* 2009; **51**: 12: 125-131
- 4 McHorney CA, Martin-Harris B, Robbins J, Rosenbeck J. *Dysphagia* 2006; **21**: 141-148
- 5 Curado MP, Hashibe M. Recent changes in the epidemiology of head and neck cancer. *Curr Opin Oncol* 2009; **21**: 194-200
- 6 Cooper JS, Porte K, Mallin K, Hoffman HT, Weber RS, Ang KK, Gay EG, Langer CJ. National Cancer Database report on cancer of the head and neck: 10-year update. *Head Neck* 2009; **31**: 748-758
- 7 Genden EM, Ferlito A, Silver CE, Jacobson AS, Werner J, Suárez C, Leemans CR, Bradley PJ, Rinaldo A. Evolution and management of laryngeal cancer. *Oral Oncol* 2007; **43**: 431-439
- 8 Genden EM, Ferlito A, Silver CE, Takes RP, Suárez C, Owen RP, Haigentz M Jr, Stoeckli SJ, Shaha AR, Rapidis AD, Rodrigo JP, Rinaldo A. Contemporary management of cancer of the oral cavity. *Eur Arch otorhinolaryngol* 2010; **267**: 1001-1017
- 9 Haigentz M Jr, Silver CE, Corry J, Genden EM, Takes RP, Rinaldo A, Ferlito A. Current trends in initial management of oropharyngeal cancer: the declining use of open surgery. *Eur Arch Otorhinolaryngol* 2009; **266**: 1845-1855
- 10 Gallo O, Deganello A, Gitti G, Santoro L, Senesi M, Scala J, Boddi V, de Campora E. Prognostic role of pneumonia in supracricoid and supraglottic laryngectomies. *Oral Oncol* 2009; **45**: 30-38
- 11 Manikantan K, Khode S, Sayed SI, Roe J Nutting CM, Rhys-Evans P, Harrington KJ, Kazi R. Dysphagia in head and neck cancer. *Cancer Treat Rev* 2009; **35**: 724-732
- 12 Schindler A, Favero E, Nudo S, Albera R, Schindler O, Cavalot AL. Long-term voice and swallowing modifications after supracricoid laryngectomy: objective, subjective, and self-assessment data. *Am J Otolaryngol* 2006; **27**: 378-383
- 13 Starmer HH, Gourin CG, Lua LL, Burkhead L. Pretreatment swallowing assessment in head and neck cancer patients. *Laryngoscope* 2011; **121**: 1208-1211
- 14 Pauloski BR, Rademaker AW, Logemann JA, Stein D, Beery Q, Newman L, Hanchett C, Tusan S, MacCracken E. Pretreatment swallowing function in patients with head and neck cancer. *Head Neck* 2000; **22**: 474-482
- 15 Stenson KM, MacCracken E, List M, Haraf DJ, Brockstein B, Weichselbaum R, Vokes EE. Swallowing function in patients with head and neck cancer prior to treatment. *Arch Otolaryngol Head Neck Surg* 2000; **126**: 371-377
- 16 Van der Molen L, Van Rossum MA, Ackerstaff AH, Smeele LE, Rasch CNR, Hilgers FJM. Pretreatment organ function in patients with advanced head and neck cancer; clinical outcome measures

- and patients views. *BMC Ear Nose Throat Disord* 2009; **9**: 10
- 17 Hirano M, Kuroiwa Y, Tanaka S, Matsuoka H, Sato K, Yoshida T. Dysphagia following various degrees of surgical resection for oral cancer. *Ann Otol Rhinol Laryngol* 1992; **101**: 138-141
 - 18 McConnel FM, Logemann JA, Rademaker AW, Pauloski BR, Baker SR, Lewin J, Shedd D, Heiser MA, Cardinale S, Collins S, Graner D, Cook BS, Milianti F, Baker T. Surgical variables affecting postoperative swallowing efficiency in oral cancer patients: a pilot study. *Laryngoscope* 1994; **104**: 87-90
 - 19 Schindler A, Mozzanica F, Barbiera F. Dysphagia evaluation and treatment after head and neck surgery and/or chemo-radiotherapy for head and neck malignancies. In: Ekberg O (ed.). *Dysphagia: diagnosis and treatment*. Berlin, Germany: Springer-Verlag Berlin Heidelberg; 2012
 - 20 Zuydam AC, Rogers SN, Brown JS, Vaughan ED, Magennis P. Swallowing rehabilitation after oro-pharyngeal resection for squamous cell carcinoma. *Br J Oral Maxillofac Surg* 2000; **38**: 513-518.
 - 21 Hamlet S, Jones L, Patterson R, Michou G, Cislo C. Swallowing recovery following anterior tongue and floor of mouth surgery. *Head Neck* 1991; **13**: 334-339
 - 22 Woisard V, Puech M, Yardeni E, Serrano E, Pessey JJ. Deglutition after supracricoid laryngectomy: compensatory mechanism and sequelae. *Dysphagia* 1996; **11**: 265-269
 - 23 Yuceturk AV, Tarhan S, Gunhan K, Pbusu Y. Videofluoroscopic evaluation of the swallowing function after supracricoid laryngectomy. *Eur Arch Otorhinolaryngol* 2005; **262**: 198-203
 - 24 Schindler A, Favero E, Capaccio P, Albera R, Cavalot AL, Ottaviani F. Supracricoid laryngectomy: age influence on long-term functional results. *Laryngoscope* 2009; **119**: 1218-1225
 - 25 Hirai H, Omura K, Harada H, Tohara H. Sequential evaluation of swallowing function in patients with unilateral neck dissection. *Head Neck* 2010; **32**: 896-904
 - 26 Lango MN, Egleston B, Ende K, Feignferd S, D'Ambrosio DJ, Cohen RB, Ahmad S, Nicolaou N, Ridge JA. Impact of neck dissection on long-term feeding tube dependence in patients with head and neck cancer treated with primary radiation or chemoradiation. *Head Neck* 2010; **32**: 341-347
 - 27 Merlano M, Benasso M, Corvò R, Rosso R, Vitale V, Blengio F, Numico G, Margarino G, Bonelli L, Santi L. Five-year update of a randomized trial of alternating radiotherapy and chemotherapy compared with radiotherapy alone in treatment of unresectable squamous cell carcinoma of the head and neck. *J Natl Cancer Inst* 1996; **88**: 583-589
 - 28 Merlano M, Vitale V, Rosso R, Benasso M, Corvò R, Cavallari M, Sanguineti G, Bacigalupo A, Badellino F, Margarino G, Brema F, Pastorino G, Marziano G, Grimaldi A, Scasso F, Sperati G, Pallestrini E, Garaventa G, Accomando E, Cordone G, Comella G, Daponta A, Rubagotti A, Bruzzi P, Santi L. Treatment of advanced squamous-cell carcinoma of the head and neck with alternating chemotherapy and radiotherapy. *N Engl J Med* 1992; **327**: 1115-1121
 - 29 Wendt TG, Grabenbauer GG, Rödel CM, Thiel HJ, Aydin H, Rohloff R, Wustrow TP, Iro H, Popella C, Schalhorn A. Simultaneous radiochemotherapy versus radiotherapy alone in advanced head and neck cancer: A randomized multicenter study. *J Clin Oncol* 1998; **16**: 1318-1324
 - 30 Pignon JP, Bourhis J, Domenge C, Designé L. Chemotherapy added to locoregional treatment for head and neck squamous-cell carcinoma: three meta-analyses of updated individual data. MACH-NC Collaborative Group. Meta-analysis of chemotherapy on head and neck cancer. *Lancet* 2000; **355**: 949-955
 - 31 Pignon JP, Le Maitre A, Maillard E, Bourhis J. MACH-NC Collaborative Group. Meta-analysis of chemotherapy in head and neck cancer (MACH-NC): an update of 93 trials and 17, 346 patients. *Radiother Oncol* 2009; **92**: 4-14
 - 32 Adelstein DJ, Li Y, Adams GL, Wagner H Jr, Kish JA, Ensley JF, Schuller DE, Forastiere AA. An intergroup phase III comparison of standard radiation therapy and two schedules of concurrent chemoradiotherapy in patients with unresectable squamous cell head and neck cancer. *J Clin Oncol* 2003; **21**: 92-98.
 - 33 Sessions DG, Lenox J, Spector GJ, Chao C, Chaudry OA. Analysis of treatment results for base of tongue cancer. *Laryngoscope* 2003; **113**: 1252-1261
 - 34 Forastiere AA, Goepfert H, Maor M, Pajak TF, Weber R, Morrison W, Glisson B, Trotti A, Ridge JA, Chao C, Peters G, Lee DJ, Leaf A, Ensley J, Cooper J. Concurrent chemotherapy and radiotherapy for organ preservation in advanced laryngeal cancer. *N Engl J Med* 2003; **349**: 2091-2098
 - 35 Smith RV, Kotz T, Beitler JJ, Wadleret S. Long-term swallowing problems after organ preservation therapy with concomitant radiation therapy and intravenous hydroxyurea. *Arch Otolaryngol Head Neck Surg* 2000; **126**: 384-389
 - 36 Eisbruch A, Lyden T, Bradford CR, Dawson LA, Haxer MJ, Miller AE, Tekson TN, Chepeha DB, Hogikyan ND, Terrell JE, Wolf GT. Objective assessment of swallowing dysfunction and aspiration after radiation concurrent with chemotherapy for head-and-neck cancer. *Int J Radiat Oncol Biol Phys* 2002; **53**: 23-28
 - 37 Frowen J, Perry A. Swallowing outcomes after radiotherapy for head and neck cancer: a systematic review. *Head Neck* 2006; **28**: 932-944
 - 38 Frowen J, Cotton S, Corry J, Perry A. Impact of demographics, tumor characteristics, and treatment factors on swallowing after (chemo) radiotherapy for head and neck cancer. *Head Neck* 2010; **32**: 513-528
 - 39 Agarwal J, Palwe V, Dutta D, Gupta T, Laskar SG, Budrukkar A, Murthy V, Chaturvedi P, Pai P, Chaukar D, D'Cruz AK, Kulkarni S, Kulkarni A, Baccher G, Shrivastava SK. Objective assessment of swallowing function after definitive concurrent (chemo)radiotherapy in patients with head and neck cancer. *Dysphagia* 2011; **26**: 399-406
 - 40 Dornfeld K, Simmons JR, Karnell L, Karnell M, Funk G, Yao M, Wacha J, Zimmerman B, Buatti JM. Radiation doses to structures within and adjacent to the larynx are correlated with long-term diet- and speech- related quality of life. *Int J Radiat Oncol Biol Phys* 2007; **68**: 750-757
 - 41 Caudell JJ, Schaner PE, Meredith RF, Locher JL, Nabell LM, Carroll WR, Magnuson JS, Spencer SA, Bonner JA. Factors associated with long-term dysphagia after definitive radiotherapy for squamous cell carcinoma of the head and neck. *Int J Radiat Oncol Biol Phys* 2009; **73**: 410-415
 - 42 Logemann JA, Pauloski BR, Rademaker AW, Lazarus CL, Mittal B, Gaziano J, Stachowiak L, MacCracken E, Newman LA. Xerostomia: 12-month changes in saliva production and its relationship to perception and performance of swallow function, oral intake, and diet after chemoradiation. *Head Neck* 2003; **25**: 432-437
 - 43 Lazarus CL. Effects of chemoradiotherapy on voice and swallowing. *Curr Opin Otolaryngol Head Neck Surg* 2009; **17**: 172-178
 - 44 Mittal BB, Pauloski BR, Haraf DJ, Pelzer HJ, Argiris A, VOKES EE, Rademker A, Logemann JA. Swallowing dysfunction—preventative and rehabilitation strategies in patients with head and neck cancers treated with surgery, radiotherapy, and chemotherapy: a critical review. *Int J Radiat Oncol Biol Phys* 2003; **57**: 1219-1230
 - 45 Treister N, Sonis S. Mucositis: biology and management. *Curr Opin Otolaryngol Head Neck Surg* 2007; **15**: 123-129
 - 46 Pauloski BR, Rademaker AW, Logemann JA, Lundy D, Bernstein M, McBreen C, Santa D, Campanelli A, Kelchner L, Klaben B, Discekici-Harris M. Relation of mucous membrane alterations to oral intake during the first year after treatment for head and neck cancer. *Head Neck* 2011; **33**: 774-779
 - 47 Georgalas CC, Tolley NS, Narula A. Tonsillitis. *Clin Evid (online)* 2009 Oct 26; 2009. doi: pii: 0503
 - 48 Cantarella G, Pagani D, Biondetti P. An unusual cause of mechanical dysphagia: an agglomerate of calculi in a tonsillar residue.

- Dysphagia* 2006; **21**: 133-136
- 49 Charles R, Fadden M, Brook J. Acute epiglottitis. *BMJ* 2013 Sep 19; **347**: f5235
- 50 Kassam K, Messiha A, Heliotis M. Ludwig's angina: the original angina. *Case Rep Surg* 2013; **2013**: 974269
- 51 Herbert-Cohen D, Yeh JS, Hernandez J, Lewiss RE, Saul T. Man with facial pain. Ludwig's angina. *Ann Emerg Med* 2013; **61**:278-288
- 52 Karus D, Raveis VH, Alexander C, Hanna B, Selwyn P, Marconi K, Higginson I. Patient reports of symptoms and their treatment at three palliative care projects servicing individuals with HIV/AIDS. *J Pain Symptom Manage* 2005; **30**: 408-417
- 53 Cook TM, Protheroe RT, Handel JM. Tetanus. A review of the literature. *Br J Anaesth* 2001; **87**: 477-487
- 54 Rubin AD, Sataloff RT. Vocal fold paresis and paralysis. *Otolaryngol Clin North Am* 2007; **40**: 1109-31
- 55 Netterville JL, Stone R, Luken ES, Civantos FJ, Ossoff RH. Silastic medicalization and arytenoid adduction: the Vanderbilt experience. A review of 116 phonosurgical procedures. *Ann Otol Rhinol Laryngol* 1993; **102**: 413-424
- 56 Yin SS, Qiu WW, Stucker FJ, Hoasjoe DK, Aarstad RF. Evaluation of bilateral vocal fold dysfunction: paralysis versus fixation, superior versus recurrent, and distal versus proximal to the laryngeal nerves. *Am J Otolaryngol* 1997; **18**: 9-18
- 57 Freehery JA, Pribitkin EA, Heffelfinger RN, Lacombe VG, Lee D, Lowry LD. The evolving etiology of bilateral vocal fold immobility. *J Voice* 2003; **17**: 76-81
- 58 Kraus DH, Ali MK, Ginsberg RH, Hughes CJ, Orlikoff RF, Rusch VW. Vocal cord medicalization for unilateral paralysis associated with intrathoracic malignancies. *J Thorac Cardiovasc Surg* 1996; **111**: 334-339
- 59 Hirano M, Bless DM. Videostroboscopic examination of the larynx. 1993. San Diego (CA): Singular
- 60 Bhattacharyya N, Kotz T, Shapiro J. Dysphagia and aspiration with unilateral vocal fold immobility: incidence, characterization and response to surgical treatment. *Ann Otol Rhinol Laryngol* 2002; **111**: 672-679
- 61 Logemann JA, Kharilas PJ, Cheng J, Pauloski BR, Gibbons PJ, Rademaker AW. Closure mechanism of the laryngeal vestibule during swallow. *Am J Physiol* 1992; **262**: G338-G344
- 62 Hsu HP, Chen ST, Chen CJ, Ro LS. A case of Collet-Sicard syndrome associated with traumatic atlas fractures and congenital basilar invagination. *J Neurol Neurosurg Psychiatr* 2004; **75**: 782-784
- 63 Legros B, Fournier P, Chiaroni P, Rotz O, Fusciardi J. Basal fracture of the skull and lower (I, X, XI, XII) cranial nerves palsy: four case reports including two fractures of the occipital condyle. A literature review. *J Trauma Inj Inf Crit Care* 2000; **48**: 342-348
- 64 Chichero J. Swallowing rehabilitation. In: J Chichero, B Murdoch (eds). *Dysphagia: foundation, theory and practice*. 2006: Chichester, England: John Wiley and Sons
- 65 Swift S, Hornick P, Fountain SW. Calculophagia? *Ann Royal Coll Surg Eng* 2004; **86**: 220
- 66 Eisen GM, Baron TH, Dominitz JA, Faigel DO, Goldstein JL, Johanson JF. Guidelines for management of ingested foreign bodies. *Gastrointest End* 2002; **55**: 802-806
- 67 Caceres M, Steeb G, Wilks S, Garrett HE. Large peduncolated polyps originating in the esophagus and hypopharynx. *Ann Thorac Surg* 2006; **81**: 393-396
- 68 Nishimura G, Horiuchi C, Yoshida T, Kawakami M, Yabuki K, Matsuda H, Mikami Y, Tsukuda M. Fibromatous polyp of the hypopharynx. *Auris Nasus Larynx* 2006; **33**: 333-336
- 69 Zevallos JP, Shah RP, Baredes S. Giant fibrovascular polyp of the hypopharynx. *Laryngoscope* 2005; **11**: 876-878
- 70 Granville LJ, Musson N, Altman R, Silverman M. Anterior cervical osteophytes as a cause of pharyngeal stage dysphagia. *J Am Geriatr Soc* 1998; **46**: 1003-1007
- 71 Strasser G, Schima W, Schber E, Pokieser P, Kaider A, Denk DM. Cervical osteophytes impinging on the pharynx: importance of size and concurrent disorders for development of aspiration. *Am J Roentg* 2000; **174**: 449-453
- 72 Presutti L, Alicandri-Ciuffelli M, Piccinin A, Trebbi M, Marchioni D, Ghidini A, Ruberto M. Forestier disease: single-center surgical experience and brief literature review. *Ann Otol Rhinol Laryngol* 2010; **119**: 602-608
- 73 Angevine PD, Arons RR, McCormick PC. National and regional rates and variation of cervical discectomy with and without anterior fusion, 1990-1999. *Spine* 2003; **28**: 931-939
- 74 Chin KR, Eiszner JR, Adams SB. Role of plate thickness as a cause of dysphagia after anterior cervical fusion. *Spine* 2007; **32**: 2585-2590
- 75 Fountas KN, Kapsalaki EZ, Nikolakakos LG, Smission HF, Johnston KW, Gregorian AA, Lee, GP, Robinson JS. Anterior cervical discectomy and fusion associated complications. *Spine* 2007; **32**: 2310-2317
- 76 Lee MJ, Bazaz R, Furey CG, Yoo J. Risk factors for dysphagia after anterior cervical spine surgery: a two-year prospective cohort study. *Spine J* 2007; **7**: 141-147
- 77 Killian G. Uber den mund der speiserohre. *Zschr Ohrenheilk* 1908. *Zschr Ohrenheilk* 1908; **55**: 1
- 78 Schindler A, Mozzanica F, Alfonsi E, Ginocchio D, Rieder E, Lenglinger J, Schoppmann SF, Scharitzer M, Pokieser P, Kuribayashi S, Kawamura O, Kusano M, Zelenik K. Upper esophageal sphincter dysfunction: diverticula-globus pharynges. *Ann N Y Acad Sci* 2013; **1300**: 250-260
- 79 Sutherland HD. Cricopharyngeal achalasia. *J Thorac Cardiovasc Surg* 1962; **43**: 114-26
- 80 Belsey R. Functional disease of the esophagus. *J Thorac Cardiovasc Surg* 1966 Aug; **52**: 164-88
- 81 Dantas RO, Cook IJ, Dodds WJ, Kern MK, Lang IM, Bras-seur JG. Biomechanics of cricopharyngeal bars. *Gastroenterology* 1990; **99**:1269-1274.
- 82 Leonard R, Kendall K, McKenzie S. UES opening and cricopharyngeal bar in nondysphagic elderly and nonelderly adults. *Dysphagia* 2004; **19**: 182-191
- 83 Cook IJ, Gabb M, Panagopoulos V, Jamieson GG, Dodds WJ, Dent J, Shearman DJ. Pharyngeal (Zenker's) diverticulum is a disorder of upper esophageal sphincter opening. *Gastroenterology* 1992; **103**: 1229-35
- 84 Cook I J, Blumbergs P, Cash K, Jamieson G G, Shearman D J. Structural abnormalities of the cricopharyngeus muscle in patients with pharyngeal (Zenker's) diverticulum. *J Gastroenterol Hepatol* 1992; **7**: 556-62
- 85 Sasaki CT, Ross DA, Hundal J. Association between Zenker diverticulum and gastroesophageal reflux disease: development of a working hypothesis. *Am J Med* 2003; **18**: 169S-171S
- 86 Chang CY: Endoscopic staple diverticulostomy for Zenker's diverticulum: review of literature in 159 consecutive cases. *Laryngoscope* 2003; **113**: 957-65
- 87 Feeley MA et al, Zeenker's diverticulum: analysis of surgical complications from diverticulotomy and cricopharyngeal myotomy. *Laryngoscope* 1999; **109**: 858-61
- 88 Wang AY, Kadekade R, Kahrilas PJ, Hirano I. Effectiveness of esophageal dilation for symptomatic cricopharyngeal bar. *Gastrointest Endosc* 2005; **61**:148-152
- 89 Bonavina L, Bona D, Abraham M, Saino G, Abate E. Long-term results of endoscopic and open surgical approach for Zenker diverticulum. *World J Gastroenterol* 2007; **13**: 2586-2589
- 90 Peretti G, Piazza C, Del Bon F, Cocco D, De Benedetto L, Mangili S. Endoscopic treatment of Zenker's diverticulum by carbon dioxide laser. *Acta Otorhinolaryngol Ital* 2010; **30**: 1-4

Peer reviewer: Angelique A. Timmerman, Department of Family Medicine, Maastricht University, PO Box 616, 6200 MD, Maastricht, The Netherlands.