

Taeniasis Related Frequent Intestinal Obstruction: Case Report and Mini-Review

Pan Li, Lijuan Xu, Jie Xiang, Zhi He, Zhaoyuan Peng, Bota Cui, Guozhong Ji, Faming Zhang

Pan Li, Lijuan Xu, Jie Xiang, Zhi He, Zhaoyuan Peng, Bota Cui, Guozhong Ji, Faming Zhang, Medical Center for Intestinal Diseases, the Second Affiliated Hospital of Nanjing Medical University, 121 Jang Jiayuan, Nanjing 210011, China

Correspondence to: Faming Zhang, MD, PhD, Medical Center for Intestinal Diseases, the Second Affiliated Hospital of Nanjing Medical University, 121 Jang Jiayuan, Nanjing 210011, China.

Email: fzhang@njmu.edu.cn

Telephone: +86-25-58509883

Fax: +86-25-58509931

Received: October 15, 2014

Revised: December 27, 2014

Accepted: December 31, 2014

Published online: January 21, 2015

ABSTRACT

A 62-year-old Chinese male presented to our hospital for abdominal pain and bloating for more than one month. He had a history of operation for appendicitis and followed by frequent intestinal obstruction during the last 35 days. He was finally diagnosed as taeniasis and taeniasis related-eosinophilic gastroenteritis. Glycerini under colonoscope was used to improve the quality of endoscopic view for parasite and relieve the intestinal obstruction. This article introduced our diagnostic and therapeutic experience of parasite infection in patients with frequent intestinal obstruction and parasite infection related-eosinophilic gastroenteritis.

© 2015 ACT. All rights reserved.

Key words: Intestinal obstruction; Taeniasis; Glycerini; Eosinophilic gastroenteritis

Li P, Xu LJ, Xiang J, He Z, Peng ZY, Cui BT, Ji GZ, Zhang FM. Taeniasis Related Frequent Intestinal Obstruction: Case Report and Mini-Review. *Journal of Gastroenterology and Hepatology Research* 2015; 4(1): 1455-1458 Available from: URL: <http://www.ghrnet.org/index.php/joghr/article/view/944>

INTRODUCTION

Taenia solium (T. solium) is a pork tapeworm which induces human infections through pigs as intermediate hosts. Humans eat raw or undercooked pork infected with cysticerci and develop intestinal taeniasis in definitive host or may also acquire cysticercosis by accidental ingestion of parasite eggs released from taeniasis carriers^[1]. Neurocysticercosis (NCC), cysticercosis of the human nervous system, is a major cause of epilepsy and other neurological morbidity in most of the world^[2-4]. Significant symptoms are absent in most patients who carry an adult T. solium. Expulsion of proglottids is a specific symptom in taeniasis infected persons^[5,6]. Taeniasis and cysticercosis (T/C) is still endemic in remote and/or rural areas in China in recent decades, especially in minority territories because of meat inspection systems and sustainable education against T/C are lacking^[6-8]. However, *Taenia solium* is rare in developed area in China. We reported an unusual case presented with abdominal pain and bloating and frequent intestinal obstruction which was finally diagnosed as parasite infection. The special method for diagnosis of parasite infection and combined treatment for the frequent intestinal obstruction were reported in this article.

CASE REPORT

A 62-year-old Chinese man presented to our hospital in May 2013. He complained with abdominal pain and bloating for more than one month. He had an emergency appendectomy in the local hospital thirty-five days ago. On the third postoperative day, he developed abdominal pain and bloating, watery stools, and high fever at 38.3°C. Anti-inflammatory therapy didn't improve his symptoms, and the patient subsequently developed frequent intestinal obstruction and malnutrition. He was transferred to our hospital because the treatment was ineffective. On examination, the patient showed anemic appearance and abdominal tenderness. Routine laboratory tests revealed total white blood cell count 10,640/ μ L with absolute neutrophil count 9390/uL and normal count of eosinophils,

erythrocyte sedimentation rate (ESR) 9 mm/h, C-reactive protein (CRP) 23 mg/L, serum albumin 29 g/L, immunoglobulin (Ig) G 9.34g/L, IgA 2.02 g/L, IgM 1.16 g/L. Examination of the stool showed mucus and occult blood positive, but no parasites and ova. An abdominal computed tomography (CT) scan was performed and showed thickening of the ileocecal, colonic and rectal walls. Colonoscopy revealed stenosis of the descending colon and sigmoid colon, multiple erosion and superficial ulcers (Figure 1A). Biopsy specimens revealed a mixed chronic inflammatory infiltrate predominately with eosinophils and tumor cells were not observed (Figure 1B). He was discharged for follow-up after with his symptoms resolved.

In June 20 2013, the patient observed more than one parasites in 15-20 cm length in his feces at home. We failed to test the worm because he didn't bring it to hospital. Then, he received 2 days of albendazole which is a broad-spectrum anthelmintic that is effective against nematode, trematode, and cestode infections. However, the patient was re-admitted to our center within one week with abdominal distension and right lower quadrant cramp. Colonoscopy scraped through the stenotic sigmoid colon and showed cluster of gelatinous

stool in the descending colon. 100 mL of enema Glycerini was injected into the descending colon through colon channel and the dead parasites in stool were clear observed in the colon (Figure 2A). After the procedure, his intestinal obstruction was relieved immediately. Parasitological examination showed that the parasite was probably *T. solium*. The biopsy in stenotic sigmoid colon was performed again and enough eosinophilic infiltrates in the mucosa was observed. With the consideration of parasite induced eosinophilic gastroenteritis related multiple thickening of intestine, this patient was treated with oral prednisone (40 mg/day) for 3 weeks, prior to weekly tapering by 5 mg until withdrawal. Three months later, colonoscopy showed the normal enteric cavity, normal mucosa and distinct vessels in whole colon. All routine laboratory parameters were within normal ranges. He was well during the follow-up 16 months.

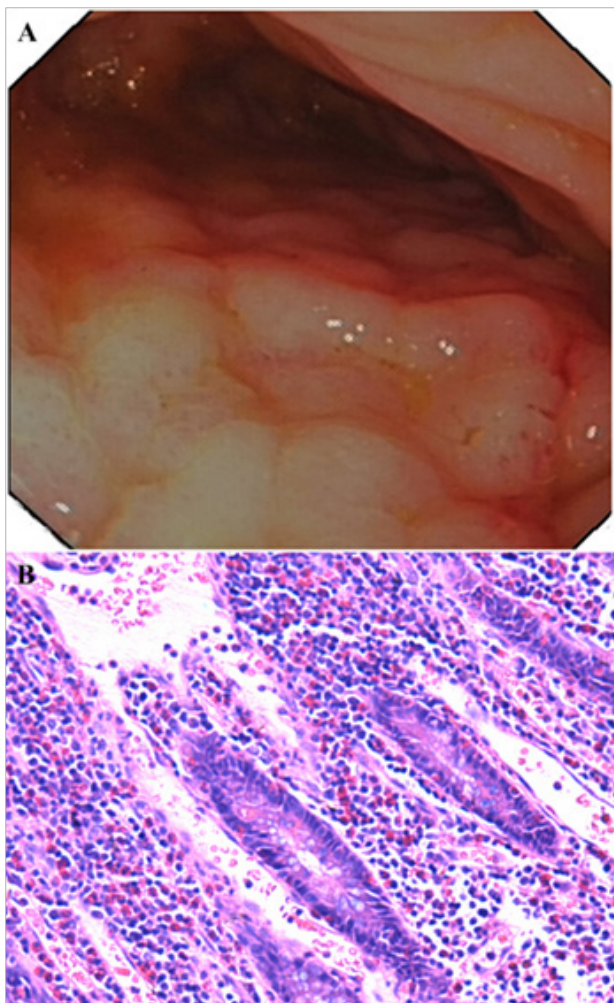


Figure 1 Endoscopic and pathological finding. A: Colonoscopy revealed stricture and mucosa lesion in the sigmoid colon and the descending colon; B: Biopsy from colon lesion revealed chronic inflammatory infiltrate predominately with eosinophils (HE, $\times 100$).

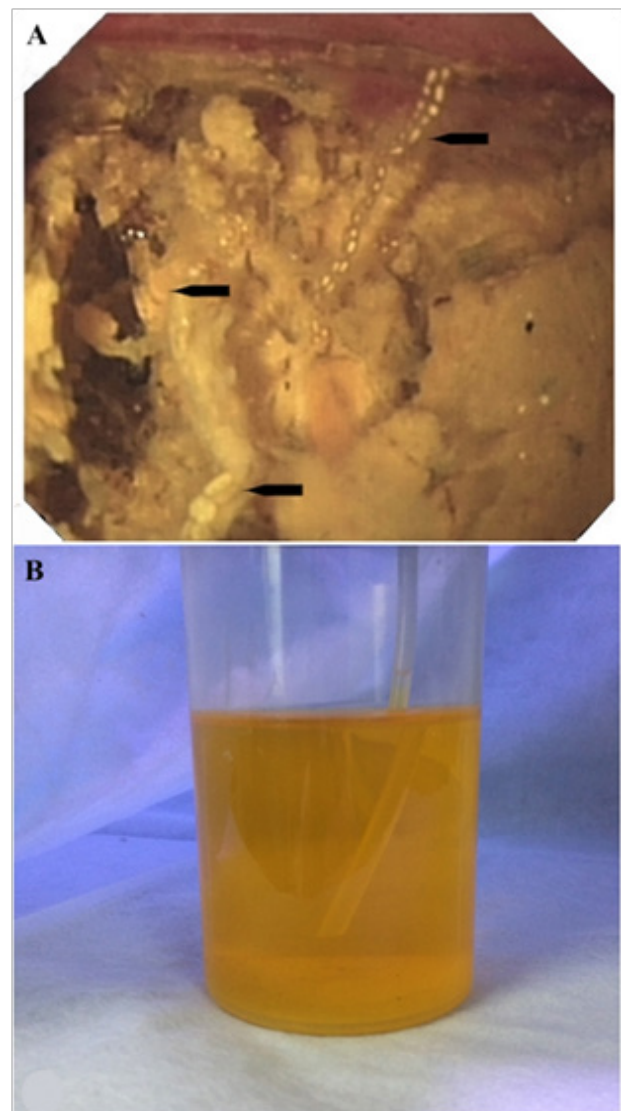


Figure 2 The effect of infusing enema Glycerini under colonoscope. A: Endoscopic view showed dead parasites (black arrow) in feces in the descending colon; B: In visual observation, the plastic pipe in the solution is larger than the part in air. The lab-prepared yellowish-brown solution was used for modeling the fluid contents in colon.

DISCUSSION

T/C caused by *T. solium* is one of the WHO Neglected Tropical Diseases and continues to be a major public health burden in most developing countries^[6]. Taeniasis refers to the intestinal infection with adult tapeworm, which is acquired by eating raw or undercooked pork containing cysticerci. The main clinical features of taeniasis are vague. Patients experience symptoms like abdominal pain, epigastric pain, nausea, vomiting, diarrhea, and weight loss, but these nonspecific symptoms rarely occur^[9]. Adult tapeworms consist of a scolex and numerous body segments called proglottids. Patients become aware of tapeworm infection by noting passage of proglottids in their feces, but this is not necessarily in the case for *T. solium*^[5]. Mature tapeworms may lead to several rare complications such as Meckel's diverticulitis^[10], appendicitis^[11,12], intestinal obstruction^[13,14] and colonic perforation^[15]. Human cysticercosis is acquired by accidental ingestion of eggs of *T. solium* liberated from gravid proglottids.

Diagnosis T/C can be performed by microscopic observation of taenia eggs and proglottids or scolices in feces, immunoblot assay to detect IgG anticysticercal antibodies in serum and cerebrospinal fluid, genotyping of mitochondrial DNA (mtDNA) to assess where the infection acquired^[5,16,17].

Albendazole is a broad-spectrum anthelmintic that is effective against nematode, trematode, and cestode infections^[18]. In the present case, the patient with abdominal pain and bloating for one month had a history of appendicitis treatment and frequent intestinal obstruction, and was initially considered possible Cohn's disease. After the patient observed an approximately 15-20 cm length parasite in his feces at home, he was diagnosed as parasite infection. He suffered intestinal obstruction again after albendazole was taken by oral. During colonoscopy, infused Enema Glycerini through colonoscopy can achieved the diagnostic view same as oil immersion microscope (Figure 2B) and also resolve bowel obstruction caused by parasites.

This case benefited from effective anthelmintic, however, the multiple thickening of intestine actually was the important reason of frequent intestinal obstruction. With the consideration of parasite induced eosinophilic gastroenteritis based on the pathological findings, the patient further benefited from the treatment with oral prednisone based on the 16-month follow-up.

Eosinophilic gastroenteritis is an uncommon disease and can be seen anywhere in the gastrointestinal tract. The involvement of different layers usually gives rise to different clinical manifestations. The most common mucosal disease generally presents with diarrhea, bleeding, and protein-losing enteropathy, or malabsorption. Involvement of the muscle layer may cause bowel wall thickening and subsequent intestinal obstruction, which was the manifestation in this patient. The subserosal form usually presents with peritonitis and eosinophilic ascites, with or without any or all of the symptoms associated with mucosal and/or muscle layer disease^[19].

Because the pathogenesis and etiology of the disease are not clear, there is no standards for the diagnosis of eosinophilic gastroenteritis^[19]. Talley *et al*^[20] have identified three main diagnostic criteria: (1) the presence of gastrointestinal symptoms; (2) biopsies demonstrating eosinophilic infiltration of one or more areas of the gastrointestinal tract, or characteristic radiological findings with peripheral eosinophilia; and (3) no evidence of parasitic or extra-intestinal disease. However, the definitive diagnosis is the histologic demonstration of eosinophilic infiltration of some part of the gastrointestinal tract^[21]. There is no consensus about the treatment of eosinophilic gastroenteritis, but long term steroid treatment is the

mainstay management so far.

In conclusion, parasite infection and parasite infection related-eosinophilic gastroenteritis should be aware for cryptogenic frequent intestinal obstruction. Infusing Enema Glycerini through endoscope should be a useful method which might bring benefits to improve the endoscopic view of parasite and relieve fecal ileus.

CONFLICT OF INTERESTS

There are no conflicts of interest with regard to the present study.

REFERENCES

- Rhee S-M, Park KJ, Ha Y-C. Hypertrophic Osteoarthropathy in Patient with Crohn's Disease: A Case Report. *Journal of Bone Metabolism* 2014; **21**: 151
- Roman G, Sotelo J, Del Brutto O, Flisser A, Dumas M, Wadia N, Botero D, Cruz M, Garcia H, de Bittencourt PR, Trelles L, Arriagada C, Lorenzana P, Nash TE, Spina-Franca A. A proposal to declare neurocysticercosis an international reportable disease. *Bull World Health Organ* 2000; **78**: 399-406
- Burneo JG, Cavazos JE. Neurocysticercosis and epilepsy. *Epilepsy Curr* 2014; **14**: 23-28
- Ito A, Nakao M, Wandra T. Human Taeniasis and cysticercosis in Asia. *Lancet* 2003; **362**: 1918-1920
- Raoul F, Li T, Sako Y, Chen X, Long C, Yanagida T, Wu Y, Nakao M, Okamoto M, Craig PS, Giraudoux P, Ito A. Advances in diagnosis and spatial analysis of cysticercosis and taeniasis. *Parasitology* 2013; **140**: 1578-1588
- Ito A, Li T, Chen X, Long C, Yanagida T, Nakao M, Sako Y, Okamoto M, Wu Y, Raoul F, Giraudoux P, Craig PS. Mini review on chemotherapy of taeniasis and cysticercosis due to *Taenia solium* in Asia, and a case report with 20 tapeworms in China. *Trop Biomed* 2013; **30**: 164-173
- Ito A, Urbani C, Jiamin Q, Vuitton DA, Dongchuan Q, Heath DD, Craig PS, Zheng F, Schantz PM. Control of echinococcosis and cysticercosis: a public health challenge to international cooperation in China. *Acta Trop* 2003; **86**: 3-17
- Li T, Craig PS, Ito A, Chen X, Qiu D, Qiu J, Sato MO, Wandra T, Bradshaw H, Li L, Yang Y, Wang Q. Taeniasis/cysticercosis in a Tibetan population in Sichuan Province, China. *Acta Trop* 2006; **100**: 223-231
- Hirasaki S, Murakami K, Mizushima T, Hiramatsu K, Hanayama Y, Kanamori T, Koide N. Long-term *Taenia saginata* Infection Successfully Treated with Meglumine/Diatrizoate Sodium. *Internal Medicine* 2012; **51**: 177-179
- Chirdan L, Yusufu L, Ameh E, Shehu S. MECKEL'S DIVERTICULITIS DUE TO TAENIA SAGINATA: CASE REPORT. *East African medical journal* 2001; **78**: 107-108
- Aydin O. Incidental parasitic infestations in surgically removed appendices: a retrospective analysis. *Diagn Pathol* 2007; **2**: 16
- Chakrabarti I, Gangopadhyay M, Bandopadhyay A, Das NK. A rare case of gangrenous appendicitis by eggs of *Taenia* species. *J Parasit Dis* 2014; **38**: 135-137
- Karanikas ID, Sakellariadis TE, Alexiou CP, Siaperas PA, Fotopoulos AC, Antsaklis GI. *Taenia saginata*: a rare cause of bowel obstruction. *Trans R Soc Trop Med Hyg* 2007; **101**: 527-528
- Atitar I, Amrani L, Serraj I, Amrani N. Small bowel parasitosis. *Clin Res Hepatol Gastroenterol* 2012; **36**: 399
- Demiriz M, Gunhan O, Celasun B, Aydin E, Finci R. Colonic perforation caused by taeniasis. *Trop Geogr Med* 1995; **47**: 180-182
- Yanagida T, Yuzawa I, Joshi DD, Sako Y, Nakao M, Nakaya K, Kawano N, Oka H, Fujii K, Ito A. Neurocysticercosis: assessing where the infection was acquired from. *Journal of travel medicine* 2010; **17**: 206-208

- 17 Sako Y, Itoh S, Okamoto M, Nakaya K, Ito A. Simple and reliable preparation of immunodiagnostic antigens for *Taenia solium* cysticercosis. *Parasitology* 2013; **140**: 1589-1594
- 18 Horton J. Albendazole: a review of anthelmintic efficacy and safety in humans. *Parasitology* 2000; 121 Suppl: S113-32
- 19 Dai YX, Shi CB, Cui BT, Wang M, Ji GZ, Zhang FM. Fecal microbiota transplantation and prednisone for severe eosinophilic gastroenteritis. *World J Gastroenterol* 2014; **20**: 16368-16371
- 20 Talley NJ, Shorter RG, Phillips SF, Zinsmeister AR. Eosinophilic gastroenteritis: a clinicopathological study of patients with disease of the mucosa, muscle layer, and subserosal tissues. *Gut* 1990; **31**: 54-58
- 21 Chen MJ, Chu CH, Lin SC, Shih SC, Wang TE. Eosinophilic gastroenteritis: clinical experience with 15 patients. *World J Gastroenterol* 2003; **9**: 2813-2816

Peer reviewer: Raffaele Capasso PhD, Department of Experimental Pharmacology, University of Naples Federico II, Via D. Montesano 49, I-80131 Naples, ITALY.