

Sarcina Ventricularis Complicating a Patient Status Post Vertical Banded Gastroplasty: A Case Report

Shaun AC Medicott, Fatin Adams

Shaun AC Medicott, Department of Pathology and Laboratory Medicine, Rockyview General Hospital, University of Calgary, Calgary, Alberta, Canada

Fatin Adams, Department of Internal Medicine, Gastroenterology, Rockyview General Hospital, University of Calgary, Calgary, Alberta, Canada

Correspondence to: Shaun Medicott MD, Rockyview General Hospital, Calgary Laboratory Services, Room 4N12, 7007, 14th Street SW, Calgary, Alberta, T2V 1P9, Canada

Email: shaun.medlicott@cls.ab.ca

Telephone: +1-403-943-3584

Fax: +1-403-943-3333

Received: December 6, 2014

Revised: January 15, 2015

Accepted: January 21, 2015

Published online: February 21, 2015

ABSTRACT

Herein we describe the first case of *Sarcina* species identified on gastric biopsy material from a patient status post bariatric surgery. As *Sarcina* species is known to rarely behave as a pathogen, its presence is noteworthy. Our patient was treated with antibiotics with resolution of bacterial overgrowth on repeat biopsies.

© 2015 ACT. All rights reserved.

Key words: *Sarcina ventricularis*; Bariatric surgery; Bacterial overgrowth

Medicott SA, Adams F. *Sarcina Ventricularis Complicating a Patient Status Post Vertical Banded Gastroplasty: A Case Report*. *Journal of Gastroenterology and Hepatology Research* 2015; 4(2): 1481-1484 Available from: URL: <http://www.ghrnet.org/index.php/joghr/article/view/950>

INTRODUCTION

Sarcina ventricularis is a known acid tolerant organism that rarely behaves as a pathogen, causing emphysematous gastritis and/or

perforation^[1-4]. A well documented predisposition to *Sarcina* species infection is overgrowth in the setting of gastroparesis or gastric outlet obstruction^[2-5]. Approximately half of all reported *Sarcina ventricularis* cases diagnosed on gastric biopsy have complicated those individuals with histories of upper gastrointestinal surgery^[2-4]. However, *Sarcina ventricularis* has yet to be documented in the bariatric surgery population. Herein we report the first case of *Sarcina ventricularis* overgrowth complicating a 53 year old female with probable diabetic gastroparesis, who is five years removed from a vertical banded gastroplasty procedure.

CASE REPORT

A 53 year old female presented with epigastric pain, post-prandial regurgitation and vomiting. In 2009 she had a vertical banded gastroplasty with a subsequent pouch ulcer diagnosed in 2011. She also has a history of a sliding hiatus hernia, irritable bowel, gastroesophageal reflux disease, diabetes, hypothyroidism and she is status post a remote cholecystectomy procedure. Present medications include: modulon, sulcrate, humalog victoza, synthroid and fenofibrate. She denies ethanol and illicit drug use.

She had an esophagogastroduodenoscopy which revealed abundant retained food in the distal stomach and polypoid mucosal lesions along the proximal- to mid-stomach staple line (Figure 1). A healed ulcer was evident in the pouch but no gastritis was noted. Endoscopic biopsies were procured from the antrum, body and polypoid lesions. Assessment of routine 4 µm hematoxylin and eosin stained slides revealed a mild chronic gastritis with rare organisms noted along the luminal surface of gastric body and polypoid mucosa (Figure 2). A gram stain proved the organisms to be gram positive cocci. There was negligible vital response to the organisms. No *Helicobacter pylori*, intestinal metaplasia or atrophy was identified.

MANAGEMENT

The patient was empirically treated with motilium 10 mg twice daily. When *Sarcina* was delineated in the laboratory, metronidazole 500 mg three times daily was initiated. A repeat

esophagogastroduodenoscopy was performed four months later. The proximal stomach anastomotic polyps persisted but had diminished in size. There was antral erythema of a linear antritis. Histology revealed reactive antral mucosa of a chemical gastropathy. All other mucosa was unremarkable including an absence of Sarcina and Helicobacter species.

DISCUSSION

Sarcina species was isolated as a human pathogen in 1842 by Goodsir^[5]. The organism manifested as a profuse frothy and yeasty vomiting illness in the setting of pyloric obstruction^[5]. Further study delineated positive Sarcina cultures almost exclusively in stool samples of healthy vegetarians compared to those who ate a mixed diet^[6]. This finding collaborates with the natural history of Sarcina disease in livestock (goats, cows) and horses whose herbivorous diet predisposes to abomasal bloat^[7,8].

Sarcina ventricularis is a gram positive coccus, an obligate anaerobe with a carbohydrate fermentative metabolism and consequent vigorous gas (carbon dioxide) production^[9]. The organism is exceptionally acid tolerant, growing in environments with a pH as low as 2^[10]. It has distinct morphology on routine histologic stains

allowing for a definitive diagnosis via microscopy^[3,4]. Individual cells are 1.8-to-3 μm but replicate along at least two planes of growth resulting in tetrad or octet units, the former 8-to-10 μm ^[9].

There have been nine relatively recent publications in English literature of Sarcina ventricularis in the human upper gastrointestinal tract^[1-4]. All patients were deemed to have gastric outlet obstruction or gastroparesis^[1-4]. In particular, four patients had compromised gastric emptying due to previous surgical interventions including a Billroth II procedure and truncal vagotomy for recalcitrant ulcers, small bowel resection for malrotation, gastric pull through for esophageal atresia and a pancreaticoduodenectomy for pancreatic adenocarcinoma^[2-4]. Our case is the fifth where Sarcina overgrowth complicates a patient with surgically altered gastroenteric anatomy (Table 1). Our patient is also predisposed to bacterial overgrowth in the stomach due to presumed diabetic gastroparesis.

Previous studies have delineated a management paradigm for Sarcina sp. The majority of cases represent an overgrowth of a commensal organism that potentially signifies an underlying anatomic and/or physiologic delay in gastric emptying^[3,4]. Such cases may not require pharmacologic intervention. However, if Sarcina organisms are identified in a patient with prominent dysphagia or substernal

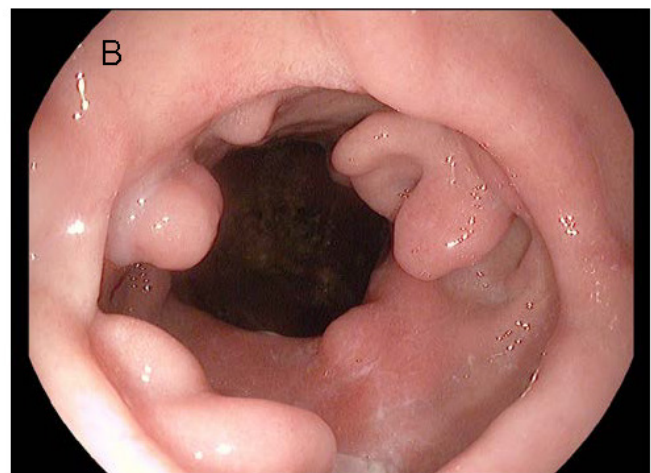
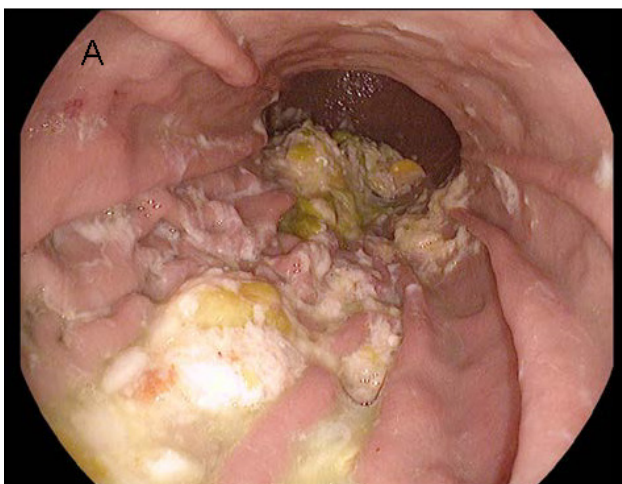


Figure 1 Sarcina sp. overgrowth is facilitated by retained food of a gastroparesis and/or outlet obstruction (A); Anastomosis site polypoid mucosa in our patient (B).

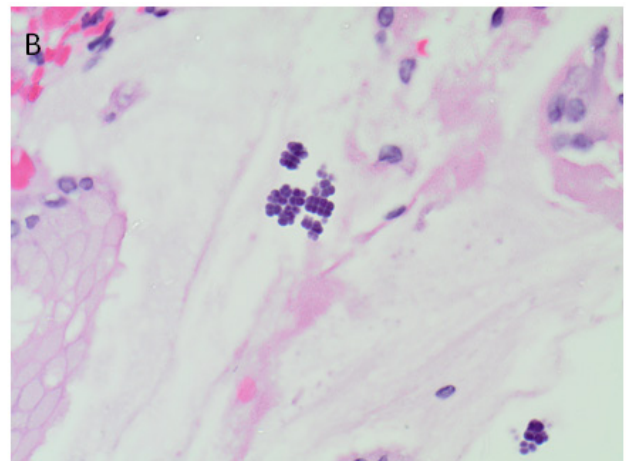
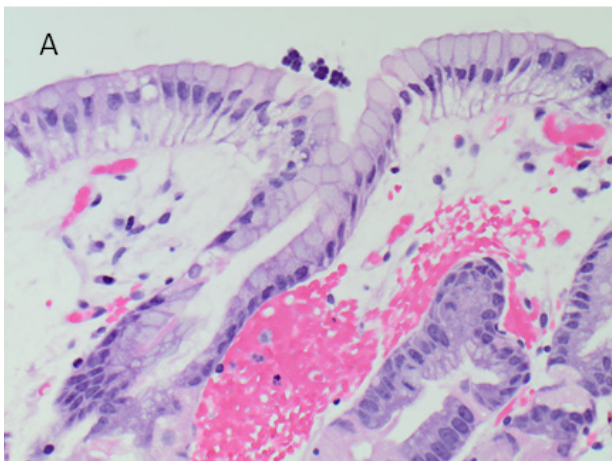


Figure 2 Each organism was 2-to-3 μm and they were arranged in tetrad and octet groups. Tetrad structures were 8-to-10 μm . This bacteria morphology is pathognomonic for Sarcina species, presumed Sarcina ventricularis. A is 40 \times and B is 60 \times , hematoxylin and eosin stain.

Table 1 Sarcina ventricularis in individuals status post gastrointestinal surgery.

Patient	Age/Sex	Surgical History	Symptoms	Surgical/Endoscopic Findings	Pathology Findings	Clinical outcome	Pathologic Outcome
1. Tolentino <i>et al</i>	14 year old male	Small bowel resection for malrotation 45 days prior	Abdominal pain and distension	Gastric perforation and necrotic fundus	Acute hemorrhagic gastritis Sarcina organisms	Gentamycin metronidazole. Fully recovered day 5	No follow up biopsy
2. Lam-Himlin <i>et al</i>	12 year old female	Gastric pull-through for esophageal atresia	Dysphagia	Retained food in stomach. Anastomosis stricture	Reflux esophagitis. Sarcina organisms	Lost to follow up	Lost to follow up
3. Lam-imlin <i>et al</i>	46 year old female	Whipple's procedure for pancreatic adenocarcinoma	Painful epigastric spasms	Bile and retained food	Chronic active duodenitis. Sarcina organisms	Continued spasms	No follow up biopsy
4. Ratuapli <i>et al</i>	73 year old male	Billroth II antrectomy and vagotomy 27 years prior	Iron deficiency anaemia	Retained food. Diffuse gastric erythema. Two 4 mm polyps at anastomosis site	Diffuse active gastritis. Bacteria overgrowth including Sarcina sp	Metronidazole, Ciprofloxacin and Sucralfate. 3 month follow up - no erythema, no bezoar	3 month follow up - chronic gastritis, negative for Sarcina
5. Medlicott and Adams	53 year old female	Vertical banded gastropasty 4 years prior.	Dyspepsia	Retained food, healed ulcer in pouch and polypoid anastomosis site	Mild chronic gastritis, Sarcina organisms	Motilium Metronidazole 4 month follow up - Antral erythema	4 month follow up - chemical gastropathy of antrum. negative for Sarcina

burning, combined proton pump inhibitor and prokinetic therapy is indicated^[3,4]. Finally, Sarcina organisms proliferating in an ulcerated or eroded stomach may cause sequela such as emphysematous gastritis or perforation^[1,2]. In this setting, eradication of the organism by antibiotics is recommended^[2,4]. Previous cases have been treated with either gentamycin and metronidazole or ciprofloxacin 250 mg twice daily and metronidazole 250 mg three times daily^[2,4]. As a healed ulcer was evident in our case, we decided to treat with metronidazole. Confirmation of Sarcina eradication warrants repeat endoscopy in three to six months^[4].

Individuals with obesity, gastroparesis and/or metabolic syndrome have an increased prevalence of stomach and intestinal bacterial overgrowth^[11,12,13]. This bacterial overgrowth can have deleterious consequences in the post-bariatric surgery population manifesting as liver toxicity and liver failure^[14]. The bariatric procedure Roux-en-Y is associated with a transition to a lean weight microbiota profile in the stomach six months post-operation and may facilitate weight loss^[15]. Proton pump inhibitor exposure may reverse this flora shift and propagate an obese microbiota profile, negating the benefits of surgical intervention^[15].

Certainly the microbiota landscape in the surgically resected stomach has implications for patient outcome. Sarcina ventricularis is one known gastric commensal that rarely behaves as a pathogen in the setting of gastroparesis and/or outlet obstruction. In our patient, there was no deleterious outcome and the organism was eradicated by antibiotics. However, our case delineates that the bariatric surgery population is at risk for Sarcina overgrowth. Additional examples of overgrowth need to be analyzed to discern if Sarcina sp. modifies the trajectory of weight loss in this patient cohort. As this agent is known to cause emphysematous gastritis and perforation in the eroded or ulcerated stomach, clinicians should be mindful of this bacterium when surveilling their bariatric surgery patient population.

CONFLICT OF INTERESTS

There are no conflicts of interest with regard to the present study.

REFERENCES

- Laass M, Pargac N, Fisher R, Bernhardt H, Knoke M, Henker J. Emphysematous gastritis caused by Sarcina ventriculi. *Gastrointest Endosc* 2010 Nov; **72(5)**: 1101-1103
- Tolentio LF, Kallichanda H, Javier B, Yoshimori R, French S. A case report of gastric perforation and peritonitis associated with opportunistic infection by Sarcina ventriculi. *Lab Med* 2003 July; **7(34)**: 535-537
- Lam-Himlin D, Tsiatis AC, Montgomery E, Pai RK, Brown JA, Razavi M, Lamps L, Eshleman JR, Bhagavan B, Anders RA. Sarcina organisms in the gastrointestinal tract: a clinicopathologic and molecular study. *Am J Surg Pathol* 2011 Nov; **35(11)**: 1700-1705
- Ratuapli SK, Lam-Himlin DM, Heigh RI. Sarcina ventriculi of the stomach: a case report. *World J Gastroenterol* 2013; **19(14)**: 2282-2285
- Goodsir J. History of a case in which a fluid periodically ejected from the stomach contained vegetable organisms of an undescribed form, with a chemical analysis of the fluid, by George Wilson. *Edinburgh Med Surg J* 1842; **57**: 430-443
- Crowther JS. Sarcina ventriculi in human faeces. *J Med Microbiol* 1971 Aug; **4(3)**: 343-350
- DeBey BM, Blanchard PC, Durfee PT. Abomasal bloat associated with Sarcina-like bacteria in goat kids. *J Am Vet Med Assoc* 1996 Oct 15; **209(8)**: 1468-1469
- Vatn S, Gunnes G, Nybø K, Juul HM. Possible Involvement of Sarcina ventriculi in canine and equine acute gastric dilatation. *Acta Vet Scand* 2000; **41(3)**: 333-337
- Kupfer DG, Parola-Canale E. Fermentation of glucose by Sarcina maxima. *J Bacteriol* 1968; **95**: 247-285
- Lowe SE, Pankratz HS, Zeikus JG. Influence of pH extremes on sporulation and ultrastructure of Sarcina ventriculi. *J Bacteriol* 1989; **171(7)**: 3775-3781
- Madrid AM, Poniachik J, Quera R, Defilippi C. Small intestinal clustered contractions and bacterial overgrowth: a frequent finding in obese patients. *Dig Dis Sci* 2011; **56**: 155-160
- George NS, Sankineni A, Parkman HP. Small intestinal bacterial overgrowth in gastroparesis. *Dig Dis Sci* 2014; **59**: 645-652
- Ishida RK, Faintuch J, Paula AM, Ristori CA, Silva SN, Gomes ES, Mattar R, Kuga R, Ribeiro AS, Sakai P, Barbeiro HV, Barbeiro DF, Soriano FG, Ceconello I. Microbial flora of the stomach after gastric bypass for morbid obesity. *Obes Surg* 2007; **17**: 752-758
- Ishida RK, Faintuch J, Ribeiro AS, Ribeiro U Jr, Ceconello I. Asymptomatic gastric bacterial overgrowth after bariatric surgery:

are long-term metabolic consequences possible? *Obes Surg* 2014; May 10 [Epub ahead of print]

- 15 Ward EK, Schuster DP, Stowers KH, Royle AK, Ir D, Robertson CE, Frank DN, Austin GL. The effect of PPI use on human gut microbiota and weight loss in patients undergoing laparoscopic Roux-en-Y gastric bypass. *Obes Surg* 2014 Sep; **24(9)**: 1567-1571

Peer reviewers: Timothy R. Koch, M.D., FACC, Professor of Medicine (Gastroenterology), Center for Advanced Laparoscopic & Bariatric Surgery, Washington Hospital Center, POB North, Suite 3400, 106 Irving Street NW, Washington, DC 20010, USA; Abdulzahra Hussain, General surgery department, Princess royal university hospital, Farnborough common, BR6 8ND, Orpington, Kent, UK.