

## Successful Endoscopic Treatment of Bleeding Anorectal Varices in a Patient with Advanced Pancreatic Cancer

Masayuki Nakanowatari, Takahiro Sato, Michio Iida, Jiro Honma, Takashi Fukuhara

Masayuki Nakanowatari, Michio Iida, Jiro Honma, Takashi Fukuhara, Department of Palliative Care Medicine, Sapporo Kosei General Hospital, Kita3 Higashi8-5, Chuo-ku, Sapporo, Hokkaido 060-0033, Japan

Takahiro Sato, Department of Gastroenterology, Sapporo Kosei General Hospital, Kita3 Higashi8-5, Chuo-ku, Sapporo, Hokkaido 060-0033, Japan

Correspondence to: Masayuki Nakanowatari, MD, Department of Palliative Care Medicine, Sapporo Kosei General Hospital, Kita3 Higashi8-5, Chuo-ku, Sapporo, Hokkaido 060-0033, Japan.

Email: [m.nakanowatari@ja-hokkaidoukouseiren.or.jp](mailto:m.nakanowatari@ja-hokkaidoukouseiren.or.jp)

Telephone: +81-11-261-5331 Fax: +81-11-271-5320

Received: December 9, 2014 Revised: January 9, 2015

Accepted: January 21, 2015

Published online: February 21, 2015

### ABSTRACT

A 78-year-old female with massive hematochezia showed an extra-hepatic portal vein obstruction (EHO) and rectal varices due to advanced pancreatic cancer with computed tomography (CT). Endoscopy revealed enlarged rectal varices and external anal varices with a reddish fibrin plug, and we diagnosed the rupture of anorectal varices near the anal verge. We first performed endoscopic injection sclerotherapy (EIS) for rectal varices under fluoroscopy. After EIS, endoscopic variceal ligation (EVL) was performed for the fibrin plug. Following treatment, the patient experienced no further episodes of bleeding during the three months up to her death.

© 2015 ACT. All rights reserved.

**Key words:** Rectal varices; Ectopic varices; Advanced pancreatic cancer; Extra-hepatic portal vein obstruction; Portal hypertension

Nakanowatari M, Sato T, Iida M, Honma J, Fukuhara T. Successful Endoscopic Treatment of Bleeding Anorectal Varices in a Patient

with Advanced Pancreatic Cancer. *Journal of Gastroenterology and Hepatology Research* 2015; 4(2): 1478-1480 Available from: URL: <http://www.ghrnet.org/index.php/joghr/article/view/963>

### INTRODUCTION

Anorectal varices due to an extra-hepatic portal vein obstruction (EHO) are rare in patients with portal hypertension. The occurrence of rectal varices varies among different reports (3.6-9%)<sup>[1,2]</sup>, accounting for 10% or less of patients with portal hypertension. According to a nationwide survey of ectopic varices in Japan from 2001 to 2005, rectal varices were the most common type of ectopic varices; the number of patients with rectal varices was 77<sup>[3]</sup>. The most frequent underlying cause of rectal varices was liver cirrhosis, accounting for 87%<sup>[3]</sup>. On the other hand, EHO, as seen in our patient, is relatively rare clinicopathological condition, accounting for 3% of rectal varices<sup>[3]</sup>.

Anorectal varices with massive bleeding are not common complications in patients with portal hypertension. The risk of rectal variceal rupture reported in the literature is somewhat variable (2-3.6%)<sup>[1,4,5]</sup>, accounting for 5% or less of patients with portal hypertension. However, once ruptured, they can be life-threatening. Endoscopic variceal ligation (EVL) can be an effective and safe treatment for bleeding anorectal varices, as seen in this case. Here, we report a case of ruptured anorectal varices resulting in massive bleeding which was successfully controlled by a combination of EVL and endoscopic injection sclerotherapy (EIS).

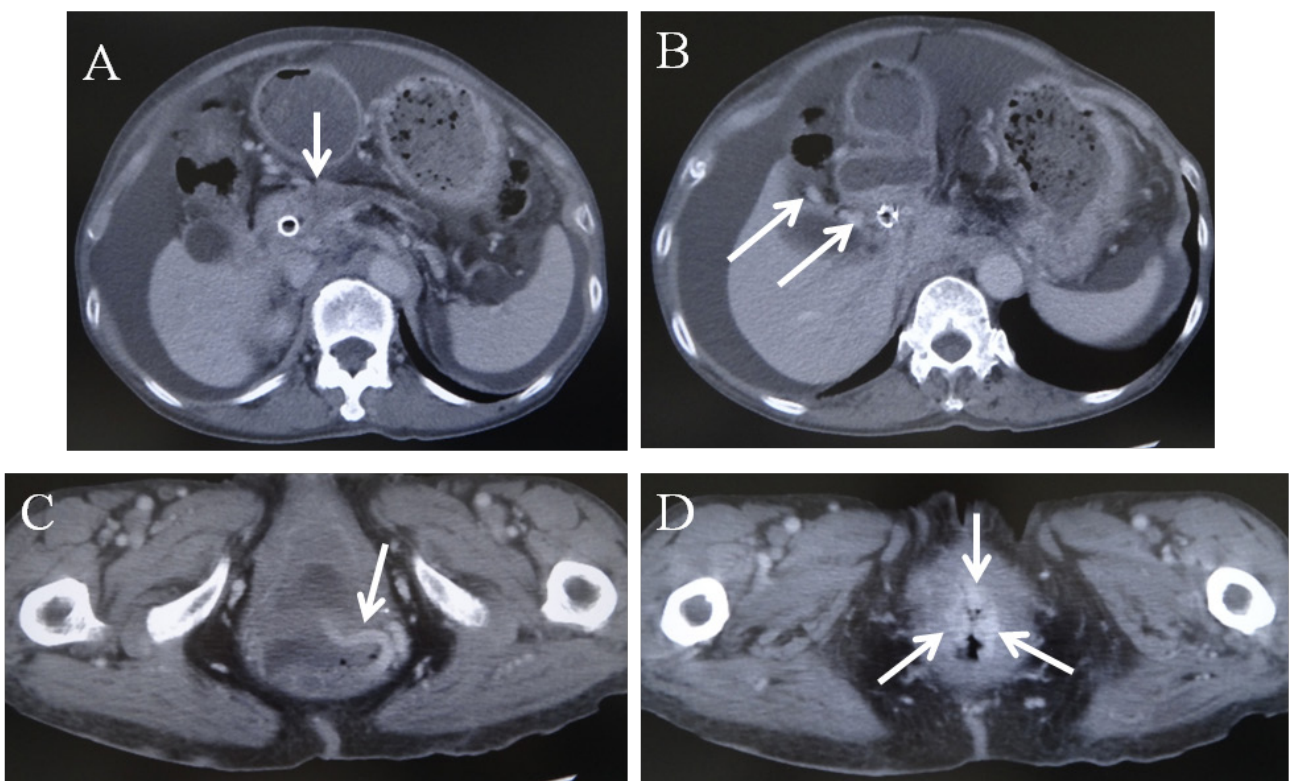
### CASE REPORT

A 78-year-old female, affected by epigastralgia, was diagnosed with advanced cancer of the pancreatic head in January 2012. Surgery was not indicated because of invasion to the portal vein and common hepatic artery. In February, chemotherapy was started in the Department of Gastroenterology of our hospital. However, it was discontinued due to adverse reactions, including nausea and taste disorder, and home care was provided. In June, occlusive jaundice was observed, and a biliary stent was inserted. In November,

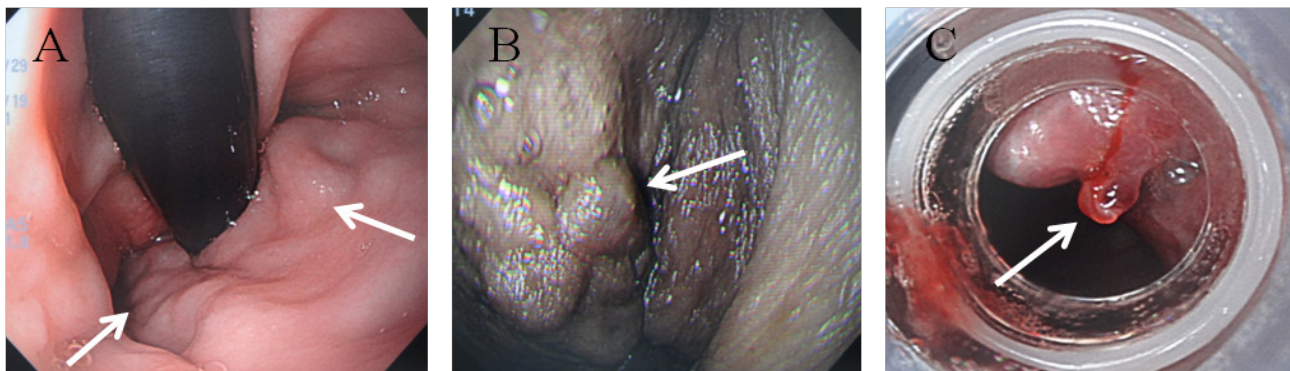
weakness of the limbs and flapping tremor were noted. The patient was admitted to the Palliative Care Unit (PCU) of our hospital with a diagnosis of hepatic encephalopathy. On December 17, marked hematochezia occurred suddenly. An abdominal contrast-enhanced computed tomography (CT) revealed an increase in the size of the pancreatic head tumor, ascites, EHO, development of cavernomatous transformation and dilation of the inferior mesenteric vein, and the superior rectal veins (Figure 1A-C). We diagnosed an EHO due to the advanced pancreatic cancer and rectal varices with portal hypertension. In addition, the vessel images of rectal varices were observed and hemorrhage from these sites was suspected (Figure 1D).

She had anemic conjunctivae and her hemoglobin level had dropped from 9.1 g/dL one month previously to 7.7 g/dL, however,

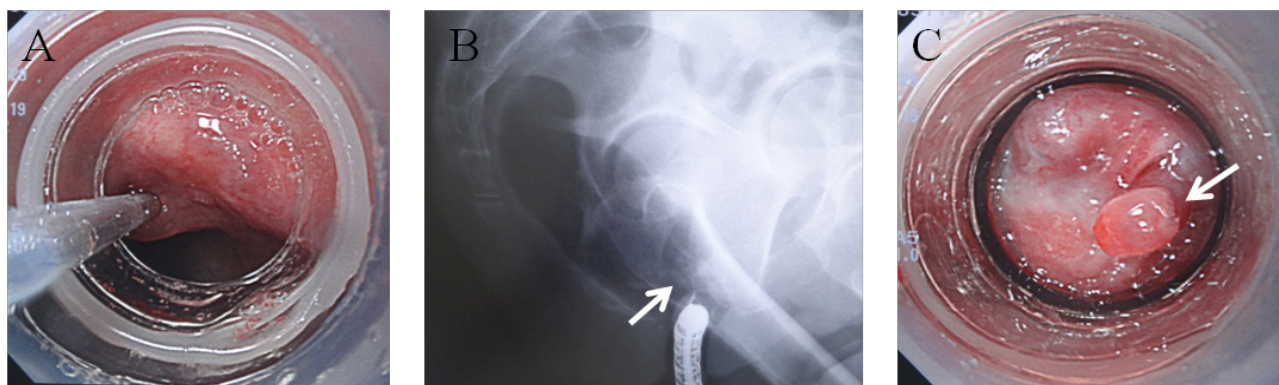
conservative treatment was chosen because of stable general condition. Two days later, hematochezia recurred and emergency endoscopy was carried out with a transparent hood attached. Red color-negative enlarged tortuous varices were observed in the rectal wall (Figure 2A), and protruding into the external anal zone (Figure 2B). Endoscopy revealed a reddish fibrin plug on the rectal varices near the anal verge (Figure 2C) and she was diagnosed with rupture of rectal varices near the anal verge. We first performed EIS for rectal varices under fluoroscopy (Figure 3A); 2 and 5 mL 5% ethanolamine oleate with iopamidol (EOI) were injected intermittently (total: 7 mL) (Figure 3B). Following EIS, EVL was successfully performed for the fibrin plug (Figure 3C). Her daily activity improved and she was doing well after treatment. She experienced no further episodes of bleeding during the three months up to her death.



**Figure 1** Abdominal contrast-enhanced computed tomography showing (A) increased size of the pancreatic head tumor (arrow), (B) development of cavernomatous transformation (arrows), (C) dilation of the superior rectal vein (arrow) and (D) 3 vessel images of rectal varices (arrows).



**Figure 2** (A) Endoscopy showing red color-negative enlarged tortuous varices (arrows); (B) External anal varices (arrow); (C) Endoscopy showing a reddish fibrin plug on rectal varices near the anal verge (arrow).



**Figure 3** (A) Endoscopic injection sclerotherapy for rectal varices under fluoroscopy; (B) Varicealography during endoscopic injection sclerotherapy (arrow); (C) Endoscopic variceal ligation for the fibrin plug (arrow).

## DISCUSSION

Rectal varices are portal systemic collaterals that manifest as discrete dilated submucosal veins and constitute a pathway for portal venous flow between the superior rectal veins of the inferior mesenteric system and the middle and inferior rectal veins of the iliac system<sup>[6]</sup>. Concerning the prediction of hemorrhage from rectal varices, Shudo *et al* reported that the prevalence of hemorrhage was significantly higher in patients with rectal varices of form and/or with a positive “red color (RC)” sign<sup>[1]</sup>. However, the RC sign is observed in only 40% of rectal varices<sup>[3]</sup>.

No consensus has been reached regarding the treatment of rectal varices. Surgical procedures, including transanal methods, are invasive for cirrhotic patients. Transjugular intrahepatic portosystemic shunt, percutaneous transhepatic obliteration, and double balloon-occluded embolotherapy are available as interventional radiology (IVR). However, these treatments are dependent on the patency of the portal vein and are not indicated for our patient because of the EHO.

Compared to surgery and IVR, endoscopic treatment is preferred more to treat rectal varices in Japan<sup>[3]</sup>. Maslekar *et al* suggested that EVL or EIS should be the first line of treatment, as these are easy methods of obtaining early control<sup>[7]</sup>. In particular, EVL is minimally invasive and shows marked hemostatic effects in emergency cases. EVL may be suitable as an initial treatment for rectal varices, but it appears that the varices can easily recur after treatment. Sato *et al* reported that the incidences of EVL-related rebleeding during 6 months and 1 year were approximately 20 and 50%, respectively, whereas that of EIS-related rebleeding was 0% over 2 years<sup>[8]</sup>. They demonstrated that EIS appeared to be superior to EVL with regard to long-term effectiveness and complications following endoscopic treatment of rectal varices in patients with portal hypertension<sup>[8]</sup>. In our case, we performed a combination of EVL and EIS on purpose of preventing rebleeding of rectal varices with relatively favorable general conditions.

Concerning precautions for EIS, it is necessary to avoid severe complications such as pulmonary embolism under fluoroscopy. The sclerosant should be slowly injected under fluoroscopy and an attached balloon to the endoscope be used, taking care to ensure that the agent does not flow into the systemic circulation<sup>[9]</sup>. In this patient, the sclerosant was intermittently injected at a small volume under fluoroscopy. It is thought that the volume of sclerosant during EIS for

treating anorectal varices is adequate when the superior rectal vein is shown. With that approach, EIS was conducted safely, with effective varicealography.

In this case, a combination of EVL and EIS was performed successfully for bleeding anorectal varices. Endoscopic treatment proved an effective and safe therapeutic method.

## CONFLICT OF INTERESTS

There are no conflicts of interest with regard to the present study.

## REFERENCES

- Shudo R, Yazaki Y, Sakurai S, Uenishi H, Yamada H, Sugawara K. Clinical study comparing bleeding and nonbleeding rectal varices. *Endoscopy* 2002; **34**(3): 189-194
- Rabinovitz M, Schade RR, Dindzans VJ, Belle SH, Van Thiel DH, Gavaler JS. Colonic disease in cirrhosis. *Gastroenterology* 1990; **99**: 195-199
- Watanabe N, Toyonaga A, Oho K, Kokubo S, Nakamura K, Hasmura A, Murashima N, Tajiri T. The present state of ectopic varices in Japan: the results of the questionnaire survey. *JJPH* 2009; **15**: 131-142 (in Japanese)
- Hosking SW, Smart HL, Johnson AG, Triger DR. Anorectal varices, haemorrhoids, and portal hypertension. *Lancet* 1989; **18**: 349-352
- McCormack TT, Bailey HR, Simms JM, Johnson AG. Rectal varices are not piles. *Br J Surg* 1984; **71**: 163
- Sato T, Yamazaki K, Toyota J, Karino Y, Ohmura T, Suga T. The value of the endoscopic therapies in the treatment of rectal varices: a retrospective comparison between injection sclerotherapy and band ligation. *Hepatol Res* 2006; **34**: 250-255
- Maslekar S, Toh EW, Adair R, Bate JP, Botterill I. Systematic review of anorectal varices. *Colorectal Dis* 2013; **15**: 702-710
- Sato T, Yamazaki K, Akaike J, Arakawa T, Kuwata Y, Nakajima T, Ozeki I, Ohmura T, Karino Y, Toyota J. Diagnosis and treatment of rectal varices. *Syoukaki Naishikyou* 2010; **25**(11): 1845-1850 (in Japanese, Abstract in English)
- Sato T, Yamazaki K, Akaike J. Evaluation of the hemodynamics of rectal varices by endoscopic ultrasonography. *J Gastroenterol* 2006; **41**: 588-592

**Peer reviewer:** Sang Wook Kim, 634-18 Keumam-dong, Dukjin-ku, Jeonju, Jeonbuk 561-712, South Korea.