

Two Cases of Diaphragmatic Hernia (Congenital and Post-Traumatic) Primarily Treated by Laparotomic Access: Critical Appraisal of Operative Strategy

Flavio Colaut, Nicola Clemente, Maurizio De Luca

Flavio Colaut, Nicola Clemente, Maurizio De Luca, Surgery Unit, City Hospital, via Montegrappa 1 31044 Montebelluna Italy
Correspondence to: Flavio Colaut, Surgery Unit, City Hospital, via Montegrappa 1 31044 Montebelluna Italy
Email: flavio.colaut@ulssasolo.ven.it
Telephone: +39 349 6039619
Received: October 28, 2015 Revised: February 12, 2016
Accepted: February 17, 2016
Published online: March 18, 2016

ABSTRACT

We report a case of congenital diaphragmatic hernia and a case of a post – traumatic one. Both of them have been treated by a laparoscopic access, but we think that for post – traumatic hernia particularly if delayed, thoracotomy could represent a better surgical approach. This is because if the abdominal viscera remain for long time into the pleural cavity, important adhesions develop into the pleural space so that reducing herniated viscera into abdomen could reveal difficult. Moreover if a tract of herniated bowel has to be resected because of necrosis, the surgeon can manage better the pleural cavity via a thoracotomic access, because adequate cleaning and washing can be performed.

© 2016 The Authors. Published by ACT Publishing Group Ltd.

Key words: Diaphragmatic hernia; Surgery

Colaut F, Clemente N, De Luca M. Two Cases of Diaphragmatic Hernia (Congenital and Post-Traumatic) Primarily Treated by Laparotomic Access: Critical Appraisal of Operative Strategy. *Journal of Respiratory Research* 2016; 2(1): 37-40 Available from: URL: <http://www.ghrnet.org/index.php/jrr/article/view/1452>

INTRODUCTION

Morgagni hernia consists of the migration of abdominal viscera into the thoracic cavity through a congenital defect of the parasternal part of the diaphragm. In adults, Morgagni hernia is asymptomatic or oligo symptomatic; in most cases, diagnosis is prompted by a chest X-ray prescribed for long lasting cough, dyspnea, chest discomfort or chronic obstructive intestinal symptoms^[1-2].

Surgical repair has been reported by both the laparotomic and thoracotomic route^[3]. With growing experience, laparoscopy has gained popularity as an effective mean for the treatment of this pathology^[4-5].

Post-traumatic diaphragmatic hernia can be diagnosed long after trauma; in up to 15 % of cases a late occurring complication leads to the diagnosis. Absence of a proper sac and consequent visceral adhesions, makes the thoracotomic route the preferred surgical approach early from trauma. Later thoracotomy seems to be a safer route for surgical repair.

CASE REPORT

Case report 1 Morgagni hernia

D.I. is a 84 years old female who was admitted because of coffee ground vomiting and symptoms and signs of intestinal obstruction. She had no previous history of abdominal or thoracic trauma. A gastroscopy was performed showing a hiatal hernia as well as an altered shape of the gastric body; most of the gastric wall was lined with superficially eroded and bleeding mucosa. The chest X-ray, performed on a routine base, showed a pathological enlargement of the lower mediastinum (Figure 1).

These findings were further investigated by CT which demonstrated the migration of the stomach in almost its entirety into the anterior mediastinal space along with the middle third of the

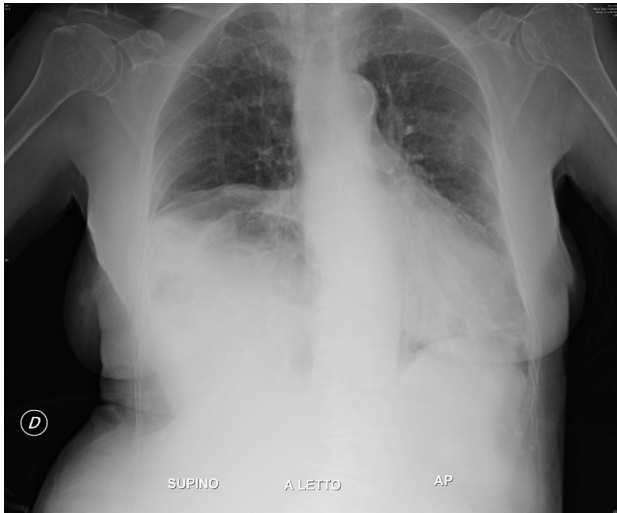


Figure 1 Morgagni hernia: chest X-ray showing a pathological enlargement of the mediastinum.

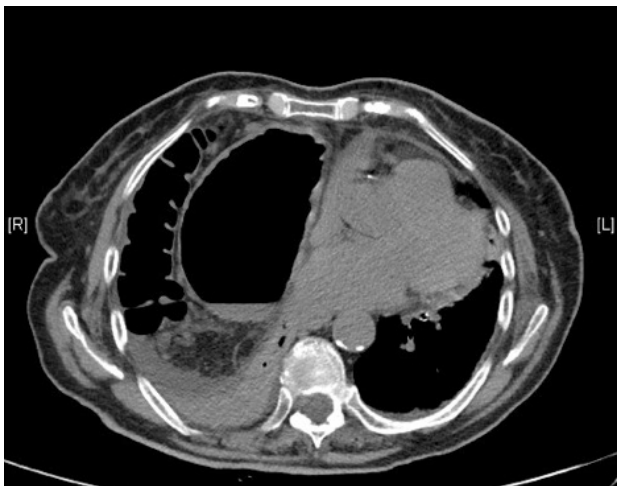

Figure 2 Morgagni hernia: CT image showing migration of stomach (in almost its entirety) and the middle third of the transverse colon into the anterior mediastinal space and right emithorax.

transverse colon (Figure 2).

A laparoscopic approach was attempted first. Dense adhesions between the herniated organs and organs and the hernia sac, made the laparoscopic dissection unsafe. To avoid any damage, a laparotomic access was gained. Herniated viscera were easily repositioned into the abdominal cavity (Figure 3).

The diaphragmatic defect was repaired by suturing the anterior and posterior rim of the orifice together and with the posterior rectal muscles sheath (Figure 4). One drain was placed into the former hernia cavity corresponding to the mediastinal anterior space; the other one was placed in the subphrenic space just below the suture. The post-operative course was uneventful and the patient was discharged in good health conditions the 8th post-operative day.

Case report 2 Post - traumatic hernia

A 63 years old man D.B.L. was admitted in our Unit because of a left thoracic empyema. The patient reported that the previous year he had occurred into a blunt thoracic trauma (car accident) with multiple left rib fractures. The pre-operative CT demonstrated herniation of bowel loops into left thoracic cavity. By laparotomy, the herniated small bowel loops were repositioned into the peritoneal cavity. One

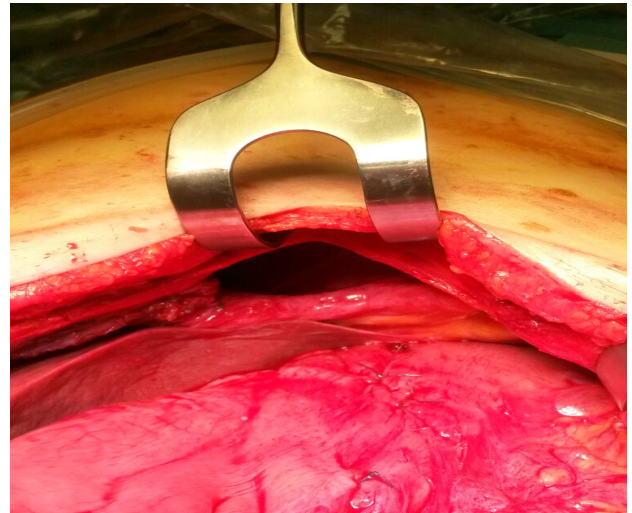


Figure 3: Morgagni hernia: diaphragmatic defect after the herniated viscera have been repositioned into the abdominal cavity.

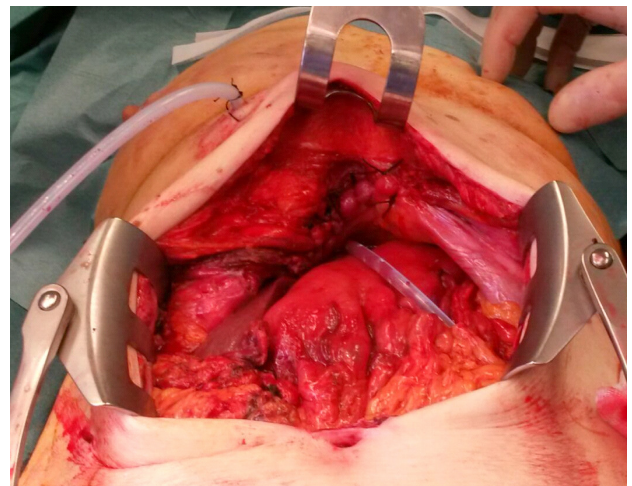


Figure 4 Morgagni hernia: the diaphragmatic defect is repaired by suturing the anterior and posterior rim of the orifice together and with the posterior rectal muscles sheath.

of them was resected because of extensive necrosis. The thoracic cavity was thoroughly cleaned with multiple washings. A drain was placed into the thoracic cavity and the defect was directly repaired by suturing the diaphragm. Eight months after discharge, the patient was readmitted for recurrent left empyema.

During bronchoscopy a fistulography was made demonstrating a fistulous broncho-pleuric tract (Figure 5).

A preoperative CT showed massive left recurrent empyema (Figure 6).

A left thoracotomy was performed and the thickened and inflamed fibrous pleura was removed by surgical decortication. The post operative course was uneventful so the patient was discharged the 8th post-operative day in good general and local conditions.

DISCUSSION

Morgagni hernia, like Bochdalek hernia, is a congenital defect of the diaphragm. In particular, Morgagni hernia results from the failure of the anterior parasternal region of the diaphragm to close or fuse^[6]; the consequent muscular-fascial defect (so called Larrey's space) is the locus minoris resistentiae through which abdominal contents

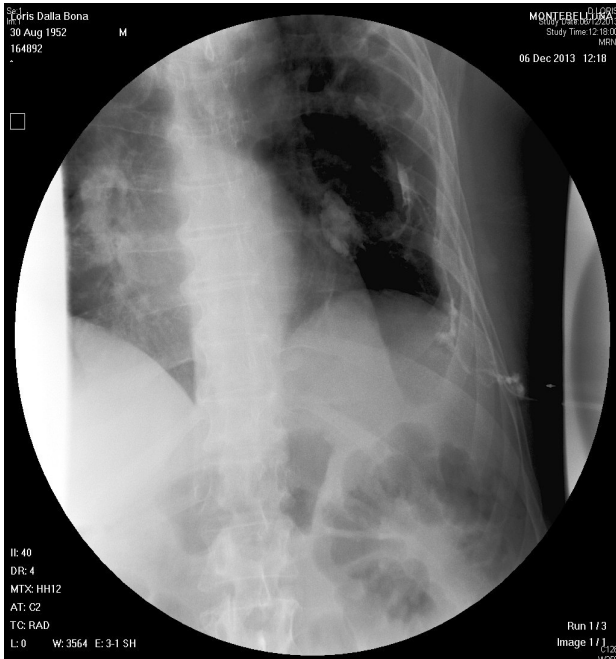

Figure 5 Post traumatic diaphragmatic hernia: fistulography demonstrating a fistulous broncho-pleuric tract.

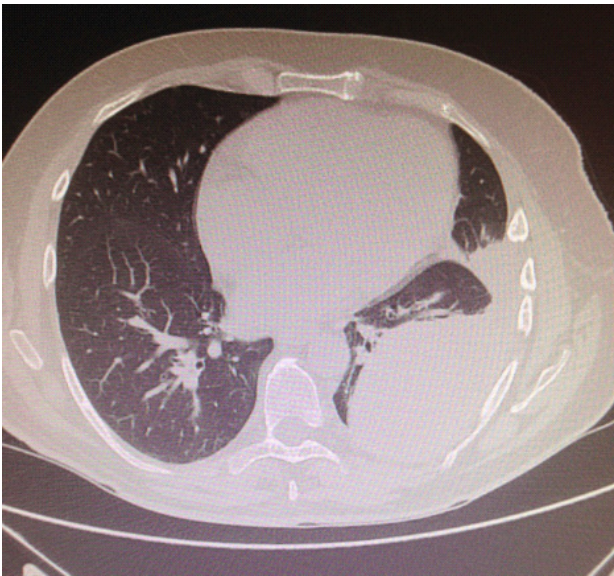


Figure 6 Post traumatic diaphragmatic hernia: CT image showing left empyema which recurred after intervention for post-traumatic diaphragmatic hernia complicated by intestinal necrosis.

can herniate into the thorax (Figure 7). Most commonly the defect is on the right side^[7] (though rare bilateral hernias have also been described) and this is where the sac is more likely to expand. The content is variably represented by the omentum, the stomach, the small and/or large bowel.

During childhood, Morgagni hernia is usually asymptomatic and therefore goes undiagnosed. In adult life, though rarely (as it represents only an estimated 2% of adult diaphragmatic hernias) it is more likely to be diagnosed. This probability increases with age and obesity. Diagnosis is mostly incidental; sometimes it is led by non-specific symptoms such as long lasting cough, dyspnea, retrosternal discomfort or chronic obstructive intestinal symptoms. Rarely adult Morgagni hernia can have an acute presentation when gastric, small and/or large bowel obstruction occurs. In this cases a

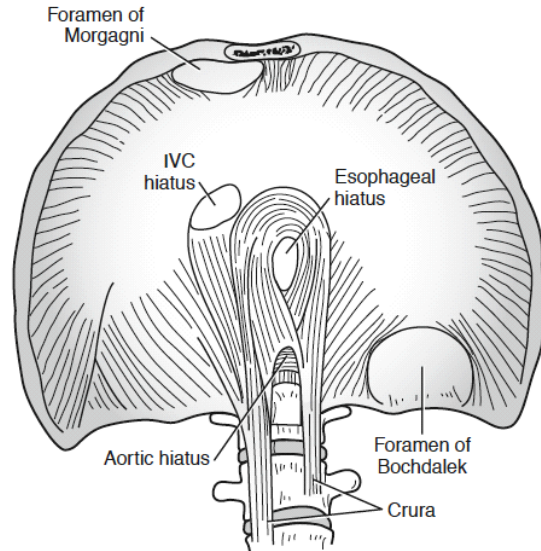


Figure 7 Diaphragmatic hernias: classic locations of Bochdalek and Morgagni hernias.

prompt diagnosis is mandatory as the obstruction could be led by a strangulation or a volvulus which are able to jeopardize the vitality of the herniated organs. Surgical repair involves reduction of the herniated viscera into the abdomen, with resection of the hernial sac and diaphragmatic repair. The last mentioned step is usually accomplished primarily because Morgagni hernias are usually small and can be closed without a patch. In case of larger defects, a prosthetic mesh^[8-9] or autologous muscle flaps are options. Surgical approach through the abdomen, rather than through the thorax, is almost universally considered the strategy of choice.

Indeed, Morgagni hernia, even if involves a long lasting visceral herniation due to its congenital nature, always has a proper hernial sac which prevent adhesions with thoracic and mediastinal organs. Adhesions are rather more likely to be found inside the sac and between the herniated organs and these can be properly addressed by abdominal access^[10]. All that considered, the risks of thoracotomic access (respiratory failure) outnumber its benefits.

Even in the emergency setting, laparotomy seems preferably. Indeed, in case of ischaemic necrosis due to strangulation or volvulus, laparotomic access makes resections and anastomoses far more straightforward. Moreover, in case of gangrenous necrosis by intestinal strangulation, the presence of a sac prevents bacterial translocation into the pleural and mediastinal spaces. This decreases the need for thoracic cleaning and draining.

These considerations are supported by the first case we reported here. Though extremely dense, adhesions were easily taken down by laparotomy, with no need of thoracic access. Similarly, by the same laparotomic route, the repair of the hernial defect was carried out with no difficulty.

The second case we reported, demonstrates that, on the other hand, post-traumatic diaphragmatic hernia, though amenable of laparotomic-laparoscopic treatment, can be better managed by thoracic access. In newly developed post-traumatic diaphragmatic hernia, contamination of the pleural cavity due to concomitant visceral injuries is more likely. A thoracic access is undoubtedly a far better mean to clean the pleural cavity, reduce the bacterial load and prevent later empyema. This principle, as in the case we operated on, applies also to post-traumatic diaphragmatic hernia diagnosed long after trauma. In this setting, concomitant visceral injuries are not likely. Yet, if an ischaemic gangrenous process is ongoing as a

result of a volvulus or strangulation, bacterial spread into the thorax and mediastinum can be overwhelming in absence of a hernial sac. This was exactly the case of D.B.L. . Contamination from intestinal necrosis was so widespread that abdominal access was insufficient to provide adequate cleaning and draining of the pleural cavity and to prevent later thoracic empyema.

Actually, a reoperation with pleural decortication by thoracic access was therefore mandatory.

CONCLUSIONS

The laparotomic and, more recently, the laparoscopic access are considered effective and safe for the treatment of diaphragmatic hernias. This applies both to the congenital Morgagni hernias and to the post traumatic ones. The content of both hernia types is represented by abdominal viscera; consequently reduction and, in case of ischaemic or traumatic damage, resection or repair of herniated organs are easily accomplished by this route.

Nevertheless, in some cases, thoracic access can be a far more judicious strategy despite concerns of greater invasiveness. Indeed it has the advantage of allowing better cleaning of thoracic cavity, reducing the chance of septic complications such as empyema. According to our experience, thoracic access is highly recommended in long - dated post - traumatic diaphragmatic hernias, in which bacterial contamination is a concern, as in case of associated traumatic injuries or ischaemic injuries to the herniated viscera.

CONFLICT OF INTERESTS

The authors declare that they do not have conflict of interests.

REFERENCES

1. Colako O, Hacıyanlı M, Soyuturk M, Colako G: Morgagni hernia in an adult atypical presentation and diagnostic difficulties. *Turk J Gastroenterol* 2005;16:114-6
2. Kaya SO, Aytenkin F, Liman ST, Telkin K, Yagci B: Morgagni hernia presented with acute gastric obstruction and mediastinal shift. *Firat Tıp Dergisi* 2005 10:27-9
3. Horton JD, Hoffman LJ, Hetz SP: Presentation and management of Morgagni hernias in adults: a review of 298 cases. *Surg Endoscop* 2008 22:1413-20
4. J.M. Sheigar, A.D. Dalal, J.L. Patel: Laparoscopic repair of a Morgagni hernia. *J Min Access Surg* 2005 1:76-78
5. Shuhai Li, Xiaochuan Liu, Yaxing Shen: Laparoscopic repair of Morgagni hernia by artificial pericardium patch in an adult obese patient. *J Thorac Dis* 2015;7(4):754-757
6. L. A. Arráez-Aybar, C. C. González-Gómez, A. J. Torres-García: Morgagni-Larrey parasternal diaphragmatic hernia in the adult. *Rev Esp Enferm Dig* 2009; 101 (5): 357-366
7. Harrington S. Various types of diaphragmatic hernia treated surgically. *Surg Gynecol Obstet* 1948; 86: 735-755.
8. F Puglisi, P.Capuano,O.Caputi Iambrenghi: Laparoscopic repair of Morgagni hernia in an adult: use of a porcine small intestine submucosa biocompatible prosthesis. *Chirurgia Italiana* 2009; 61(3): 351-356
9. M. Mahir Özmen, T. Tolga Şahin, Serkan Özen, Şahnaz İsgenderova: Laparoscopic Repair of Morgagni Hernia in The Adults: Report of Two Cases. *Eur J Endosc Laparosc Surg* 014;1(2):88-91
10. E. Gedik, M.C. Tuncer, S. Onat, A. Avci, I. Tacyıldız, B. Bac: A review of Morgagni and Bochdalek hernias in adults *Folia Morphol.*, 2011, Vol. 70, No. 1