

Implantation of Metallic Stent Under Direct Visualization of Flexible Bronchoscope Without Fluoroscopic Guidance on Orotracheal Intubated Patients

Wei-Hua Xu, Hao Xu, Geng Zhang, Ma-Hong Hu, Fei-Yan Lou, Hui-Ping Hu, Tie-Jun Wang

Wei-hua Xu, Respiration Department of Tongde Hospital of Zhejiang Province, Gucui Road #234, 310012, Hangzhou, China

Hao Xu, Respiration Department of the Second Affiliated Hospital of Zhejiang University School of Medicine, Jiefang Road #88, 310009, Hangzhou, China

Geng Zhang, Ma-hong Hu, Tie-jun Wang, Intensive Care Unit of Tongde Hospital of Zhejiang Province, Gucui Road #234, 310012, Hangzhou, China

Fei-yan Lou, Hui-ping Hu, Endoscopy Department of Tongde Hospital of Zhejiang Province, Gucui Road #234, 310012, Hangzhou, China

Wei-hua Xu and Hao Xu contributed equal to this study.

Correspondence to: Wei-hua Xu, Respiration Department of Tongde Hospital of Zhejiang Province, Gucui Road #234, 310012, Hangzhou, China.

Email: xwhzju@163.com

Telephone: +86-571-89972427

Fax: +86-571-89972067

Received: May 20, 2016

Revised: June 18, 2016

Accepted: June 20, 2016

Published online: September 16, 2016

ABSTRACT

BACKGROUND: Stent implantation has been used to liberate patients with severe airway stenosis and respiratory failure from mechanical ventilation; however, a rare clinical study is reported about metallic stent implantation via a flexible bronchoscope without using fluoroscopic guidance in ventilated patients.

AIM: The present retrospective study aims to evaluate the feasibility, safety, efficacy, and complications of using a flexible bronchoscope without fluoroscopy to implant metallic stent in mechanically ventilated patients.

METHODS: From April 2015 to April 2016, eight tracheobronchial metallic stents were implanted in six respiratory failure patients associated with central airway stenosis or fistula. First, a

bronchoscope was inserted through an endotracheal tube into the trachea or bronchus, and a guide wire was placed into the stenosis site. The bronchoscope was reintroduced into the airway outside the endotracheal tube. Under bronchoscopic visualization, the delivery catheter was advanced over the guide wire to deploy the stent.

RESULTS: These procedures were successfully performed in all patients, with three stents placed in the trachea and five stents in the main bronchus. The patients were all successfully liberated from mechanical ventilation. Five patients suffered from cough after the procedure. One patient, who received a covered metallic stent implantation in the left main bronchus, experienced increased mucus production. Granulation tissue formation was found in one patient. No patient presented with any stent migration or pneumothorax.

CONCLUSIONS: It is concluded that metallic stents can be safely implanted under the direct visualization of a bronchoscope without using fluoroscopic guidance in patients with respiratory failure to wean the patients from mechanical ventilation.

Key words: Bronchoscopy; Respiratory failure; Stent; Mechanical ventilation

© 2016 The Authors. Published by ACT Publishing Group Ltd.

Xu WH, Xu H, Zhang G, Hu MH, Lou FY, Hu HP, Wang TJ. Implantation of Metallic Stent Under Direct Visualization of Flexible Bronchoscope Without Fluoroscopic Guidance on Orotracheal Intubated Patients. *Journal of Respiratory Research* 2016; 2(3): 75-78 Available from: URL: <http://www.ghrnet.org/index.php/jrr/article/view/1751>

INTRODUCTION

Self-expandable metallic stents (SEMSs) have been widely used to treat patients with airway stenosis^[1-3]. SEMSs can be implanted using a flexible bronchoscope^[4], rigid bronchoscope^[5-6], or combined bronchoscopic and fluoroscopic guidance^[7], or under the control of fluoroscopy^[8].

For some patients who have severe airway stenosis possibly obstructing their respiration, mechanical ventilation has to be used to treat their respiratory failure. Due to successfully solving the problems of airway stenosis, a stent implantation has been regarded as an effective method of liberating these patients from mechanical ventilation^[9-10]. Rigid bronchoscopy with general anesthesia^[11] and flexible bronchoscopy under fluoroscopic guidance^[9] are the most common methods of stent implantation in mechanically ventilated patients, especially for those patients who are not appropriated for surgical intervention. However, rigid bronchoscopy requires special facilities that may not be available in every hospital. Fluoroscopy exposes patients and pulmonologists to X-ray radiation. In addition, a flexible bronchoscope is operated more popularly than a rigid bronchoscope. Thus, using a flexible bronchoscope without fluoroscopic guidance to implant SEMSs in mechanically ventilated patients is potentially promising for pulmonologists; however, rare clinical studies are reported about this topic.

The present study describes the implantation of SEMSs under the direct visualization of a flexible bronchoscope without fluoroscopic guidance in 6 orotracheal intubated patients and aims to evaluate the feasibility, safety, efficacy, and complications of this procedure.

MATERIALS AND METHODS

Patients

From April 2015 to April 2016, eight tracheobronchial SEMSs were implanted in six patients with respiratory failure associated with central airway stenosis or fistula. Informed consent was obtained from each patient or their guardian before stent implantation. Five patients had late-stage malignant diseases. One patient suffered from tracheobronchomalacia. Due to illness severity, late-stage malignant tumor, high surgical risk, or surgical refusal, none of these patients were candidates for surgery or stent implantation under rigid bronchoscopy. The baseline characteristics of the patients are shown in Table 1. Before the procedure, all of the patients received orotracheal intubation and assistant/control mode ventilation because of respiratory failure. All of the patients underwent pulse oximeter and arterial line monitoring for oxygen saturation and blood pressure. Ventilator liberation was defined as successful if reintubation was not required within 48 hours after endotracheal extubation.

This study was performed in accordance with the Ethical Council Guide of Tongde Hospital of Zhejiang Province (Hangzhou, China).

Bronchoscopic procedure

Ultraflex SEMSs (Boston Scientific, Natick, MA, USA) and Wallstent SEMSs (Micro-Tech (Nanjing) Co., Ltd, Nanjing, China) were used in the present study. The patients received SEMS implantation by means of flexible bronchoscopy (BF260, Olympus, Tokyo, Japan) without fluoroscopic guidance. The length and type of the metallic stent (with or without a cover) for each patient were evaluated by an endoscopic examination and a chest computed tomography (CT) scan, if a CT scan was available, before stent implantation. Each patient underwent flexible bronchoscopy as follows: The patient was administered intravenous midazolam (5 mg) and a local anesthetic with 2% of xylocaine solution. In some cases where midazolam did not provide enough sedation for the operation, patients received intravenous propofol (1.5 mg/kg in 1 minute then 4 mg/kg hour).

First, the bronchoscope was inserted into the trachea through

the hole of a tracheal tube extension (Covidien Inc, Mansfield, MA, USA), which connects the ventilator and orotracheal tube (Kyoling OC-01, Jinlin Medical Appliances Company, Hangzhou, China). The pulmonologist inspected and evaluated the airway stenosis under the direct visualization of the bronchoscope. If the lesion was at a level higher than the tip of the endotracheal tube, the tube was withdrawn slightly to provide enough view and space for the stent implantation. After determining the type of stent to be used, the bronchoscope reached the proximal end of the lesion. A guide wire was inserted via the working channel of the bronchoscope and passed through the lesion. The bronchoscope was withdrawn, and the guide wire was left at the lesion site. The bronchoscope was then reintroduced through a nostril into the space between the tracheal wall and the orotracheal tube to inspect the location of the guide wire. When the bronchoscope started to reach the balloon cuff of the intubated tube, air inside the balloon cuff was sucked out by a syringe to save enough space for the passing bronchoscope. At the same time, the concentration of oxygen from the ventilator was elevated to 100% to keep the patient's peripheral blood oxygen saturation above 95%. Under bronchoscopic visualization, the delivery catheter (Micro-Tech (Nanjing) Co., Ltd, Nanjing, China, or Boston Scientific, Natick, MA, USA) was inserted over the guide wire into the lesion airway to deploy the metallic stent. The delivery catheter, guide wire, and bronchoscope were then withdrawn consecutively, and the stent was left in the lesion site. After completion of the stent deployment, the balloon cuff of the intubated tube was inflated again, and the bronchoscope was introduced through the tracheal tube extension to check the position of the stent. If adjustment of the stent position was required, biopsy forceps (Micro-Tech (Nanjing) Co., Ltd, Nanjing, China) were used to hold the proximal or distal ring of the stent and pull or push the stent to the fine position. Before finishing the bronchoscopic procedure, sputum in the trachea and bronchus was sucked out by means of a bronchoscope. The operation time was defined as the time from first inserting the bronchoscope for inspection of the lesion to ending sputum clearance.

Each patient underwent an X-ray examination or CT scan 12-24 hours after the SEMS implantation. CT scan was firstly suggested. If the patients refused CT scan, X-ray examinations were performed. After an assessment of the stent position and an evaluation of the patient's clinical condition, the extubation of the orotracheal tube was performed. A bronchoscopy was performed 1 week, 1 month, and 3 months after the stent implantation to evaluate the position and integrity of the stent and to confirm if there was granuloma formation around the metallic stent. If respiratory failure recurred, an endotracheal tube was inserted, and mechanical ventilation was used. When airway stenosis reappeared or when intractable coughing, increased mucus production, or stent-related symptoms occurred, an additional bronchoscopic operation was performed for further therapy.

Statistical analysis

Data of operation time were expressed as mean \pm SD.

Table 1 Patients' baseline characteristics.

Case	Gender	Age	Diagnosis	Stenosis site
1	Male	57	Oesophageal cancer	L
2	Male	68	Lung cancer	L and R
3	Female	46	Thyroid cancer	T
4	Female	51	Cervical cancer	T
5	Female	79	Tracheobronchomalacia	L
6	Male	68	Lung cancer	T and L

L: left main bronchus; R: right main bronchus; T: trachea.

RESULTS

All procedures were performed successfully. The detailed data of stents are shown in Table 2. The operation time was 8.81 ± 1.86 minutes. There was no desaturation less than 90% or hypotension (systolic blood pressure less than 90 mmHg) during or after the bronchoscopic operation.

Malignant diseases contributed to lesions in five patients, including esophageal cancer, lung cancer (two patients), thyroid cancer, and cervical cancer with mediastinal metastasis. One patient suffered from tracheobronchomalacia with the complication of recurrent severe pneumonia in the left lower lobe. The esophageal cancer patient suffered a tracheoesophageal fistula with the complication of severe pulmonary infection. Because of central airway stenosis and/or severe infection, every patient had respiratory failure and received mechanical ventilation. After stent implantation, all of the patients were successfully liberated from ventilators.

Five patients suffered from cough after stent implantation; however, the coughing symptoms were not severe. After use of antitussive medications, including Robitussin or Asmeton, the cough of these patients was fully or partially controlled. Increased mucus production emerged from the esophageal cancer patient who received a covered metallic stent implantation in the left main bronchus. This patient had to be operated on using a bronchoscope to clean the sputum once a week.

During the 3-month follow-up period (case numbers 5 and 6 had follow-up periods less than 1 month), granulation tissue formation was found in the left main bronchus of the lung cancer patient (case number 2). The granulation tissue obstructed the left main bronchus less than 30% and was successfully treated by cryotherapy.

No stent migration or pneumothorax occurred in the patients during the 3-month follow-up period.

DISCUSSION

Central airway stenosis is commonly formed from airway compression, airway obstruction, and airway invasion. The etiology contains malignant tumors and benign diseases^[12-13]. Procedures of pulmonary intervention, including ablation of argon^[14], laser resection^[15], and stent implantation, are used to treat malignant airway stenosis.

Airway stent implantation mainly involves a silicon stent^[16] and a metallic stent. The placement of a silicon stent requires rigid bronchoscopy, which refrains it from wide use. Flexible bronchoscopy is becoming popular in metallic stent implantation^[17-20]. However, because of its connection to the ventilator, rigid bronchoscopy is more appropriate for stent implantation in those patients whose airway stenosis is so severe that they cannot respire sufficiently without ventilator support. These patients need endotracheal intubation and mechanical ventilation. Flexible bronchoscopy under fluoroscopy^[9] is also performed frequently on intubated and ventilated patients for metallic stent implantation. Flexible bronchoscopy without fluoroscopy is rarely used in these patients due to the following reasons:

The diameter of the stent delivery catheter used in the present study is 4.0 mm [Micro-Tech (Nanjing) Co., Ltd, Nanjing, China] or 5.3 mm (Boston Scientific, Natick, MA, USA). The inner diameter of an endotracheal tube is 8.0 mm, and the diameter of a flexible bronchoscope is 5.9 mm (BF260, Olympus, Tokyo, Japan). Either the delivery catheter or bronchoscope can be successfully inserted into the endotracheal tube, and some space inside the tube is saved for

ventilation; however, it is not available for simultaneous insertion of the delivery catheter and bronchoscope. Essentially, it needs another way for the bronchoscope or stent delivery catheter when the catheter or bronchoscope passes through the tracheal tube. The average diameter of an adult trachea is 20 mm^[21]. After tracheal intubation, there is enough space (the diameter is about 9.3 mm) for a bronchoscope passing outside the endotracheal tube because the outer diameter of tracheal tube is 10.7 mm (Figures 1 and 2).

Simultaneously inserting a stent delivery catheter through an endotracheal tube and a bronchoscope through an airway outside the tube guarantees successful SEMS implantation under the direct visualization of a bronchoscope. However, it raises another question. The balloon cuff needs to be deflated to save enough space for a bronchoscope to pass; meanwhile, the stent delivery catheter is in the tracheal tube. The latter decreases ventilation, and the former increases the risk of air leakage from the ventilator. Will the patient

Table 2 Patients' metallic stents implantation data.

Case	Stent manufacturer	Stent type	Operation time
1	Micro-Tech (Nanjing)	Covered, 14×50 mm	9.6 min
2	Micro-Tech (Nanjing)	Uncovered, 14×30 mm (L)	8.2 min
		Uncovered, 12×40 mm (R)	5.6 min
3	Micro-Tech (Nanjing)	Uncovered, 18×50 mm	10.8 min
4	Micro-Tech (Nanjing)	Uncovered, 18×50 mm	11.5 min
5	Boston Scientific	Uncovered, 16×40 mm	8.7 min
6	Boston Scientific	Uncovered, 16×60 mm (T)	7.5 min
		Uncovered, 14×40 mm (L)	8.6 min

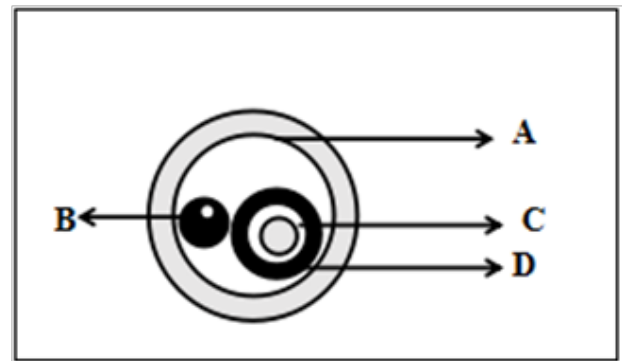


Figure 1 Cross-section of a schematic plot of simultaneously inserting a bronchoscope outside an orotracheal tube and a stent delivery catheter inside an orotracheal tube. "A" represents the tracheal wall with a diameter of 20.0 mm; "B" represents a flexible bronchoscope with an outer diameter of 5.9 mm and a working channel of 2.0 mm; "C" represents a delivery catheter with an outer diameter of 4.0 mm; and "D" represents an orotracheal tube with an outer diameter of 10.7 mm and an inner diameter of 8.0 mm.

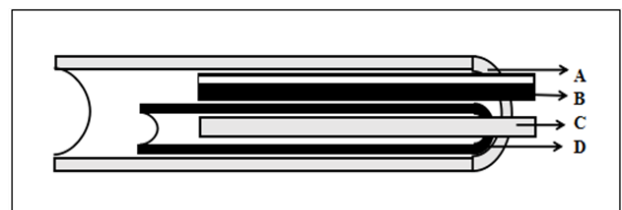


Figure 2 Sagittal plane of a schematic plot of simultaneously inserting a bronchoscope outside an orotracheal tube and a stent delivery catheter inside an orotracheal tube. "A" represents the tracheal wall with a diameter of 20.0 mm; "B" represents a flexible bronchoscope with an outer diameter of 5.9 mm and a working channel of 2.0 mm; "C" represents a delivery catheter with an outer diameter of 4.0 mm; and "D" represents an orotracheal tube with an outer diameter of 10.7 mm and an inner diameter of 8.0 mm.

receive sufficient ventilation? The results of the previous research^[10] and the present study all showed that patients received enough oxygen support during the operation.

There were at least two tips supporting the bronchoscopic procedure's success. The first was the elevation of the oxygen concentration. The patients in these two studies all received 100% oxygen support during the operations. The second was that, for a bronchoscope and stent delivery catheter, the smaller tool was left in the endotracheal tube, and the bigger one passed outside tube. This method produced relatively more sufficient ventilation and less air leakage. In the previous study^[10], the catheter passed outside the tube, and a bronchoscope was inserted through the tube. The diameter of a No. 22 Fr delivery catheter (Boston Scientific) used in the previous study^[10] is 7.26 mm. It is bigger than the diameter of a bronchoscope. Therefore, a delivery catheter passing outside of the endotracheal tube in the previous study was reasonable. Despite all of this, a catheter is encouraged to be inserted through an endotracheal tube because a catheter is less flexible than a bronchoscope. Winding through an airway outside a tracheal tube needs more skill and time. It might be an important reason that the operation time of the present study was less than that of the previous study^[10]. In addition, an ultra-thin bronchoscope with an outer diameter of about 1.8-2.8 mm may be inserted simultaneously with a delivery catheter into a tracheal tube to implant a metallic stent. It needs more experience in the future.

The present method of SEMS implantation, using a flexible bronchoscope without the guidance of fluoroscopy, was successful in all of the orotracheal intubated patients with acute respiratory failure mainly due to central airway stenosis. The time required for the stent implantation was 8.81 ± 1.86 minutes. Ventilators were successfully liberated from all patients after SEMS implantation. No life-threatening complications developed as a result of this procedure. These outstanding outcomes prove that SEMSs can be successfully implanted in the orotracheal intubated patients under the direct visualization of a flexible bronchoscope without the guidance of fluoroscopy. However, a number of cases in the present study are limited. More operations and longer follow-up need to be performed, and more experience need to be summed up.

In conclusion, the present study describes successful SEMS implantation in six mechanically ventilated patients under the direct visualization of a flexible bronchoscope without the guidance of fluoroscopy. This procedure is feasible, safe, efficient, and timesaving. It can successfully liberate patients from ventilators.

CONFLICT OF INTERESTS

The authors have not conflicts of interest to declare.

REFERENCES

- Marchese R, Poidomani G, Paglino G, et al. Fully covered self-expandable metal stent in tracheobronchial disorders: clinical experience. *Respiration* 2015; **89**: 49-56.
- Plojoux J, Laroumagne S, Vandemoortele T, et al. Management of benign dynamic "A-shape" tracheal stenosis: a retrospective study of 60 patients. *Ann Thorac Surg* 2015; **99**: 447-53.
- Dutau H, Musani AI, Plojoux J, et al. The use of self-expandable metallic stents in the airways in the adult population. *Expert Rev Respir Med*. 2014; **8**: 179-90.
- Yuasa R, Hata Y, Otsuka H, et al. Placement of self-expandable metallic stents for tracheal stenosis secondary to thyroid cancer. *Mol Clin Oncol* 2014; **2**: 1003-1008.
- Madan K, Dhoria S, Sehgal IS, et al. A Multicenter Experience With the Placement of Self-Expanding Metallic Tracheobronchial Y Stents. *J Bronchology Interv Pulmonol* 2016; **23**: 29-38.
- Serio P, Fainardi V, Leone R, et al. Tracheobronchial obstruction: follow-up study of 100 children treated with airway stenting. *Eur J Cardiothorac Surg* 2014; **45**: e100-109.
- Inchingolo R, Sabharwal T, Spiliopoulos S, et al. Tracheobronchial stenting for malignant airway disease: long-term outcomes from a single-center study. *Am J Hosp Palliat Care* 2013; **30**: 683-689.
- Chen G, Wang Z, Liang X, et al. Treatment of cuff-related tracheal stenosis with a fully covered retrievable expandable metallic stent. *Clin Radiol* 2013; **68**: 358-364.
- Espinoza A, Neumann K, Halvorsen PS, et al. Critical airway obstruction: challenges in airway management and ventilation during therapeutic bronchoscopy. *J Bronchology Interv Pulmonol* 2015; **22**: 41-47.
- Lin SM, Lin TY, Chou CL, et al. Metallic stent and flexible bronchoscopy without fluoroscopy for acute respiratory failure. *Eur Respir J* 2008; **31**: 1019-1023.
- Dincq AS, Gourdin M, Collard E, et al. Anesthesia for adult rigid bronchoscopy. *Acta Anaesthesiol Belg* 2014; **65**: 95-103.
- Murgu S, Egressy K, Laxmanan B, et al. Central airway obstruction: benign strictures, tracheobronchomalacia and malignancy-related. *Chest* 2016; doi: 10.1016/j.chest.2016.02.001.
- Ranu H, Madden BP. Endobronchial stenting in the management of large airway pathology. *Postgrad Med J* 2009; **85**: 682-687.
- Reichle G, Freitag L, Kullmann HJ, et al. Argon plasma coagulation in bronchology: a new method--alternative or complementary? *Pneumologie*. 2000; **54**: 508-516
- Hansen G, Sundset A. Transbronchial laser ablation of benign and malignant tumors. *Minim Invasive Ther Allied Technol* 2006; **15**: 4-8.
- Tsakiridis K, Darwiche K, Visouli AN, et al. Management of complex benign post-tracheostomy tracheal stenosis with bronchoscopic insertion of silicon tracheal stents, in patients with failed or contraindicated surgical reconstruction of trachea. *J Thorac Dis* 2012; **4 Suppl 1**: 32-40.
- Saad CP, Murthy S, Krizmanich G, et al. Self expandable metallic airway stents and flexible bronchoscopy: long-term outcomes analysis. *Chest* 2003; **124**: 1993-1999.
- Serrano C, Laborda A, Lozano JM, et al. Metallic stents for tracheobronchial pathology treatment. *Cardiovasc Intervent Radiol* 2013; **36**: 1614-1623.
- Fuehner T, Wiesner O, DeWall C, et al. Self-expanding metallic stent placement with laryngeal mask in lung transplant recipients. *Transplant Proc* 2010; **42**: 4595-4599.
- Choudhary C, Gildea TR, Salman R, et al. Management of tracheomediastinal fistula using self-expanding metallic stents. *Ann Thorac Surg*. 2008; **85**: 1800-1802.
- Breatnach E, Abbott GC, Fraser RG. Dimensions of the normal human trachea. *AJR Am J Roentgenol* 1984; **142**: 903-906.

Peer reviewers: Carlos Galvez, MD, Thoracic Surgery Unit, University General Hospital of Alicante, C/Pintor Baeza, 12, 03010 Alicante, Spain; Mohamed Shehata, Köln, Germany.