

CASE REPORT

Tracheal Diverticulum: A Rare Entity Diagnosed in the Context of Blunt Thoracic Trauma Report of A Case

Nicola Clemente, Flavio Colaut, Maurizio De Luca, Alessandro Berardino Di Marco, Alberto Sartori

Nicola Clemente, Flavio Colaut, Maurizio De Luca, Alberto Sartori, Department of General Surgery and Thoracic, City Hospital, Montebelluna, Treviso, Italy
Alessandro Berardino Di Marco, Pneumology, City Hospital, Montebelluna, Treviso, Italy

Conflict-of-interest statement: The author(s) declare(s) that there is no conflict of interest regarding the publication of this paper.

Open-Access: This article is an open-access article which was selected by an in-house editor and fully peer-reviewed by external reviewers. It is distributed in accordance with the Creative Commons Attribution Non Commercial (CC BY-NC 4.0) license, which permits others to distribute, remix, adapt, build upon this work non-commercially, and license their derivative works on different terms, provided the original work is properly cited and the use is non-commercial. See: <http://creativecommons.org/licenses/by-nc/4.0/>

Correspondence to: Flavio Colaut, Department of General Surgery and Thoracic, City Hospital, Montebelluna, Treviso, Italy.
Email: flavio.colaut@ulssasolo.ven.it
Telephone: +393496039619

Received: July 13, 2017

Revised: August 7, 2017

Accepted: August 9, 2017

Published online: September 12, 2017

ABSTRACT

Tracheal diverticulum (TD) is an outpouching or sac arising from the wall of the trachea. It can be classified, based on etiology, in congenital and acquired. Congenital tracheal diverticulum is the consequence of a defect in endodermal differentiation of the membranous posterior tracheal wall and it contains all the layers of the airway wall (true diverticulum). Acquired diverticulum is the result of an abnormally increased pressure inside the airways pushing the respiratory mucosa out of a defect of the airway wall; it contains only mucosa (pseudodiverticulum). Both types are rare, accounting only for a limited percentage of the paratracheal air cysts

(PTACs) from which TD should be differentiated in consideration of the similar basic pattern of “paratracheal air collection”. Diagnosis of TD is difficult because of its rarity, lack of symptomatology or specific symptomatology and low sensibility of the diagnostic tools available to date (chest CT and bronchoscopy). Apart from its intrinsic rarity, the case of TD we present here has the peculiarity of being diagnosed, differently from usual, by direct bronchoscopic visualization. The blunt thoracic trauma of which the patient was victim, gives more exemplarity to the diagnostic pathway of this entity. Indeed the detection of a para tracheal air collection on CT images could have been interpreted as a traumatic rupture of the trachea rather than a TD, leading to an unjustified surgical treatment. It was only clinical judgment combined with the use of the diagnostic imaging and bronchoscopy that conducted to the correct diagnosis.

Key words: Tracheal diverticulum

© 2017 The Author(s). Published by ACT Publishing Group Ltd. All rights reserved.

Clemente N, Colaut F, De Luca M, Di Marco AB, Sartori A. Tracheal Diverticulum: A Rare Entity Diagnosed in the Context of Blunt Thoracic Trauma Report of A Case. *Journal of Respiratory Research* 2017; 3(2-3): 109-111 Available from: URL: <http://www.ghrnet.org/index.php/jrr/article/view/2111>

INTRODUCTION

Tracheal diverticulum is a rare entity consisting of an outpouching or sac arising from the wall of the trachea. We present here a case of TD diagnosed in a patient with blunt thoracic trauma.

CASE REPORT

A 60 years old man reported a blunt thoracic trauma after falling from three meters high. He was conducted to the Emergency Department of our hospital and CT of the chest was carried out. A right scapula fracture with fragmentation and multiple ribs fracture (ninth, eleventh and twelfth right rib) were diagnosed. Moreover, an air collection of about 14 × 8 mm was found in the right paratracheal area, apparently in communication with the airway lumen (Figures 1, 2, 3).

A diagnostic bronchoscopy was scheduled the following day. Under conscious sedation, the bronchoscope was introduced through the nasal fossa. At the border of the upper third with the lower two thirds of the trachea, dorsally and slightly on the right of the median line, a little orifice was demonstrated (Figure 4).

The presence of this diverticulum was confirmed by the presence of air bubbles jus below it (Figure 5).

A traumatic origin of this orifice was ruled out because of the integrity of the mucosa and the absence of signs of endoluminal bleeding. The diagnosis of tracheal diverticulum was clear. Aspiration of endobronchial fluids was carried out for routine microbiological and citological analysis which later resulted within normal range.

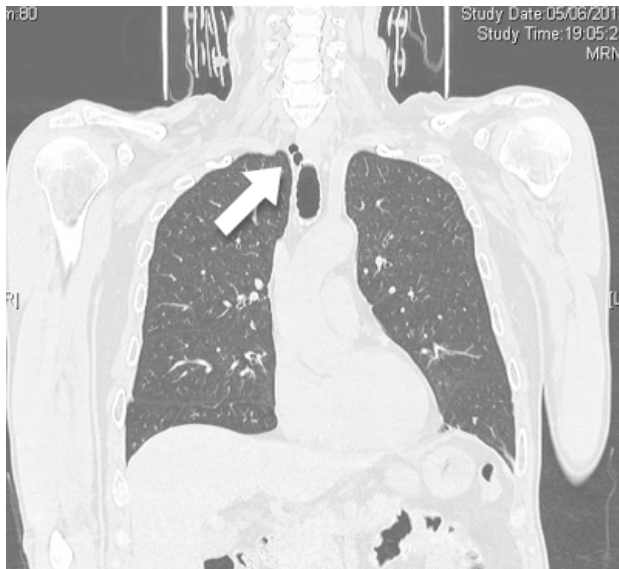


Figure 1 Tracheal diverticulum: CT frontal scan showing a right paratracheal air collection (arrow).

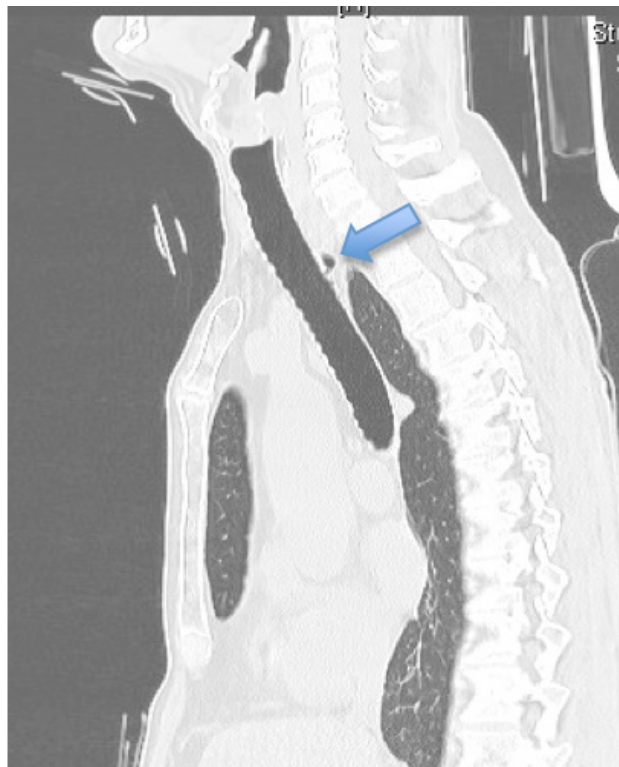


Figure 2 Tracheal Diverticulum: CT sagittal scan showing a paratracheal air collection (arrow).

The patient was treated conservatively because no complication developed as a consequence of the thoracic trauma. Indeed he was discharged in good health condition seven days after admission. A medical therapy based on pain killers was prescribed; a control chest X-ray and a follow-up visit in our outpatient clinic was scheduled ten days after discharge. No surgical treatment of the tracheal diverticulum was planned as the patient was asymptomatic.

DISCUSSION

Tracheal diverticulum (TD) consists of small air collection in the paratracheal area. It is a rare entity with an estimated incidence of 2.4%^[1]. In most cases TD is located at the right posterolateral region of the trachea (97.1%) and rarely at the contralateral side (2.9%)^[1]. It is lined by the same ciliated columnar epithelium of the trachea and

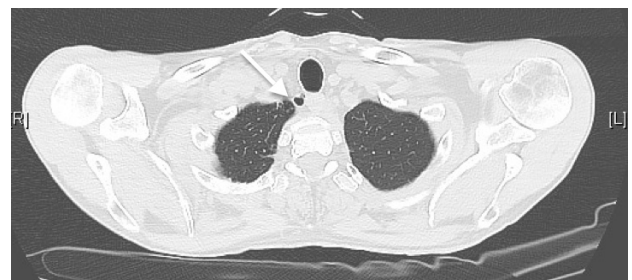

Figure 3 Tracheal Diverticulum: CT assial scan showing a paratracheal air collection (arrow).

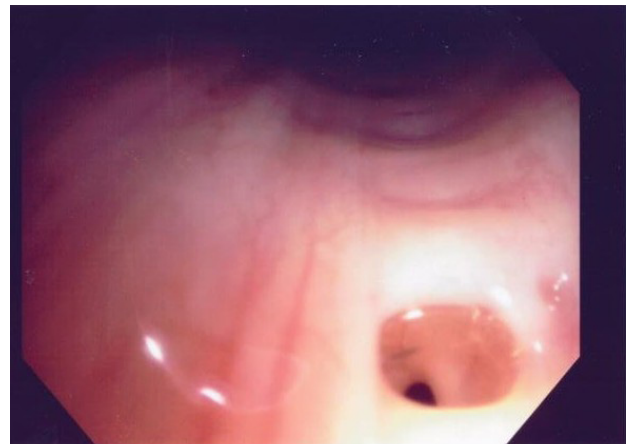


Figure 4 Tracheal diverticulum: direct visualization of the diverticulum orifice by bronchoscopy.

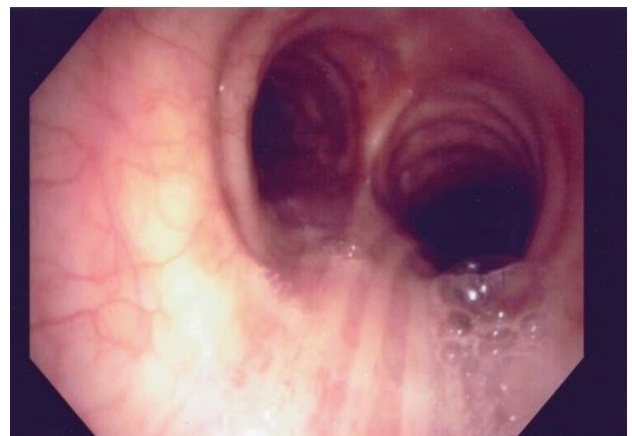

Figure 5 Tracheal diverticulum: air bubbles as an indirect sign of the presence of the TD.

its lumen is in communication, though often difficult to demonstrate, with that of the airways. These features enable to differentiate TD from other paratracheal air cysts (PTACs) such as tracheoceles, lymphoepithelial cysts and bronchogenic cysts. These entities which share the same radiological aspect of “air collection” have an altogether incidence of 0.75-8.1%^[2-4].

Tracheal diverticula can be congenital or acquired

Congenital tracheal diverticula are thought to be the consequence of a defect in endodermal differentiation of the membranous posterior tracheal wall^[5]. As a consequence, all the layers of the airways (respiratory epithelium, smooth muscle and cartilage) are involved and can be demonstrated within the wall of the diverticulum at pathological examination (true diverticulum). Congenital diverticula are reported to be more common in males, smaller than the acquired counterpart and generally located 4-5 cm below the vocal cords or just above the carina. Connection with the trachea is so narrow that it can be hardly demonstrated by bronchoscopy.

Acquired tracheal diverticula occur as a complication of surgical procedure or as a result of tracheomalacia; whatever the cause, an area of weakness in the tracheal wall develops. A long standing increased pressure inside the airways, such as in obstructive lung disease, emphysema and chronic cough, pushes the mucosa out of the defect. As a result, the acquired diverticulum is made of respiratory mucosal lining only, is wide mouthed and larger in size (pseudodiverticulum). Moreover it is usually located at the level of the thoracic inlet between the extrathoracic and intrathoracic area. Acquired diverticula can be single or multiple and, when multiple, a tracheobronchomegaly or Mounier-Kuhn disease can be claimed^[6-7].

Symptoms related to TD are chronic cough, dyspnea, stridor or recurrent tracheobronchitis^[8]. Dysphagia, odynophagia, neck pain, hoarseness, hemoptysis, choking, recurrent episodes of hiccups and/or burping have also been described^[9]. Compression of the laryngeal nerves can lead to dysphonia. Several cases of paratracheal abscesses have been described in the literature following infection of a TD.

Nevertheless the great majority of tracheal diverticula, both congenital and acquired, are asymptomatic. Diagnosis is incidental following a chest CT. Multidetector computed tomography is considered the best method to demonstrate a TD. It is able to show the exact location, size and contour and wall thickness. If the CT scans are thinner than 1 mm, a communication between TD and trachea can be seen. Presence of such communication could not be equally obvious at bronchoscopy because TD can have a very narrow opening or it can be joined to the trachea by a fibrous tract only. Though communication of TD with the tracheal lumen enables differential diagnosis from other paratracheal air cysts which don't have such connection.

The rarity of TD is that sheer and simple diagnosis of this entity deserves some mention. Yet the case we observed had some further peculiarities that makes it worth of consideration. First, diagnosis was based not only on chest CT which showed a paratracheal air collection with a likely communication with the airway lumen but, differently from usual, by bronchoscopy also. Indeed bronchoscopy was able to directly visualize the orifice of the TD. This enabled differential diagnosis from other PTACs.

Secondly, the context of blunt thoracic trauma of our case made

diagnosis of TD challenging. Indeed the detection of a para tracheal air collection on CT images could have been misinterpreted as a traumatic rupture of the trachea leading to unjustified surgical treatment. Clinical judgment supported by the absence of other signs and symptoms of tracheobronchial injury, led to a more cautious treatment plan. The following bronchoscopy correctly diagnosed a TD.

CONCLUSIONS

Tracheal diverticulum is a rare entity to be distinguished by other paratracheal air cysts. Diagnosis is often difficult because of lack of specific symptomatology, and low sensibility of even invasive procedures such as bronchoscopy. The case of TD reported here has the peculiarity of being diagnosed by a rare combination of CT images and bronchoscopic direct visualization. Clinical judgment, guided by the above mentioned diagnostic tools, avoided a first-instance, yet wrong, diagnosis of traumatic laceration of trachea and enabled the correct treatment of the patient.

REFERENCES

1. Kurt A, Sayit AT, Ipek A, Tatar IG. A multi detector computed tomography survey of tracheal diverticulum. *Eurasian J Med* 2013; **45**: 145-8. [PMID: 25610271]; [PMCID: PMC4261431]; [DOI: 10.5152/eajm.2013.31]
2. Goo JM, Im JG, Ahn JM, Moon WK, Chung JW, Park JH, Seo JB, Han MC. Right paratracheal air cysts in the thoracic inlet: clinical and radiologic significance. *AJR Am J Roentgenol* 1999; **173**: 65-70 [PMID: 10397101]; [DOI: 10.2214/ajr.173.1.10397101]
3. Buterbaugh JE, Erly WK. Paratracheal air cysts: a common finding on routine CT examinations of the cervical spine and neck that may mimic pneumomediastinum in patients with traumatic injuries. *AJNR Am J Neuroradiol* 2008; **29**: 1218-21. [PMID: 18544671]; [DOI: 10.3174/ajnr.A1058]
4. Bae HJ, Kang EY, Yong HS, et al. Paratracheal air cysts on thoracic multidetector CT: incidence, morphological characteristics and relevance to pulmonary emphysema. *Br J Radiol* 2013; **86**: 20120218. [DOI: 10.3174/ajnr.A1058]
5. Tanaka H, Mori Y, Kurokawa K, Abe S. Paratracheal air cysts communicating with the trachea: CT findings. *J Thorac Imaging* 1997; **12**: 38-40 [PMID: 8989757]
6. Bhatnagar V, Lal R, Agarwala S, et al. Endoscopic treatment of tracheal diverticulum after primary repair of esophageal atresia and tracheoesophageal fistula. *J Pediatr Surg* 1998; **33**: 1323-4 [PMID: 722017]
7. Lazzarini-de-Oliveira LC, Costa de Barros Franco CA, Gomes de Salles CL, et al. A 38-year-old man with tracheomegaly, tracheal diverticulosis, and bronchiectasis. *Chest* 2001; **120**: 1018-20 [PMID: 11555541]
8. Srivastava A, Guitron J, Williams VA. Tracheal diverticulum: an atypical presentation. *J Thorac Cardiovasc Surg* 2014; **148**: 3244-5. [PMID: 24725771]; [DOI: 10.1016/j.jtcvs.2014.03.010]
9. Akabane S, Kawachi J, Fukai R, Kashiwagi H, Ogino H, Watanabe K. A rare case of an infected tracheal diverticulum requiring emergency intervention: A case report. *Int J Surg Case Rep* 2016; **24**: 7-9. Epub 2016 May 6. [PMID: 27176502]; [PMCID: PMC4872469]; [DOI:10.1016/j.ijscr.2016.04.051]

Peer reviewer: Mariano García-Yuste