

Supply of the Alveoli With Blood and Circulation in the Alveoli

Ivanov K.P.

I.P. Pavlov, Institute of Physiology, Russian Acad. Sci., Sankt-Petersburg, Nab. Makarova, 6. 199034, Russia

Conflict-of-interest statement: The author(s) declare(s) that there is no conflict of interest regarding the publication of this paper.

Open-Access: This article is an open-access article which was selected by an in-house editor and fully peer-reviewed by external reviewers. It is distributed in accordance with the Creative Commons Attribution Non Commercial (CC BY-NC 4.0) license, which permits others to distribute, remix, adapt, build upon this work non-commercially, and license their derivative works on different terms, provided the original work is properly cited and the use is non-commercial. See: <http://creativecommons.org/licenses/by-nc/4.0/>

Correspondence to: I.P. Pavlov, Institute of Physiology, Russian Acad. Sci., Sankt-Petersburg, Nab. Makarova, 6. 199034, Russia
Email: kpivanov@nc2490.spb.edu
Telephone: +7-921-921-2330

Received: October 9, 2017

Revised: December 2, 2017

Accepted: December 5, 2017

Published online: December 25, 2017

ABSTRACT

With the help of new devices and methods an attempt was made to study circulation in the lungs between the alveoli and in the very alveoli on the lungs in an almost intact thorax of white rats. Alveoli were shown to receive the blood from a dense network of microvessels 20-50 μm in diameter contrary to previous concepts about single thin microvessels supplying each alveolus. Efficient oxygenation of the blood was shown to be attained by spreading the blood in a thin layer over the whole surface of the inner coating of an alveolus and by rotation of this layer in the alveolus.

Key words: Blood flow in the lungs; Maximal blood flow in the lungs

© 2017 The Author(s). Published by ACT Publishing Group Ltd. All rights reserved.

Ivanov KP. Supply of the Alveoli With Blood and Circulation in the Alveoli. *Journal of Respiratory Research* 2017; 3(4): 125-128 Available from: URL: <http://www.ghrnet.org/index.php/jrr/article/view/2154>

The videos of this paper are linked as follow:

https://drive.google.com/file/d/0B-gaA67uGJ2PmRSM0xrV3B3Sms/view?usp=drive_web

https://drive.google.com/file/d/0B-gaA67uGJ2PSHJHUIRON29nQTg/view?usp=drive_web

INTRODUCTION

The lungs supply an organism with energy, i.e. with oxygen. It is clear that the mechanisms of oxygen transport and of energy transformations in the lungs are the most important of all the physiological processes in an organism. An adequate supply of an organism with oxygen requires an extremely lavish circulation in the lungs. It is surprising that despite such an important function of the lungs in the development of an organism and in maintaining its life the construction of circulation in the lungs and especially in the alveoli is practically terra incognita, i.e. an enigma up to now. So far the important details of circulation in the lungs are little-known. The matter is that nonphysiological methods are used for studying the circulation in the lungs – the work on isolated lungs or their separate sections^[1,2,3,4]. Sometimes the attempts to study circulation are made on frozen lungs. The main trend in the study of the structure of circulation system in the lungs was given by Miller^[5]. On the basis of purely mental deductions he made the conclusion that each alveolus receives the blood through an individual very thin arteriole. Such an opinion is widely distributed in modern literature^[6-12]. Figures of this kind are present in modern works, atlases, and textbooks. In recent years the so called intravital microscopic methods of studying the animal inner organs – liver, brain, skeletal muscles at rest have gained wide acceptance^[13,14]. However it appeared to be exceptionally difficult to apply them to the study of lungs. There are two reasons for this: first, it is necessary to have a very large magnification making possible separate alveoli of the lungs to be distinguished; and second, upon the studies of a living animal under physiological conditions the lung repeatedly contracts due to the respiration movements. This resulted in the fact that until recent years almost no works devoted to the study of circulation in the lungs appeared in published literature. At last in 2008 Tabuchi and co.^[15] published the work where they showed that

there are no such arterioles in the lungs, which would supply each alveolus. The alveoli of mice were shown to be supplied with the blood with the help of venous blood flows $\approx 15 \mu\text{m}$ in diameter, which lie between the mass of alveoli. However, the structure of the coatings of these blood flows, the structure of the alveoli, or the mode of the blood contacts with the air medium of the alveoli were not described in this work. The authors had no sufficient magnification, and they could register the picture only during short moments of relative immobility of the lungs.

It is known that at rest 6 liters of blood passes through the human lungs 600 g in mass per minute, and during intensive muscle work up to 18 liters of blood passes through the lungs. With the help of our unique devices and some special methods we were able to overcome all the impediments in the study of lungs under physiological conditions and to see and register in the photographs and video films not only the vascular network of the lungs, but also to scrutinize the structure of separate alveoli.

The first problem to be solved in our work was to reveal the structure of the vascular system of the lungs capable of letting pass such large volumes of the blood through such a small mass of the lungs. The second problem, which almost results from the first, was to find the mechanisms of rapid oxygenation of very large volumes of the blood passing through the lungs per minute – from 6 liters at rest to 18 L during work.

MATERIALS AND METHODS

Our work was carried out on white rats, taking into account the fact that the structure of lungs is similar in all the mammals – from mice to humans. The committee on bioethics of I.P.Pavlov Institute of physiology approved their use in this study. An animal was fixed on a special stand on its side. The animal trachea was first introduced with a soft polyethylene tube about 1.5 mm in diameter in such a manner that a slot of about 0.2-0.15 mm was left between the walls of the tube and the trachea walls. Oxygen was continuously fed through the tracheotomic tube, which filled the lungs. An excess of oxygen was released through the slot between the tracheotomic tube and the trachea wall. Oxygen supply was regulated in such a manner that oxygen entering the lungs did not expand them excessively. Such a method allowed the lungs to be continuously ventilated with oxygen without expansion. The operation of introducing the tracheotomic tube and the very experiment were carried out under light urethane narcosis (120 mg per 100 g of the animal weight). In a number of experiments, when an animal in spite of narcosis showed a certain motive agitation we injected a certain dose of listenone under the skin (1.5 mg per 100 g of the body weight).

For observations and film recording of the vascular system we cut a window about $4 \times 4 \text{ mm}$ in the thoracic cavity on the right side of the animal. The incision of the outer pleura was made through this window. We brought the tube of the contact microscope against the naked lung. The preparation was illuminated through the objective, which allowed the details of circulation system to be recorded at a large magnification without external illumination. The construction of our contact microscope and the operating procedures are described in detail in one of our previous papers^[16]. We were observing either 8-12 alveoli at once or one alveolus with the help of greater magnification. In such a position an animal had the normal or a little decreased blood pressure, and the normal circulation was preserved for several hours. Usually there were no respiration movements, since the lungs were continuously ventilated with oxygen. During this time with the help of a miniature colored TV camera, a monitor, and a colored

printer we made multiple colored panoramic photos of the general picture of circulation in the lungs and of separate alveoli.

In this work we used 35 animals, since far from all the pictures were of sufficiently high quality. The latter depends on the fact that we can record on the paper only “optical” sections of the subject. In contrast to the histological section, the optical section has no even surface. The surface of an alveolus may have a various incline to the plane of the objective of the contact microscope and be located at various distance from the objective. In such a case one end of an alveolus may be focused, whereas the other end may not be focused. Moreover, the scraps of pleura, the blood coagulates, fractions of other alveoli may appear on the surface of an alveolus, and you just cannot avoid this in the optical section.

RESULTS

The results of our experiments are colored pictures of the lung vessels, of alveoli, of the coatings of alveoli, and of the blood in the slots between the coatings of alveoli (Figures 1, 2). First of all let us note large microvessels, which lie between the alveoli. They make up a dense network, which supplies the alveoli with the blood. The diameter of these vessels is from 30 to 50 microns and even more. The distance between separate vessels of the network, which are adjacent to the alveoli is from 40 to 60 microns and more. Such a construction of the lung vessels is a kind of discovery, since during almost a century of the studies of the lung structure nothing like this has been found.

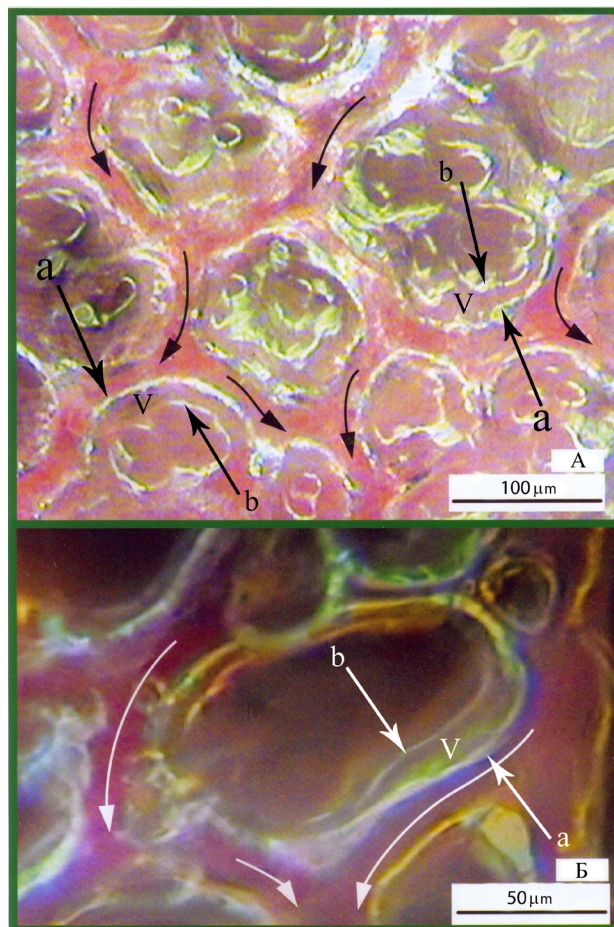


Figure 1 Panoramic photos of circulation in a site of lung (A) and of a separate alveolus (B). The arrows show the direction of the blood flow. “a” the outer coating of an alveolus, “b” – the inner coating of an alveolus; V – the space between the inner and outer coatings of an alveolus.

This construction is given in Figure 1A. After merging the vessels of the network into the lung venulas and veins the arterialized blood from various alveoli reaches the left auricle. In Fig. 1A the coatings of the alveoli can be recognized. The outer coating merges with the coating of a vessel from the network. The inner coating separates the space between the coatings from the air space of an alveolus. In Figure 1B an alveolus is given. Its width is about 50 μm , and a large microvessel adjacent to this alveolus has a diameter of about 30 μm . The vessels near the alveolus are distinctly seen. The coatings of the alveolus also can be distinguished. Close-up views of several alveoli are given in Figures 2A, 2B, 2C, 2D. The inner and outer coatings of these alveoli are distinctly seen. In three of them only separate parts of the coatings are seen. But in one of the photos the coatings are seen over their whole length as closed circles.

Such is the morphological image of the network of the lung vessels, of the location of alveoli and their coatings. All these photos are made in the normal physiological state of the animals with the lungs located inside the animal thorax.

DISCUSSION

We outlined the biological structure of the lungs. What is the physiological significance of this structure?

First it is necessary to answer the question, why the lungs need such large quantities of blood. At rest about six liters of blood pass

through the lungs per minute. This is ten times as much as the volume of the lungs. Every minute each 6 liters of the blood carry away 250 ml of oxygen, which are then spent for the work of all the organs and tissues of an organism. When an organism fulfills an intensive work 18 liters of blood per minute pass through the lungs, i.e. by a factor of 30 greater than the volume of the lungs. In this case every minute the blood carries away about 850-900 ml of O_2 from the lungs. This oxygen is necessary to provide the work of muscles and heart with oxygen. A particular construction of the vessel network of the lungs with a large number of sizable microvessels and with a high blood flow rate in them permits a passage of a great amount of blood through the lungs. This amount of blood at rest and during intensive work is far in excess of the lung volume. Such volumes of blood are consistent with physiological needs of humans and animals. Of course, a question arises, why physiologists studying the circulation in the lungs for about the whole century did not discover this network of large microvessels and did not account for the reason of their great transmissivity. Having no corresponding devices to solve this problem they seem just to step over it, and up to now it remained unanswered.

The blood volume of the lungs is about 0.5 L. Consequently, during saturation of 6 L per minute of venous blood from 40 mm Hg to arterial blood, i.e. to 95 mm Hg, the blood volume of the lungs was alternated 12 times, and each 0.5 L of the venous blood were saturated with oxygen during 5-6 seconds. If 0.5 L of venous blood is stirred with a spoon in a glass in air, the venous blood will be

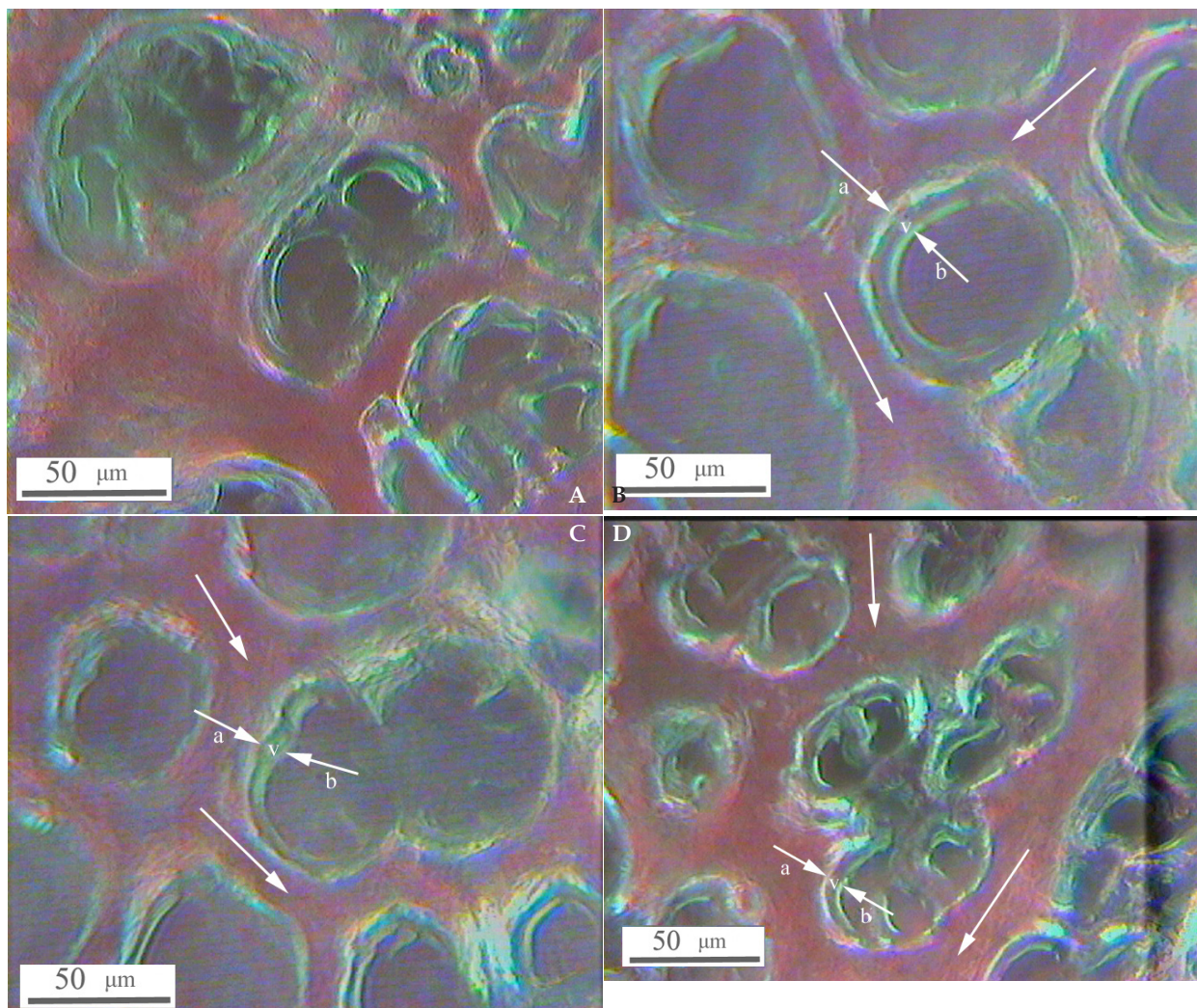


Figure 2 A, B, C, D. Two coatings of the alveoli: a – the inner and b – the outer coatings. V – the blood in the space between the inner and outer coatings of the alveoli.

saturated to arterial blood from 40 to 95 mm Hg in no less than 5-10 minutes. The question arises, which method is used by the lungs for saturating 0.5 L of the blood from venous to arterial during 5-6 seconds. And during intensive work given 18 liters of blood per minute according to our calculations it must happen during 1.6-1.7 seconds. Trying to account for the reason of such an acceleration of the blood oxygenation we must assume that in the lungs the contact of blood with the flow of oxygen in the alveoli is organized in such a manner that the inertness of oxygen diffusion is minimized and the reaction of hemoglobin with oxygen reaches the highest efficiency. Our latest studies confirmed these assumptions. First we found that oxygen from the air space of alveoli never contacts the blood flowing in the large microvessels about 20-50 μm in diameter and even greater. It is practically impossible to attain a high efficiency of saturation given a relatively thick layer of blood in a large microvessel and a high blood flow rate. A thorough investigation of the circulation system in the lungs showed that between large microvessels and the air space of the alveoli there is one more space as a slot between outer and inner coatings of the alveoli. This slot is from 2 to 6 μm thick. The blood penetrates into this narrow space from the vessels through special channels, which thread the coating of the vessel and correspondingly the outer coating of an alveolus. In the photos made by Weibel^[12] these channels are well seen. The blood that penetrated into the space between the coatings is distributed (spread) over the inner coating of an alveolus. This abruptly increases the area of the blood contact with the oxygen flow, thus undoubtedly accelerating oxygen diffusion. This is the first factor. The layer of blood spread over the inner coating of an alveolus is very thin, possibly only 2 - 4 μm thick. It is common knowledge that the thinner is the layer of a substance into which oxygen diffuses, the more rapidly the diffusion occurs. This is the second factor. We distinctly observe in our video films attached to the paper that the thinnest layer of blood spread over the inner coating of an alveolus continuously rotates. These data we obtained by an unusual method – by recording the video films of the movement of a thin layer of blood in an alveolus in the animal life time. This is the third factor, which was the most difficult to discover.

It remains unknown if there are any other factors accelerating the diffusion of oxygen in an alveolus. However the factors we gave seem to be able to account for an unusually rapid oxygenation of large volumes of blood every minute passing through the lungs from the state of rest and to an intensive muscle work.

CONCLUSIONS

Lungs and heart are the main engine of life at rest, during work, upon adaptation to various unfavorable environmental conditions, during relatively short-term resistance of an organism to strong pathological effects. This is well known. However, the most important mechanisms of the action of this life engine appeared to remain a mystery until recently. We were able to account for the manner how through a relatively small mass of lungs very large volume of blood can pass

per minute. It appeared to be sufficiently simple to be done with the help of our devices. Much more difficult it was to reveal the mechanisms of the blood oxygenation in the lungs even with our technique. But with the help of video films we managed to find three factors which allow a rapid saturation of the blood in the alveoli with oxygen. These most complicated physiological procedures are the result of many millions of years of biological evolution.

REFERENCES

1. Michel RP. Arteries and veins of the normal dog lung: qualitative and quantitative structural differences. *Am J Anat* 1982; **164**: 227-241. [DOI: 10.1002/aja.1001640304]; [PMID: 7424654]
2. Moudgil R, Michelakis ED, Archer SL. Hypoxic pulmonary vasoconstriction. *J Appl Physiol* 2005; **98**: 390-403. doi:10.1152/jappphysiol.00733.2004. [PMID: 15591309]
3. Paddenberg R, Konig P, Faulhammer P, Goldenberg A, Pfeil U, Kummer W. Hypoxic vasoconstriction of partial muscular intracinar pulmonary arteries in murine precision cut lung slices. *Respir Res* 2006; **7**: 93. [DOI: 10/1186/1465-9921-7-93]
4. Waypa GB, Schumacker PT. Hypoxic pulmonary vasoconstriction: redox events in oxygen sensing. *J Appl Physiol* 2005; **98**: 404-414. [DOI: 10.1152/jappphysiol.00722.2004]; [PMID: 15591310]
5. Miller WS. The lung. Springfield-Baltimore, Thomas. 1947.
6. Dvoretzkii DP, Tkachenko BI. Hemodynamic in the lungs [In Russian]. Leningrad, Meditsina, 1956.
7. Sinelnikov RD. Atlas of human anatomy. Vol. II [In Russian]. Moscow, Meditsina, 1979.
8. Faller AF, Schunke M. The human body. Stuttgart, George Thime Verlag KG, 2004.
9. Dirken MN, Heemstra H. Agents of the lung circulation. *Quart. J. exp. Physiol.* 1948; **34**: 227-241.
10. Guyton AC. Textbook of Medical Physiology. Cambridge, Cambridge University Press, 1986.
11. Scheid P. Physiology of respiration. Fundamental and Clinical Physiology. Section 10. Academia, Moscow, 2004.
12. Weibel ER. The pathway for oxygen. Cambridge, London, Harvard University press, 1954.
13. Mempel TR, Moser C, Hutter J, Kuebler WM, Krombach F. Visualization of leukocyte transendothelial and interstitial migration using reflected light oblique transillumination in intravital video microscopy. *J Vasc Res* 2003; **40**: 435-441. [DOI: 10/1159/000073902]
14. Nagasaka Y, Bhattacharya J, Nanjo S, Gropper MA, Staub NC. Microstructure measurement of lung microvascular profile during hypoxia in rats. *Circ Res* 1984; **54**: 90-95.
15. Tabuchi A, Mertens M, Kuppe H, Pries AR, Kuebler WM. Intravital microscopy of the murine pulmonary microcirculation. *J Appl Physiol* 2008; **104**: 338-346. [DOI: 10.1152/jappphysiol.00348.2007]
16. Ivanov KP, Kalinina MK, Levkovich YuI. Microcirculation velocity changes under hypoxia in brain, muscles, liver and their physiological significance. *Microvasc Res* 1985; **30**: 10-18.

Peer Reviewer: Michael Firstenberg