

When A Lung Nodule is not the Usual Lung Nodule: the Rare Entity of PEComa

Flavio Colaut, Nicola Clemente, Maurizio De Luca

Flavio Colaut, Nicola Clemente, Maurizio De Luca, General Surgery and Thoracic, City Hospital, Montebelluna (Treviso), Italy

Conflict-of-interest statement: The author(s) declare(s) that there is no conflict of interest regarding the publication of this paper.

Open-Access: This article is an open-access article which was selected by an in-house editor and fully peer-reviewed by external reviewers. It is distributed in accordance with the Creative Commons Attribution Non Commercial (CC BY-NC 4.0) license, which permits others to distribute, remix, adapt, build upon this work non-commercially, and license their derivative works on different terms, provided the original work is properly cited and the use is non-commercial. See: <http://creativecommons.org/licenses/by-nc/4.0/>

Correspondence to: Flavio Colaut, General Surgery and Thoracic, City Hospital, via Montegrappa 1, 31044 Montebelluna (Treviso), Italy.

Email: flavio.colaut@outlook.it

Telephone: +390423611520

Received: December 12, 2017

Revised: December 23, 2017

Accepted: December 27, 2017

Published online: April 27, 2018

ABSTRACT

Perivascular epithelioid cell tumors (PEComas) are rare tumors which can arise in almost every body site. Little is still known about these tumors because of the limited number of cases described by far and the short follow-ups. Diagnosis, based on histopathological and immunohistochemical features, is not so straightforward owing to their rarity. Prediction of clinical behaviour which can be benign, locally aggressive or purely malignant, is not without flaws. A refinement in the prognostic criteria is desirable. Even if surgery is considered the mainstay of therapy of both primary PEComa and local recurrences/metastases, doubts still exist regarding the other treatment modalities such as chemotherapy and immunotherapy. The rarity of this neoplasm prompted us to report a case we observed. A left lung PEComa was diagnosed in a 70-year-old lady that we treated with upper left lobectomy. Our aim is to add our experience to

the present body of literature and contribute in the understanding of PEComa neoplasms.

Key words: Lung nodule; Lobectomy; PEComa

© 2018 The Author(s). Published by ACT Publishing Group Ltd. All rights reserved.

Colaut F, Clemente N, De Luca M. When A Lung Nodule is not the Usual Lung Nodule: the Rare Entity of PEComa. *Journal of Respiratory Research* 2018; **4(1)**: 131-133 Available from: URL: <http://www.ghrnet.org/index.php/jrr/article/view/2224>

INTRODUCTION

Perivascular epithelioid cell tumors (PEComas), which had originally been described by Liebow and Castleman^[1] are rare neoplasms. Indeed less than 100 cases have been published so far^[2]. They can arise in almost every body site (gastrointestinal, gynecologic and genitourinary tracts; retroperitoneum, skin, heart, breast, oral cavity, orbit and skull base) with a prevalence in women and a wide age range at presentation. Diagnosis, which is based on histopathological and immunohistochemical features is difficult owing to their rarity. The lack of detailed literature on these tumor explains uncertainty in the prediction of the clinical behaviour. Moreover, concerns still exist regarding the optimal treatment. We report a case of a PEComa of the upper left lobe of the lung in a 70-year-old female patient. We believe that our experience can sum up to the body of literature available to date and aid in a better understanding of this entity.

CASE REPORT

A 70-year-old lady was occasionally diagnosed, by plain chest X-ray, with a solitary nodule in the middle area of left lung field (Figure 1).

She was on pharmacological treatment for systemic hypertension, bronchial asthma, COPD, hiatal hernia and gastritis. Her past medical history included hysterectomy for uterine fibromatosis and a total thyroidectomy with lymphadenectomy for cancer. A contrast-enhanced CT of the chest showed that the lesion, of about 32 mm of diameter, was located within the lingula, just above the fissure. Moreover it had several calcifications and it didn't uptake any iodinated contrast medium (Figure 2).

The diagnostic work-up was completed with a 18F-fluoro-2-deoxy-D-glucose positron emission tomography (18F-FDG-PET) which showed a mild (SUVmax =5.6) FDG activity within the lesion with no significant uptake elsewhere in the body (Figure 3).

Shortly after, a CT guided needle biopsy was performed. The histopathological analysis of the retrieved specimen showed absence of unequivocal features of malignancy. The case was discussed in another hospital and they decided not to treat the lesion and the patient was counselled for clinical and radiological follow-up. But one year later a HRCT of the chest was performed. An increase in the dimension of the lesion was detected (maximum diameter of 38 mm). Consequently, a surgical treatment was planned. A left posterolateral thoracotomy was performed along the fifth intercostal space. The lesion, of hard consistency, was easily identified within the lingula and a specimen was taken. Frozen section of the specimen cast high suspicion for malignancy as cytologic atypias, mitoses, and necrosis were detected by the pathologist. Abiding by the informed consent, we went on to perform an upper left lobectomy. This was carried out according to the usual technique in use in our Institution. The inferior pulmonary ligament was sectioned as a first step. Then the superior pulmonary vein was isolated at the hilum and sectioned by Endo-GIA. The left pulmonary artery was dissected at the hilum and within the fissure. As this last one was incomplete, a blunt dissector was introduced along the artery in the fissure until it exited at the hilum just at the level of the previous dissection. On the guidance of the dissector, an Endo-Gia was introduced and the fissure was completely divided. Then it was possible to ligate and divide the segmental arterial branches A3, A1+2 and finally A4+5. The bronchus for the upper lobe was divided by Endo-GIA as well and the mechanical suture was reinforced with some absorbable stitches. Lymphadenectomy at level 5, 6, 10 and 11L was carried out. Two drains were placed and the thoracotomy was closed. The postoperative course was uneventful so, after removal of the drains, the patient was discharged in ninth postoperative day in good health condition.

The pathology report described a well circumscribed tumor with well defined margins, measuring 3.7 × 3 × 3.3 cm on gross examination. At a microscopic level the tumor was composed of cells mostly epithelioid and, in lesser degree, of spindle shape arranged in short bundles. Cytoplasm was eosinophilic, nuclei of variable dimensions with prominent eosinophilic nucleoli inside. The cellular component was interspersed with thin walled blood vessels. Immunohistochemistry showed that the tumor cells were positive for HMB-45, MART1 and smooth muscle actin. However they were negative for cytokeratin (AE1/AE3), epithelial membrane antigen (EMA), S-100 and ALK. All the lymph nodes retrieved were free of metastases. The overall features favored a diagnosis of PEComa of the lung of uncertain malignant potential. In consideration of the characteristics of the patient (age, performance status), the characteristics of the neoplasm (uncertain malignant potential) and the lack of consensus on optimal treatment for PEComas, no adjuvant treatment was administered. The patient was strongly recommended to adhere to a strict clinical and radiological follow-up. To date, after a one year follow-up, the patient is still asymptomatic and disease-free.

DISCUSSION

According to the World Health Organization perivascular epithelioid cell tumors (PEComas) are mesenchymal tumors composed of histologically and immunohistochemically distinctive perivascular

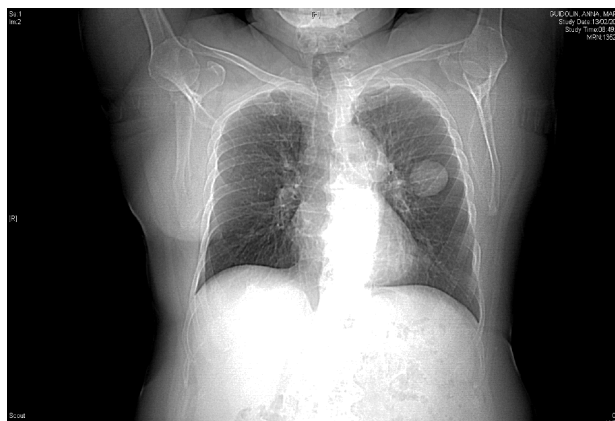

Figure 1 CT scout image showing a solitary nodule in the middle area of the left lung field.

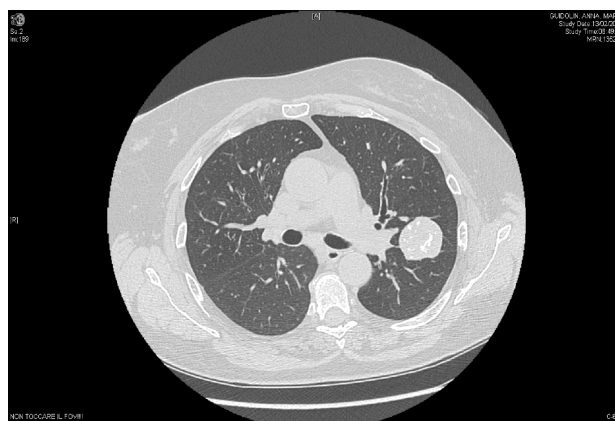


Figure 2 Contrast enhanced CT scan showing a lesion of about 32 mm of diameter, within the lingula. The lesion presents several calcification in its context.

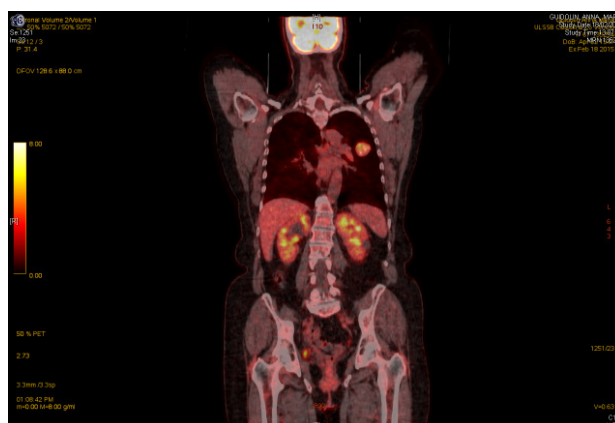


Figure 3 18F-FDG-PET showing a mild (SUVmax =5.6) FDG activity within the lesion.

epithelioid cells (PECs)^[3]. To date there is no known normal cellular counterpart to this PEC, and a precursor of PEComas has not been described yet^[4]. Grossly PEComas are usually tan to grey with mixed firm and friable areas. Cut surface is dishomogeneous as well, with white-tan to grey-red areas corresponding to focal areas of necrosis and hemorrhage. Although such neoplasms appear to be well circumscribed, no definite capsule is detectable. From a microscopic point of view, PEComas are typically biphasic tumors with epithelioid and spindle cell components; a great variation exists in the relative proportion of these two different cellular population. These cells have clear to granular, lightly eosinophilic cytoplasm with small,

centrally placed normochromatic nuclei and are arranged in bundles radially located around the numerous small blood vessels. The most distinctive feature is the immunohistochemical one. The PEComa is characterized by immunopositivity with both myoid (desmin, smooth muscle actin) and melanocytic (HMB-45, MART-1) markers.

The case we observed had exactly the above mentioned macroscopic, microscopic and immunohistochemical characteristics; indeed it appeared as a well circumscribed mass at gross examination with a mixture of epithelioid and spindled cell with eosinophilic cytoplasm arranged in short bundles. Moreover the tumor cells were positive for HMB-45, MART1 and smooth muscle actin.

The scientific community is still uncertain about how to differentiate the clinical behaviour of these tumors. To date, only 100 PEComas have been reported in the English language medical literature. Malignant PEComas represent a small percentage of these. Add to this the relatively short length of follow-up, no wonder firm criteria for malignancy have yet to be established. A recent clinicopathologic study^[4] of 26 PEComas suggested three main criteria of size (greater than 8.0 cm), mitotic count (of more than 1 per 50 high-power fields) and necrosis (presence). Based on the presence of none, 1 or 2 or more of these criteria, PEComas could be divided into benign, uncertain malignant potential and malignant categories. Infiltrative growth or edges, marked hypercellularity and marked nuclear pleomorphism/atypia may be secondary features suggesting aggressive behaviour or malignancy^[5,6]. Ki-67 labeling index which is generally is a good marker of mitotic activity and of aggressive behaviour doesn't perform equally well in PEComas. Indeed PEComas with Ki-67 labeling index of less than 1% have neither recurred nor metastasized^[7]. However Ki-67 labeling of 5% of neoplastic cells has been observed in uterine PEComas that behaved aggressively^[8].

Despite the adoption of these criteria, recognition of clinical behaviour is far from being flawless. There are several reports about diagnosis of malignant PEComa being made only after the patient had returned with a metastasis^[9]. This highlights both the need for criteria that more accurately predict the behaviour of PEComas and the need for long term follow-up as widespread metastases may present in the late course of the disease.

The case of PEComa we operated on in our Institution, based on the histo-pathological features, was categorized into the "uncertain malignant potential" group. This seems to be consistent with the clinical course as, after one year follow-up, the patient is still disease-free. Nevertheless, given the uncertainty in prognostication, we adopted a strict follow-up schedule based on clinical and radiological examinations at 6 months intervals.

Optimal management of PEComas is not well established at the present time. Currently, surgery is the mainstay of treatment of primary PEComa at presentation as well as of local recurrences and metastases with the aim of obtaining clear resection margins. The role of adjuvant therapy remains unclear. Even if metastases have been successfully treated by resection alone^[8], adjuvant therapies, including chemotherapy and immunotherapy may be of value for patients with locally advanced or metastatic PEComa. Dacarbazine, vincristine and imatinib mesylate have been used with variable results (partial, complete and absent response)^[10-11]. Our patient was excluded from adjuvant treatment for several reasons (poor performance status, age, estimated clinical behaviour of the neoplasm). As a consequence, no clinical recommendation regarding this issue can be made based on

our case.

CONCLUSION

PEComas are a rare neoplastic entities which can affect the lung as in the case we observed. Diagnosis is based on histopathological and immunohistochemical features and it can be difficult because of their rarity. Uncertainty still exists regarding prognostic indexes and optimal management even if surgery seems to be the mainstay of treatment. The case reported here can be a valuable adjunct for a better understanding of these neoplasms.

REFERENCES

1. Liebow AA, Castleman B. Benign clear cell (sugar) tumors of the lung. *Yale J Biol Med* 1971; **43**: 213-22 [PMID: 5578741]; [PMCID: PMC2592968]
2. Policarpio-Nicolas ML, Covell J, Bregman S, Atkins K. Fine needle aspiration cytology of clear cell "sugar" tumor (PEComa) of the lung: report of a case. *Diagn Cytopathol* 2008; **36**: 89-93. [PMID: 18181192]; [DOI: 10.1002/dc.20647]
3. Folpe AL. Neoplasm with perivascular epithelioid cell differentiation (PEComas). In Fletcher CDM, Unni KK, Mertens F, eds. Lyon, France: IARC Press; 2002: 221-222 World Health Organization Classification of Tumors: Pathology and Genetics of Tumors of soft tissue and bone.
4. Folpe AL, Mentzel T, Lehr HA, Fisher C, Balzer BL, Weiss SW. Perivascular epithelioid cell neoplasms of soft tissue and gynecologic origin: a clinicopathologic study of 26 cases and review of the literature. *Am J Surg Pathol* 2005; **29**: 1558-1575 [PMID: 16327428]
5. Fadare O, Parkash V, Yilmaz Y, et al. Perivascular epithelioid cell tumor (PEComa) of the uterine cervix associated with intraabdominal "PEComatosis": a clinicopathological study with comparative genomic hybridization analysis. *World J Surg Oncol* 2004; **2**: 35 [PMID: 15494070]; [PMCID: PMC527874]; [DOI: 10.1186/1477-7819-2-35]
6. Hornick JL, Fletcher CD. PEComa: what do we know so far? *Histopathology* 2006; **48**: 75-82 [PMID: 16359539]; [DOI: 10.1111/j.1365-2559.2005.02316.x]
7. Tanaka Y, Ijiri R, Kato K et al. HMB-45/Melan-A and smooth muscle actin-positive clear-cell epithelioid tumor arising in the ligamentum teres hepatis: additional example of clear cell "sugar" tumors. *Am J Surg Pathol* 2000; **24**: 1295-1299 [PMID: 10976706]
8. Dimmler A, Seitz G, Hohenberger W, Kirchner T, Faller G. Late pulmonary metastasis in uterine PEComa. *J Clin Pathol* 2003; **56**: 627-628 [PMID: 12890819]; [PMCID: PMC1770029]
9. Henry B Armah, Anil V Parwani. Perivascular Epithelioid Cell Tumor. *Arch Pathol Lab Med* 2009; **133**: 648-654 [PMID: 19391667]; [DOI: 10.1043/1543-2165-133.4.648]
10. Parfitt JR, Bella AJ, Wehrli BM. Primary PEComa of the bladder treated with primary excision and adjuvant interferon- α immunotherapy: a case report *BMC Urol* 2006; **6**: 20 [PMID: 16925812]; [PMCID: PMC1564030]; [DOI: 10.1186/1471-2490-6-20]
11. Rigby H, Yu W, Schmidt MH, Fernandez CV. Lack of response of a metastatic renal perivascular epithelial cell tumor (PEComa) to successive courses of DTIC based therapy and imatinib mesylate. *Pediatr Blood Cncr* 2005; **45**: 202-206 [PMID: 15704192]; [DOI: 10.1002/pbc.20305]

Peer Reviewer: Banu Salepci